

Clinical Image

Traumatic Eye Avulsion and Optic Nerve Transection

Brizido M*, Lopes B, Almeida AC and Soares IP
Department of Ophthalmology, Hospital Beatriz Ângelo,
Portugal

***Corresponding author:** Margarida Brizido,
Department of Ophthalmology, Hospital Beatriz Ângelo,
Av Jaime Cortesao, n.34/7 Dir, 1495-138 Miraflores,
Portugal

Received: December 09, 2020; **Accepted:** December
18, 2020; **Published:** December 25, 2020

Clinical Image

A 59-year-old man with no past medical history presented to the ophthalmology emergency department after a blunt trauma to his right eye, following a syncopal event. He reported absent vision from the injured eye and local pain.

Examination revealed unruptured partial avulsion of the right globe, which remained attached to the orbit by the superior rectus. Integrity of the remaining extraocular muscles was uncertain. Complete optic nerve transection was recognized, with inferior exposure of the nerve (Figure 1). The eye preserved limited upward motion.

Computed tomography imaging showed protrusion of the globe and confirmed absence of optic nerve inside the orbital compartment (Figure 2).

Enucleation of the avulsed globe was performed, followed by primary reconstruction of the anophthalmic socket with a dermis fat graft. An ocular prosthesis was later fitted for rehabilitation purpose.

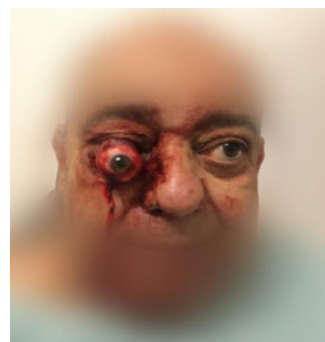

Figure 1:

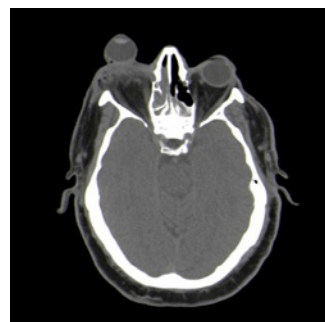


Figure 2: