

## Case Report

# Eosinophilic Myocarditis: About Two Cases and Review of Littérature

Rachdi I\*, Aydi Z, Arbaoui I, Zoubeidi H, Somai M, Dhaou BB, Daoud F and Boussema F

Department of Internal Medicine, Habib Thameur Hospital, Faculty of Medicine of Tunis, University of Tunis el Manar, Tunisia

\***Corresponding author:** Imène Rachdi, Department of Internal Medicine, Habib Thameur Hospital, Faculty of Medicine of Tunis, University of Tunis el Manar, Tunis, Tunisia

**Received:** June 09, 2020; **Accepted:** July 03, 2020;

**Published:** July 10, 2020

## Abstract

Eosinophilic myocarditis (EM) is an acute life threatening inflammatory disease of the heart. Neither large case series nor clinical trials on this specific myocarditis have been reported.

It generally presents with a wide array of clinical manifestations. Clinical presentation tends to differ in cases and not all the patients show the same signs and symptoms

Echocardiography, cardiac magnetic resonance, and bio markers particularly serum eosinophilic cationic protein concentrations are known to aid in diagnosis. EM may lead to progressive, irreversible, and fatal myocardial damage if prompt diagnosis is not made and therapy is not initiated, The current treatment regimens include corticosteroids, and immunosuppressive therapy.

We report two cases of eosinophilic myocarditis by illustrating the inaugural clinical manifestations, the diagnostic approach and our therapeutic attitude.

**Keywords:** Eosinophilic Myocarditis; Hypereosinophilia; Cardiac Magnetic Resonance; Corticosteroids

## Introduction

Hypereosinophilia is a frequent situation in internal medicine. However, cardiac involvement due to a major hypereosinophilia is poorly documented in the littérature and represents a real diagnosis and therapeutic challenge given the many clinical and ultrasound presentations that it can take as well as the fatality of its evolution in the absence of adequate therapy.

## Case Report 1

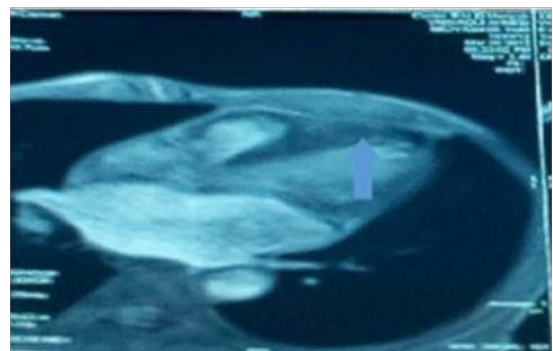A 43 year old followed for severe persistent asthma since the age of 16 with frequent exacerbations (one to two episode per month) and history of hospitalization in intensive care unit for acute asthma attack for 3 years and treated with inhaled corticosteroids and beta 2 mimetics, presented in cardiology for constrictive chest pain irradiating into inter-scapular and to the left upper limb partially improving by the forward position.

The physical examination noted tachycardia at 110, polypnea at 25c/min and a blood pressure at 120/70 mmHg.

He had an hepto jugular reflux and jugular turgescence as well as diffuse sibilants on pulmonary auscultation. The electrocardiogram noted significant antero-septal-apical undershift associated with a diffuse microvoltage, the troponin assay was positive at 1,2 U/l , controlled at Hour 6, 1.69U/l, and 3.89 U/l at Hour 12. Biological assessment noted a biological inflammatory syndrome, normocytic anemia, major hypereosinophilia at 5210 elements/mm<sup>3</sup>. Renal and hepatic functions were preserved. Proteunuria was negativer. Anti-ischemic therapy was initiated for ST-, troponines + coronary syndrome. A transthoracic ultrasound showed a pericardial detachment of 7 mm inferior- lateral and 9 mm right retro-auricular. The left ventricle had a discrete centric hypertrophy with a

fraction of ejection at 70%.Coronary angiography revealed infiltrate coronary arteries without significant lesions. The diagnosis of acute myocarditis was suspected. Myocardial MRI showed nodular antero-septal myocardial contrast and under the pericardium at the tip of the left ventricle (Figure 1).

An etiologic assessment of this eosinophilic myopericarditis was initiated. Thoracic CT scan showed a diffuse thickening of the bronchial fibroscopy walls and a multifocal subpleural frosted worm appearance. Functional respiratory explorations showed a minor obstructive profile. Bronchial fibroscopy showed an inflamebronchial mucosa. Bronchoalveolar lavage fluid cytology showed moderate eosinophilic polynucleosis with a Gold score of 850.Histological study of bronchial biopsy concluded to the presence of tissue eosinophilia. Nasal biopsy showed an aspect of chronic rhinitis without eosinophilic infiltration. Myelogram showed eosinophilic infiltration at 50%. Electromyogram was without abnormalities. Brain MRI

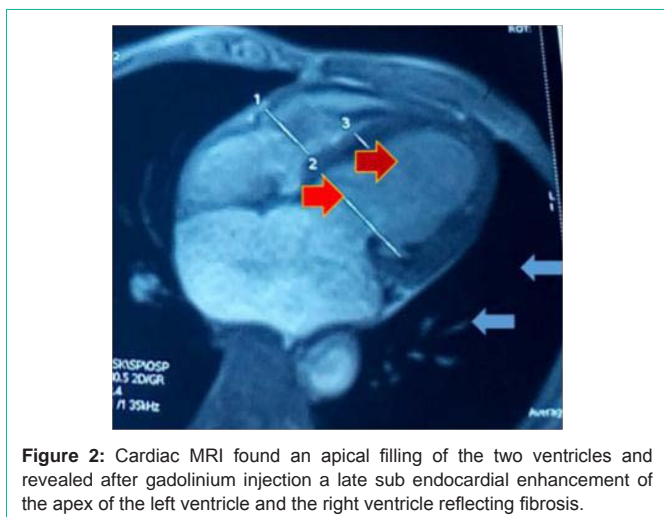


**Figure 1:** Cardiac MRI showing a nodular myocardial contrast taken antero-septally and linearly under the pericardium at the tip of the left ventricle.

imaging showed a discret meningeal contrast. The anti neutrophil cytoplasmic antibodies were negative. In front of the association of severe persistent asthma, rhinitis, hypereosinophilic perimyocarditis, eosinophilic infiltration of blood and tissues, we retained the diagnosis of eosinophilic granulomatosis with polyangitis. FFS score was at 1 point. BVAS score was at 16 points. A treatment with corticosteroids was initiated including 3 boli of methylprednisolone at the dose of 1gramme/day relayed by oral corticosteroids at the dose of 1mg/kg with progressive degression. Cyclophosphamid was prescribed every 15 days at the dose of 0,6 gramme/m<sup>2</sup> of body surface. The clinical outcome was marked by a regression of asthma symtomatology and the hypereosinophilia as well as the absence of thoracic pain episodes.

## Case Report 2

A 60 year old patient with no significant medical history or cardiovascular risk factors who presented to the emergency department with acute dyspnea with orthopnea. The examination found a general altered state, hypotension at 60/40 mmHg, polypnea at 60 cycles /min, associated with the presence of diffuse bilateral crackling at cardiac auscultation. The electrocardiogram showed an atrial fibrillation pattern at 170 beats per minute. The patient was not febrile and did not have hepatosplenomegaly or superficial adenopathies. The biological evaluation revealed the presence of major hypereosinophilia at 5200 elements/mm<sup>3</sup>. The patient was transferred for a resuscitation where dobutamine, digitalics and non invasive ventilation sessions with rapid improvement. Transthoracic ultrasound detected concentric hypertrophy of the ventricular walls associated with an estimated left ventricular ejection fraction of 48% and a moderate mitral insuffiency. The cardiac MRI found an apical filling of the two ventricles and revealed after gadolinium injection a late sub endocardial enhancement of the apex of the left ventricle and the right ventricle reflecting fibrosis (Figure 2). The patient was subsequently referred to internal medicine for etiologic assessment of hypereosinophilia. The stool parasite examination and serology were negative. The anticytoplasmic antibodies and antinuclear assays were negative. Myelogram and osteomedullary biopsies ruled out the diagnosis of malignant hemopathy. Thoraco-abdominopelvic CT imaging showed a low abundance of pleural effusion of both pulmonary fields with hepatosplenomegaly. Hisological examination



**Figure 2:** Cardiac MRI found an apical filling of the two ventricles and revealed after gadolinium injection a late sub endocardial enhancement of the apex of the left ventricle and the right ventricle reflecting fibrosis.

of bronchial biopsies revealed the existence of significant eosinophilic infiltration. Esogastroduodenal fibroscopy was without abnormalities. Colonoscopy with biopsies soncludedto the presence of eosinophilic colitis. Infront of this major hypereosinophilia with mulsystematic infiltrations (Colon, lungs and myocarde), we retained the diagnosis of an essential hyperesinophilic lymphoid. This is attested by the negativity of the search of the FIP1L1PDGFRA mutation. The patient was treated with oral corticosteroids at the dose of 1mg/kg/day associated to interferon alpha. with initial clinical improvement and regression of hypereosinophilia. Fourteen months after, he presented a cardiorespiratory decompensation leading to the patient death.

## Discussion

Eosinophilic Myocarditis (EM) is a rare form of myocardial inflammation, characterized by eosinophilic infiltration, and often accompanied by eosinophilia, [1-3]. The degree of eosinophilic infiltration of the myocardium is thought to depend on the underlying condition as well as the degree and duration of eosinophilic exposure. EM has been reported in association with hypersensitivity reactions [4,5]; immune-mediated disorders, such as Eosinophilic Granulomatosis with Polyangiitis (EGPA) (formerly Churg-Strauss syndrome) [6-8]; undefined complex hypereosinophilic syndrome (HES) or its myeloproliferative variant [9-11]; infections [12]; and cancer [13],

Cardiac involvement in cases of peripheral eosinophilia is very common (50%-60%). Eosinophils remain viable in the cardiac tissue for weeks and eventually degranulate releasing toxic substances such as eosinophil-derived neurotoxin, cationic protein, major basic protein, and reactive oxygen species. All these toxins may damage the endothelial cells and myocytes causing necrosis and thrombosis which end up in endomyocardial fibrosis. Inflammatory changes within the endocardium and papillary muscle derangement may affect the heart valves which manifests as regurgitation [14].

Numerous studies have stated about eosinophilic granule proteins leading to progression of endomyocardial lesions. This is due to the fact that eosinophilic granules contain a variety of substances including a collagenase that cleaves type 1 and type 3 collagen, major basic protein, eosinophilic cationic protein, acid phosphatase, aryl sulfatase, ribonuclease, peroxidase, B-glucuronidase, and alkaline phosphatases [15-16]. This can lead to myocyte necrosis, and can result in increased permeability and inhibition of mitochondrial respiration [17].

Eosinophilic myocarditis can present as an acute or chronic condition. Acute necrotizing myocarditis is the initial presentation of disease; it is rare and often fatal, followed by endocardial thrombosis, and chronic endomyocardial fibrosis [18]. Chronic myocarditis ranges mostly from one to 11 years from diagnosis till death. These people of ten develop symptoms of congestive heart failure [19].

EM possesses three stages. In stage 1, there is acute necrotic stage due to the infiltration and extra cellular deposition of eosinophil, and consequently interleukin 5 mediated injury. This stage lasts for about two to three weeks. Stage 2 is the thrombotic stage, characterized by layered thrombus along damaged endocardium due to an activation of tissue factor by eosinophils. Cerebral thromboembolic are common during this thrombotic stage. Stage 3 is considered as the fibrotic stage

which is characterized by myocardial fibrosis [20].

The hypereosinophilic Syndromes (HES) are characterized by persistent marked eosinophilia ( $>1500$  eosinophils/mm<sup>3</sup>), the absence of a primary cause of eosinophilia (such as parasitic or allergic disease), and evidence of eosinophil-mediated end organ damage [21]. Cardiovascular complications of HES are a major source of morbidity and mortality in these disorders. Whereas earlier studies reported that up to 84% of HES patients have signs and symptoms of cardiac disease, more recent reports suggest that the frequency is closer to 40-50% [21-22].

Clinical evidence of cardiac involvement in HES includes signs and symptoms of heart failure, intracardiac thrombus, myocardial ischemia, arrhythmias, and rarely pericarditis [22,23]. In an early review of 65 cases of HES in the English literature, the most common presenting symptom was dyspnea, occurring in 60% of the patients. Seventy-five percent of the 55 patients who could be evaluated had signs and symptoms of congestive heart failure and 4% had evidence of pericarditis [3]. In the same review of 26 HES patients followed prospectively at the NIH, 42% had dyspnea, 27% had chest pain, 12% had cough, 8% had palpitations, and 4% had embolic events [22]. These patients were subsequently found to have mitral regurgitation (42%), congestive heart failure (38%), aortic regurgitation (4%), and aortic stenosis (4%).

Electrocardiography can be performed after taking a thorough history which may show sinus rhythm, ST segment, and T wave abnormalities. Those who come with signs of infarction may show ST segment elevation, ST segment depression, and Q waves. Presence of Q waves or left bundle branch block is associated with a higher mortality rate [24]. On echocardiography, features of myocarditis include dilated, restrictive, hypertrophic, and ischemic cardiomyopathy. Increased sphericity and left ventricular volume occurs in acute active myocarditis. This procedure is also used to detect the right ventricular involvement, pericardial effusion, and left ventricular thrombus. Right ventricle involvement is a very strong indication of cardiac transplantation [25].

In recent years, CMR imaging has emerged as a highly useful non-invasive modality for the diagnosis of cardiac involvement in HES. CMR imaging is more sensitive to and specific for the detection of ventricular thrombi than either transthoracic or transesophageal echocardiography [26]. Delayed enhancement gadolinium imaging is capable of detecting myocardial fibrosis and inflammation. CMR imaging uses inversion-recovery prepared T1-weighted gradient-echo sequencing after the intravenous administration of gadolinium chelate to demonstrate nonviable tissue as delayed enhancement [27]. Delayed enhancement resulting from fibrosis is more intense than delayed enhancement due to inflammation [27]. There are several recent case reports describing CMR imaging as an adjunct diagnostic modality in HES [27,28]. One report describes the use of cine-MRI to aid in right ventricular endomyocardectomy in an HES patient [29].

Cardiac manifestations of are diverse and potentially severe when it comes to myocarditis quickly evolutionary or tamponade. In two large clinical cohorts comprising respectively 112 and 95 patients with Eosinophilic Granulomatous Polyangiitis (GPEA), cardiac involvement was noted in 35 to 51% of cases [30,31]. The clinical signs of cardiac involvement are dominated by severe heart failure,

determined by its rapid onset [30,31]. The other clinical manifestations are represented by: pericarditis (9-38% of), tachycardia isolated (12-20% of cases), rhythm disturbances (6-12% cases) or cardiac conduction (3% of cases), valve disease of varying severity (50% of cases), hypertension arterial (39% of cases) or sudden death (3% of case) [30,32,33].

Certain biological tests would be factors predictive of heart damage in patients with SCS. On the one hand, the negativity of ANCA noted in patients having a complicated SCS of cardiac involvement, as was the case of our observation, is an argument in favor of the presence of this type of visceral involvement

On the other hand, hyperosinophilia is correlated with the presence of the cardiac locations of this vasculitis. In fact, in the study of 49 cases of GPEA by Neumann et al., A higher serum NEP rate was objectified in the group of patients with a cardiac location (9947/mm<sup>3</sup> vs 3657 / mm<sup>3</sup>,  $p < 0.001$ ) [34] Cardiac MRI is a useful test for detecting heart damage during GPEA.

Cardiac MRI could influence the treatment regimen, since myocardial damage justifies the use of immunosuppressant's [35]. Finally, this examination could allow the progressive monitoring of cardiac involvement in these patients [36] Cardiac MRI in patients having an SCS is the existence of a late enhancement, which occurs ten minutes after gadolinium injection; this enhancement late is linked to inflammation and myocardial fibrosis and is observed preferentially in the middle and apical, and at the ventricular side wall [35,36].

The images found at MRI in the reported case were contributed to the differential diagnosis with acute coronary syndrome in fact The localization of this late enhancement is not systematized in a coronary perfusion zone [37,38].

The Five-Factor Score (FFS) is a validated tool which allows assess the severity of necrotizing systemic vasculitides. 2011, a modified version of the FFS was published including four factors of bad prognosis which are: the age higher than 65 years, heart and gastrointestinal involvement and kidney failure with a serum creatinine greater than or equal to 150mol/L but also an element of good prognosis which is the otolaryngological attack [39]. Indeed, the authors estimated mortality at five years at 9, 21 and 40%, respectively, in the patient groups with an FFS score of 0.1 and greater than or equal to 2 [39]. Of those reported by Guillevin et al., eight of 13 patients with myocardial died during the acute phase despite corticosteroid therapy [40]. These data underscore the importance of early diagnosis and therapeutic management in these patients.

Specific treatment of EM differs significantly based on its underlying aetiology. The majority of individuals with EM are treated with immunosuppressive treatment, namely, corticosteroids the initial dosage of corticosteroids and the treatment duration vary among the published studies and thus no clear evidence-based recommendations can be given at this time. It seems reasonable to adjust the dosage of corticosteroids and the treatment duration with respect to the severity of EM manifestation as well as the primary underlying disorder. In patients with GPEA, corticosteroids are the mainstay of treatment. Patients with GPEA are most frequently treated with 1mg/kg per day of prednisone or its equivalent administered orally. When a clinical response is reached, usually in

several weeks, steroids are tapered down slowly. If a more advanced stage of the disease is present, combined immunosuppressive therapy comprising corticosteroids and cyclophosphamide or azathioprine is usually administered [41]. In a study conducted by Miszalski-Jamka et al., patients suffering from GPEA in whom noncorticosteroid immunosuppressive treatment was initiated at the time of diagnosis less frequently had new onset or progression of heart failure in comparison with subjects in whom this therapy was started later on.

The evidence supporting this widely used therapy with interferon alpha combined with corticosteroid in lymphoid essential hyper eosinophilia is modest and is based only on case reports, case series, and small nonrandomized studies meanwhile the benefit of this therapy is suggest by those studies.

## References

- Fozing T, Zouri N, Tost A, Breit R, Seeck G, Koch C, et al. Management of a patient with eosinophilic myocarditis and normal peripheral eosinophil count: case report and literature review. *Circ Heart Fail.* 2014; 7, 692-694.
- Pollack A, Kontorovich AR, Fuster V, Dec GW. Viral myocarditis—diagnosis, treatment options, and current controversies. *Nat Rev Cardiol.* 2015; 12: 670-680.
- Kindermann I, Barth C, Mahfoud F, Ukena C, Lenski M, Yilmaz A, et al. Update on myocarditis. *J Am Coll Cardiol.* 2012; 59: 779-792.
- Pieron M, Cavallaro R, Chimenti C, Smeraldi E, Frustaci A. Clozapine-induced hypersensitivity myocarditis. *Chest.* 2004; 126: 1703-1705.
- Bourgeois GP, Cafardi JA, Groysman V, Hughey LC. A review of DRESS-associated myocarditis. *J Am Acad Dermatol.* 2012; 66: e229-e236.
- Masi AT, Hunder GG, Lie JT, Michel BA, Arend DA, Calabrese LH, et al. The American College of Rheumatology 1990 criteria for the classification of Churg-Strauss syndrome (allergic granulomatosis and angiitis). *Arthritis Rheum.* 1990; 33: 1094-1100.
- Ammirati E, Cipriani M, Musca F, Bonacina E, Pedrotti P, Roghi A, et al. A life-threatening presentation of eosinophilic granulomatosis with polyangiitis. *J Cardiovasc Med (Hagerstown).* 2016; S2: e109-e111.
- Jennette JC, Falk RJ, Bacon PA, Basu N, Cid CM, Ferrario F, et al. Revised International Chapel Hill Consensus Conference Nomenclature of Vasculitides. *Arthritis Rheum.* 2013; 65: 1-11.
- Roehrl MH, Alexander MP, Hammond SBM, Ruzinova JY, Wang CJ, O'Hara Eosinophilic myocarditis in hyper eosinophilic syndrome. *Am J Hematol.* 2011; 86: 607-608.
- Klion AD, Bochner BS, Gleich GJ, Nutman TB, Ret al. Approaches to the treatment of hyper eosinophilic syndromes: a workshop summary report. *J Allergy Clin Immunol.* 2006; 117: 1292.
- Valent P, Klion AD, Horny HP, et al. Contemporary consensus proposal on criteria and classification of eosinophilic disorders and related syndromes. *J Allergy Clin Immunol.* 2012; 130: 607-
- Enko K, Tada T, Ohgo KO, Nagase OO, Nakamura K, Ohta K, et al. Fulminant eosinophilic myocarditis associated with visceral larva migrans caused by *Toxocara canis* infection. *Circ J.* 2009; 73: 1344-1348.
- Ammirati E, Stucchi M, Brambatti M, et al. Eosinophilic myocarditis: a paraneoplastic event. *Lancet.* 2015; 385: 2546.
- Aggarwal HK, Jain D, Kaverappa V, Jain P, Kumar A, Yadav S. Idiopathic hyper eosinophilic syndrome presenting as severe loeffler's endocarditis. *Arq Bras Cardiol.* 2013; 100: 43-46.
- Tai PC, Ackerman SJ, Spry CJ, Dunnette S, Olsen EG, Gleich GJ. Deposits of eosinophil granule proteins in cardiac tissues of patients with eosinophilic endomyocardial disease. *Lancet.* 1987; 1: 643-647.
- Borcuk AC, van Hoeven KH, Factor SM. Review and hypothesis: the eosinophil and peripartum heart disease (myocarditis and coronary artery dissection)—coincidence or pathogenetic significance? *Cardiovasc Res.* 1997; 33: 527-532.
- Al Ali AM, Straatman LP, Allard MF, Ignaszewski AP. Eosinophilic myocarditis: case series and review of literature. *Can J Cardiol.* 2006; 22: 1233-1237.
- Liao YC, Su CS, Teng CL, Wang KY, Lin FY, Ting CT, et al. Acute necrotizing eosinophilic myocarditis in a young woman. *J Chin Med Assoc.* 2012; 75: 536-538.
- Janin A. Eosinophilic myocarditis and fibrosis. *Hum Pathol.* 2005; 36: 592-3; 593.
- Thambidorai SK, Korlakunta HL, Arouni AJ, Hunter WJ, Holmberg MJ. Acute eosinophilic myocarditis mimicking myocardial infarction. *Tex Heart Inst J.* 2009; 36: 355-357.
- Chusid MJ, Dale DC, West BC, Wolff SM. The hyper eosinophilic syndrome: analysis of fourteen cases with review of the literature. *Medicine (Baltimore).* 1975; 54: 1-27.
- Parrillo JE, Borer JS, Henry WL, Wolff SM, Fauci AS. The cardiovascular manifestations of the hyper eosinophilic syndrome. Prospective study of 26 patients, with review of the literature. *Am J Med.* 1979; 67: 572-582.
- Spiegel R, Miron D, Fink D, Gavriel H, Horovitz Y. Eosinophilic pericarditis: a rare complication of idiopathic hyper eosinophilic syndrome in a child. *Pediatr Cardiol.* 2004; 25: 690-692.
- Cooper LT. Myocarditis. *N Engl J Med.* 2009; 360: 1526-1533.
- Skouri HN, Dec GW, Friedrich MG, Cooper LT. Noninvasive imaging in myocarditis. *J Am Coll Cardiol.* 2006; 21; 48: 2085-2093.
- Syed IS, Martinez MW, Feng DL, Glockner JF. Cardiac magnetic resonance imaging of eosinophilic endo myocardial disease. *Int J Cardiol.* 2008; 126: e50-e52.
- Wagner A, Mahrholdt H, Holly TA, Elliott MD, Regenfus M, Parker M, et al. Contrast-enhanced MRI and routine Single Photon Emission Computed Tomography (SPECT) perfusion imaging for detection of sub endocardial myocardial infarcts: an imaging study. *Lancet.* 2003; 361: 374-379.
- Plastiras SC, Economopoulos N, Kelekis NL, Tzelepis GE. Magnetic resonance imaging of the heart in a patient with hyper eosinophilic syndrome. *Am J Med.* 2006; 119: 130-132.
- Puvanewary M, Joshua F, Ratnarajah S. Idiopathic hyper eosinophilic syndrome: magnetic resonance imaging findings in endomyocardial fibrosis. *Australas Radiol.* 2001; 45: 524-527.
- Lanham JG, Elkon KB, Pusey CD, Hughes GR. Systemic vasculitis with asthma and eosinophilia: a clinical approach to the Churg-Strauss syndrome. *Medicine (Baltimore).* 1984; 63: 65-81.
- Sablé-Fourtassou R, Cohen P, Mahr A, Pagnoux C, Mouthon L, Jayne D, et al. Antineutrophil cytoplasmic antibodies and the Churg-Strauss syndrome. *Ann Intern Med.* 2005; 143: 632-638.
- Guillevin L, Cohen P, Gayraud M, Lhote F, Jarrousse B, Casassus P. Churg Strauss syndrome. Clinical study and long-term follow-up of 96 patients. *Medicine.* 1999; 78: 26-37.
- Neumann T, Manger B, Schmid M, Kroegel C, Hansch A, Kaiser WA, et al. Cardiac involvement in Churg-Strauss syndrome: impact of endomyocarditis. *Medicine (Baltimore).* 2009; 88: 236-243.
- Vignaux O, Marmursztejn J, Cohen P, Bruguière E, Duboc D, Guillevin L, et al. Image rie cardia quedan sles vascularite sassociées aux ANCA. *Presse Med.* 2007; 36: 902-906.
- Baccouche H, Yilmaz A, Alscher D, Klingel K, Val-Bernal JF, Mahrholdt H. Magnetic resonance assessment and therapy monitoring of cardiac involvement in Churg-Strauss syndrome. *Circulation.* 2008; 117: 1745-1749.
- Vlahodimitris I, Kyrtsonis MC, Lionakis N, Votteas V, Moyssakis I. Transient left ventricular dysfunction in Churg-Strauss syndrome: a case report. *Cases J.* 2009; 2: 6564.
- Wassmuth R, Göbel U, Natusch A, Schneider W, Kettritz R, Dietz R, et al.

- Cardiovascular magnetic resonance imaging detects cardiac involvement in Churg-Strauss syndrome. *J Cardiac Fail.* 2008; 14: 856-860.
38. Guillevin L, Pagnoux C, Seror R, Mahr A, Mouthon L, Le Toumelin P, et al. The five-factor score revisited: assessment of prognoses of systemic necrotizing vasculitides based on the French Vasculitis Study Group (FVSG) cohort. *Medicine.* 2011; 90: 19-27.
39. Guillevin L, Cohen P, Gayraud M, Lhote F, Jarrousse B, Casassus P. Churg Strauss syndrome. Clinical study and long-term follow-up of 96 patients. *Medicine.* 1999; 78: 26-37.
40. Masi T, Hunder GG, Lie JT, Michel BA, Bloch DA, Arend WP, et al. The American college of rheumatology 1990 criteria for the classification of churg-strauss syndrome (allergic granulomatosis and angiitis). *Arthritis and Rheumatism.* 1990; 33: 1094-1100.
41. Miszalski-Jamka T, Szczekliak W, Sokolowska B, Karwat K, Malek LA, Jazwiec P, et al. Non corticosteroid immunosuppression limits myocardial damage and contractile dysfunction in eosinophilic granulomatosis with polyangiitis (Churg-Strauss syndrome). *Journal of the American College of Cardiology.* 2015; 65: 103-105.