

Case Report

Huge and Ruptured Amoebic Liver Abscess Diagnosed by Metagenomic Next-Generation Sequencing

Wang W, Song D, Li X and Xie H*

Department of Critical Care Medicine, Shanghai, Haining Road, China

*Corresponding author: Hui Xie, Department of Critical Care Medicine, Shanghai, No. 100, Haining Road, China

Received: May 28, 2021; Accepted: June 28, 2021;

Published: July 05, 2021

Abstract

A 46-year-old white man, presented to the emergency department with backache for 2 weeks, which aggravated with right upper abdominal pain for 1 day without fever. He was homosexual with normal dietary habits and no history of alcoholism or smoking. Contrast-enhanced CT showed a huge mass with several smaller masses underneath occupying the right lobe of liver, with large amount of abdominal and pelvic effusion. The huge liver abscess was punctured under the guidance of bedside ultrasound, and the punctured fluid was also like "anchovy sauce" (a total of 2620ml). The mNGS of the pus near the wall of the abscess cavity showed *Entamoeba histolytica*. An amoebic liver abscess was diagnosed. The patient's condition was stable after metronidazole administration and drainage of pus. He was hospitalized in the ICU for 18 days and for another 24 days in the general ward of the hospital. The results obtained in this case highlights that the use of mNGS for rapid diagnosis of huge and ruptured amoebic liver abscess in non-endemic areas without capability of serologic tests.

Keywords: Amoebic liver abscess; Metagenomic next-generation sequencing

Introduction

Amoebic Liver Abscess (ALA) is caused by a protozoan parasite, *Entamoeba histolytica*, which is the most common extra intestinal presentation of infection with the protozoan [1]. Worldwide, areas of high incidence of infection include India, Africa, Mexico and parts of Central and South America. Although the prognosis of simple abscesses is favourable, complex abscesses and large abscesses may rupture and be associated with high mortality [2]. The diagnosis of amoebic liver abscesses is made through a combination of characteristic findings on imaging and serologic testing (antigen or antibody testing). Colonic carriage can also be asymptomatic, and when patients present with amoebic liver abscesses, their stool microscopy is often negative for *E. histolytica*. Therefore, clinical history of colitis or stool microscopy cannot be relied upon for making the diagnosis of ALA [1-3]. Metagenomic Next-Generation Sequencing (mNGS) is being increasingly applied in clinical laboratories for unbiased culture independent diagnosis [4], which has been rarely reported in diagnosing ALA. In this report, we presented a unique patient who had huge and ruptured ALA without typical symptom or travel history of an endemic area. The patient was diagnosed by mNGS and had a favourable clinical outcome after

Metronidazole therapy and liver abscess drainage.

Case Presentation

A 46-year-old white man, presented to the emergency department with backache for 2 weeks, which aggravated with right upper abdominal pain for 1 day without fever. He had complained of weight loss for the previous six months. He had a medical history of hypothyroidism and denied the history of hepatitis. He was homosexual with normal dietary habits and no history of alcoholism or smoking. He came to China two years ago, working as a foreign

teacher. Before that, He had lived in Europe for a long time and had no travel history in Africa, India or other regions.

The physical findings on admission were as follows: body height 184cm, body weight 67 kg, blood pressure 134/83mmHg, pulse rate 120 beat/min, and body temperature 36.9°C. His heart and respiratory sounds were clear. The abdomen is flat and soft, with negative peritoneal irritation and mild tenderness of the right upper abdomen. A clinical laboratory examination showed elevated inflammatory markers (WBC $19.07 \times 10^9/L$, Neutrophils count $18.06 \times 10^9/L$, C-reactive protein 248.1mg/L), an immunosuppressive status (NK cell 54cells/ul, CD4⁺ 503 cells/ul, CD8⁺ 288 cells/ul) and hepatic dysfunction (total bilirubin 24.4 μ mol/L, alkaline phosphatase 861U/L, γ -glutamyl trans peptidase 143U/L). The albumin concentration was low (29.9 g/L). The patient tested negative for HBV antigen, HCV antigen, HEV antigen, HIV antibody and syphilis. Whole blood was negative for tumor markers. Contrast-enhanced CT showed a huge mass with several smaller masses underneath occupying the right lobe of liver, with large amount of abdominal and pelvic effusion (Figure 1). The right diaphragm was markedly elevated.

Considering that the diagnosis was not clear, on the first day after admission, the left lower abdomen was punctured and drained for the pelvic effusion, and a large amount of odorless anchovy-sauce-like fluid was discharged (a total of 3,030ml), which suggested the rupture of hepatic lesions (Figure 2). No bacteria or amoebic protozoa were found by a rapid microscopic examination. The samples of blood and purulent ascites were collected for mNGS assay to detect the pathogen, but the results were all negative.

Based on the characteristics of the drained fluid, liver abscess was suspected. Therefore, we initiated intravenous ceftriaxone and metronidazole administration.

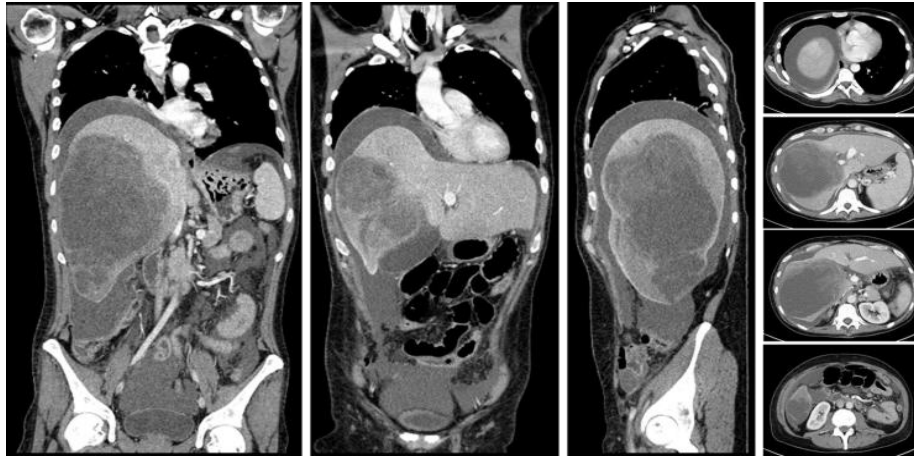


Figure 1: Contrast-enhanced CT showed a 23.5x14.2x14.3 cm irregular iso/low mixed density lesion noted in the right hepatic lobe. The margins are not very clear. After contrast, heterogeneous mild enhancement noted on the lesion with partial cystoid density in the lesion noted without evident enhancement. There was a large amount of abdominal and pelvic effusion. The right hemidiaphragm and the diaphragmatic apex region of right hepatic lobe elevated markedly.

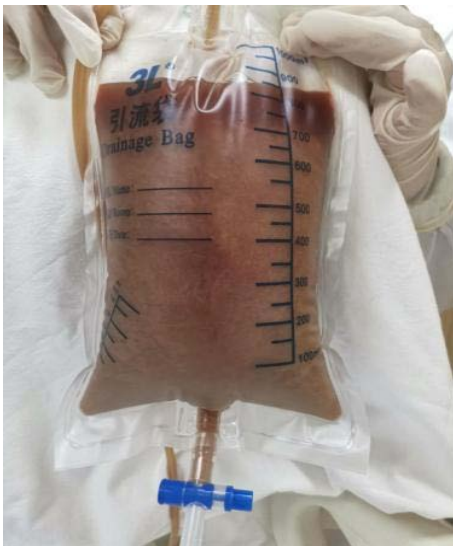

Figure 2: The ascites was anchovy-sauce-like fluid which indicated the possibility of amebic liver abscess.

To further clarify the diagnosis, on day 3 after admission, a liver Contrast Enhanced Ultrasonography (CEUS), which performed before and after the administration of Sulphur Hexafluoride Microbubbles (SonoVue) with grayscale scanning technique in real time, revealed a giant mixed echo mass (13.5*12.3 cm) in the right hepatic lobe. The mass boundary is not clear and irregular morphology. After SonoVue contrast administration, there is no enhancement in the peripheral and internal area of the mass (Figure 3, Video 1). Puncture and drainage were performed successively under the right phrenic (a total of 1790ml odorless anchovy-sauce-like fluid) and crypt effusion of liver. Routine bacteriological culture and metagenomic Next-Generation Sequencing (mNGS) were inspected, all of which were also negative. On the fifth day after admission, the huge liver abscess was punctured under the guidance of bedside ultrasound, and the punctured fluid was also like “anchovy sauce” (a total of 2620ml). The abscess in the center and around the

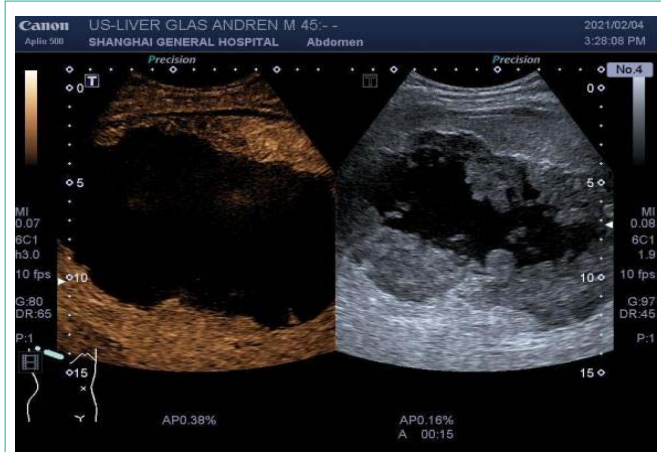


Figure 3: The right liver lobe showed a mixed echo conglomeration, range of about 13.5*12.3 cm, and the boundary is not clear. The shape is irregular, with no obvious blood flow signal. After SonoVue contrast administration, no enhancement in the peripheral and internal area of the mass.

abscess cavity were sent for bacteriological culture and mNGS assay. The cultures of the pus were negative for any microorganisms. In the mNGS of the pus center, 5 sequences of *Entamoeba*, relative abundance is 94.9% and 3 sequences of *Entamoeba histolytica* were found. The mNGS of the pus near the wall of the abscess cavity showed 1087 sequences of *Entamoeba*, relative abundance is 99.7% and 306 sequences of *Entamoeba histolytica*, identify confidence is 99.0%. Amebic liver abscess was diagnosed in combination with the history of homosexual behavior, the drained fluid, imaging findings and mNGS results. But unfortunately, his stool microscopies were consistently negative for 5 times. At present, there is no literature supporting that mNGS can assist in the diagnosis of amoeba disease. Therefore, further serologic tests were needed. However, there is no hospital or company testing amoeba antigen or antibody in Shanghai, China.

The patient's condition was stable after metronidazole administration and drainage of pus. He was hospitalized in the

ICU for 18 days and for another 24 days in the general ward of the hospital. After that he was discharged receiving oral metronidazole 500 mg three times a day.

Discussion

Amebic liver abscess is the most common extra intestinal manifestation of infection with *E. histolytica* [1,2], which is more commonly found in patients with a state of poverty, poor sanitary conditions and immunocompromised status or in homosexuals [5]. ALA rates are 3-20 times higher in adult men between the ages of 18 and 50 than other groups [1,5,6]. The reason is not clear but thought to be due to factors such as hormonal effects and alcohol consumption [2]. Although the prognosis for most patients with ALA is favourable, the mortality rate may rise to 18% in patients with risk factors including jaundice, hypoalbuminemia, large volume abscess, multiple abscess cavities, and encephalopathy [7]. Our case has three risk factors of high mortality (hypoalbuminemia, large volume abscess and multiple abscess cavities). This kind of patients needs to be diagnosed as early as possible to ensure aggressive treatment.

The diagnosis of an amebic liver abscess is made through a combination of the relevant epidemiology and clinical manifestations coupled with radiographic studies and serologic tests.

Individuals can present with ALA months to years after travel or residency in endemic regions including India, Africa, Mexico, and Central and South America. So a careful travel history is important for making the diagnosis. The patient in this case had never been to endemic area. He had a decent job and had always been in good sanitary conditions. In addition to ingesting contaminated food or water, oral and anal sex are other ways of transmission, particularly among men who have sex with men [8,9]. This patient was homosexual and he might be infected through sexual activity. The patient also had lymphocytopenia on admission, which indicated that he might be in immunocompromised status. We tested him for HIV for three times, which were all negative. After treatment, the patient's lymphocyte count returned to normal.

Nearly 4/5 patients with this disease develop symptoms within 2 to 4 weeks [2]. The most common symptoms are fever, pain and hepatomegaly. In patients with acute onset, the fever is generally present in about 98% of the cases. Almost all patients suffer from abdominal pain, which is the earliest and most frequent complaint. ALA arises from hematogenous spreading through the portal circulation. The right lobe is a frequent location which is most likely due to its larger volume, and it receiving most of the venous drainage from the right colon, a segment of the bowel frequently affected by intestinal amebiasis [5,10]. Therefore, most patients feel the pain in right upper quadrant abdomen. In abscesses of the left lobe, the pain is located in the upper abdomen and left hypochondria, which may lead to pericardial effusion and even cardiac tamponade [10,11]. Less than one-third of patients experience associated gastrointestinal symptoms, and nearly half patients complain of weight loss [5,10]. Jaundice is reported in less than 10% of the cases, which may indicate deterioration of hepatic function and the worsen prognosis [5,10].

Ultrasound findings of ALA include a hypoechoic and homogeneous round- or oval-shaped appearance, distal sonographic enhancement, no significant wall echoes, and location near or

contiguous with the liver capsule. A target pattern with a dense echogenic center and a hypoechoic periphery may also be seen. A focal liver lesion combined with diaphragmatic disruption is quite specific for ALA [12].

CEUS is a new advanced method to study the liver and detect abscesses. After contrast administration, ALA was reported as a slight strengthening of the parietal portion of the lesions, with no further findings of solid contextual components [13]. The CT feature in cases with ALA is round or oval low attenuation mass that may contain internal septations. The wall of the abscess typically measures 3-15 mm thick, enhances with contrast and may be surrounded by a rim of edema [12]. However, the ultrasound, contrast enhanced ultrasound and CT findings of this patient were inconsistent with previous reports due to the huge and ruptured liver abscess with multiple cavities, and they cannot help us to make the diagnosis.

Amoebic serology is highly sensitive (>94%) and highly specific (>95%) for the diagnosis of ALA, although the test may be negative in the first 7-10 days of illness [14]. In non-endemic areas like Shanghai, there is no hospital or company testing amoeba antibody or antigen. With the use of PCR assays detecting DNA in serum, pus and stool for diagnosis of ALA had been reported, which remains unvalidated [3,5,15,16]. It still needs to confirm false positivity and negativity rates with independent studies. It is worth noting that when patients present with ALA, their stool microscopy is often negative for *E. histolytica*. Thus, stool microscopy cannot be relied upon for making the diagnosis [5].

We used the mNGS to detect the pathogen in blood and purulent ascites from the ruptured abscess, but the tests were all negative. When we got samples from the center and edge of the abscess cavity, only sequences of *E. histolytica* were detected. Interestingly, there were far more sequences detected at the edge of the abscess cavity than in the center. The reason might be that an amebic liver abscess is not a true abscess but pockets of necrotic debris. Amebic lysis of neutrophils at the edge of the lesion releases mediators, and this leads to hepatocyte death, extending the damage to distant hepatic cells and increasing the number of small lesions that coalesce to develop a larger hepatic lesion. The reddish-brown color of the abscess content is due to the digestion of liver tissue and red blood cells, which might be the characteristic of ALA. The trophozoites can be found at the edge of the lesion, but are rarely detected in the pus or within the abscess cavity itself [10]. The negative results of the blood and ascites samples also indicated the low possibility of bacterial liver abscess. Currently, mNGS assays come to the clinical forefront usually in the event of a failure to identify causal agents by means of traditional methods. It performs well in detecting uncommon, novel and co-infecting pathogens and provides new diagnostic clues for difficult-to-diagnose infections in critically ill or immunodeficient patients [4]. Cost is another great concern regarding the use of mNGS in infectious disease diagnostics. This strategy could be interesting in high-income countries, where the prevalence of ALA appears to be low.

Treatment entails the use of metronidazole at a dose of 500 mg to 750 mg by mouth or intravenously 3 times per day for 7 to 10 days, and the cure rate for which is over 90%. There is no drug resistance in amebiasis. Most patients treated with metronidazole improve within

72-96 h. Drainage should only be considered in cases with a high risk of ruptured abscess (diameter ≥ 5 cm or lesions in the left lobe), which have no clinical response to antibiotics within 5-7 days, and in cases of bacterial coinfection of amoebic liver abscess [1,2,5,10,17]. This patient was given metronidazole empirically according to the “anchovy sauce” color of the ascites with close monitor of his clinical condition. Drainage of his huge abscess was necessary for both diagnosis and treatment.

Our case highlights the use of mNGS for rapid diagnosis of huge and ruptured amoebic liver abscess in non-endemic areas without capability of serologic tests.

References

1. Anesi JA, Gluckman S: Amebic liver abscess. *Clinical liver disease*. 2015; 6: 41-43.
2. Jackson-Akers JY, Prakash V, Oliver TI: Amebic Liver Abscess. In: StatPearls. edn. Treasure Island (FL). 2021.
3. Douglas NM, Baird RW, Currie BJ. Use of a rapid faeces multiplex PCR assay for diagnosis of amoebic liver abscess. *Pathology*. 2020; 52: 725-727.
4. Han D, Li Z, Li R, Tan P, Zhang R, Li J. mNGS in clinical microbiology laboratories: on the road to maturity. *Critical reviews in microbiology*. 2019; 45: 668-685.
5. Stanley SL. Amoebiasis. *Lancet*. 2003; 361: 1025-1034.
6. Maltz G, Knauer CM. Amebic liver abscess: a 15-year experience. *The American journal of gastroenterology*. 1991; 86: 704-710.
7. Sharma MP, Dasarathy S, Verma N, Saksena S, Shukla DK. Prognostic markers in amoebic liver abscess: a prospective study. *The American journal of gastroenterology*. 1996; 91: 2584-2588.
8. Kannathasan S, Muruganathan A, Kumanan T, de Silva NR, Rajeshkannan N, Haque R, et al. Epidemiology and factors associated with amoebic liver abscess in northern Sri Lanka. *BMC public health*. 2018; 18: 118.
9. Kannathasan S, Muruganathan A, Kumanan T, Iddawala D, de Silva NR, Rajeshkannan N, et al. Amoebic liver abscess in northern Sri Lanka: first report of immunological and molecular confirmation of aetiology. *Parasites & vectors*. 2017; 10: 14.
10. Salles JM, Moraes LA, Salles MC. Hepatic amoebiasis. *The Brazilian journal of infectious diseases: an official publication of the Brazilian Society of Infectious Diseases*. 2003; 7: 96110.
11. Francis C, Soni S, Gupta A, Agstam S. A case report of ruptured amoebic liver abscess causing cardiac tamponade and requiring pericardial window. *European heart journal Case reports*. 2020; 4: 1-4.
12. Benedetti NJ, Desser TS, Jeffrey RB. Imaging of hepatic infections. *Ultrasound quarterly*. 2008; 24: 267-278.
13. Marenga G, Traficante S, Ragonici S, Vincenzi C, Rocchetti M, De Rito G, et al. Successful Diagnosis of a Longstanding Giant Amoebic Liver Abscess Using Contrast-Enhanced Ultrasonography (CEUS): A Case Report in a Western Country. *The American journal of case reports*. 2019; 20: 493-498.
14. Stanley SL, Jackson TF, Foster L, Singh S. Longitudinal study of the antibody response to recombinant *Entamoeba histolytica* antigens in patients with amoebic liver abscess. *The American journal of tropical medicine and hygiene*. 1998; 58: 414-416.
15. Ghelfenstein-Ferreira T, Gits-Muselli M, Delliere S, Denis B, Guigue N, Hamane S, et al. *Entamoeba histolytica* DNA Detection in Serum from Patients with Suspected Amoebic Liver Abscess. *Journal of clinical microbiology*. 2020; 58.
16. Othman N, Mohamed Z, Verweij JJ, Huat LB, Olivos-Garcia A, Yeng C, et al. Application of real-time polymerase chain reaction in detection of *Entamoeba histolytica* in pus aspirates of liver abscess patients. *Foodborne pathogens and disease*. 2010; 7: 637-641.
17. Kumar R, Ranjan A, Narayan R, Priyadarshi RN, Anand U. Evidence-based therapeutic dilemma in the management of uncomplicated amoebic liver abscess: A systematic review and meta-analysis. *Indian journal of gastroenterology: official journal of the Indian Society of Gastroenterology*. 2019; 38: 498-508.