

## Clinical Image

# Three-Dimensional Representation of Fused Teeth Using Micro-Computerized Tomography

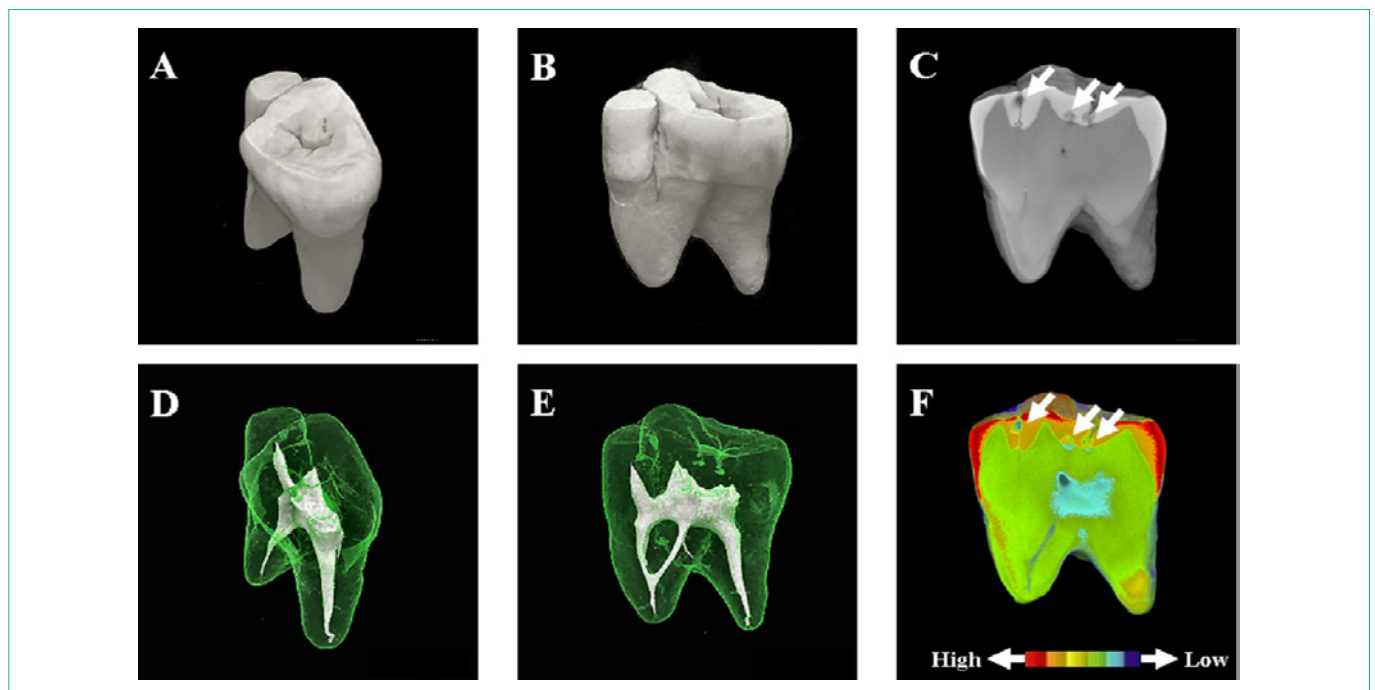
Toshiko Inoue<sup>1\*</sup>, Makoto Saito<sup>1</sup>, Masato Yamamoto<sup>2</sup>, Fumio Nishimura<sup>1</sup> and Takashi Miyazaki<sup>1</sup>

<sup>1</sup>Department of Conservative Dentistry, Division of Biomaterials and Engineering, Showa University School of Dentistry, 1-5-8 Hatanodai, Shinagawa-ku, Tokyo 142-8555, Japan

<sup>2</sup>Department of Chemistry, College of Arts and Sciences, Showa University, 4562 Kamiyoshida, Fujiyoshida, Yamanashi 403-0005, Japan

\*Corresponding author: Toshiko Inoue, Department of Conservative Dentistry, Division of Biomaterials and Engineering, Showa University School of Dentistry, 1-5-8 Hatanodai, Shinagawa-ku, Tokyo 142-8555, Japan

Received: September 15, 2014; Accepted: December 11, 2014; Published: January 05, 2015



**Figure 1:** Fusion (synodontia or false germination) is defined as the union of two or more separately developing tooth germs at the dentinal level when the crown is not yet mineralized to yield a single, large tooth during odontogenesis. The figure depicts a fused premolar imaged with the aid of micro-computerized tomography. (A) Top view, (B) Side view, (C) Sectional image. The arrows in (C) indicate caries sites. (D, E) Three-dimensional representations of the root canals. (F) Pseudo-color images generated using micro-CT data.

Warmer colors denote high mineral density, whereas cooler colors indicate low mineral density. The arrows in (F) indicate caries sites in (C), with clear mineral density. Clinical protocols require that attention is given to fused teeth because of their unusual morphology. Computerized tomography allows for three-dimensional, non-destructive visualization of image data sets, and X-ray micro-CT offers notable information *in vitro*, on the morphology of extracted teeth.