

Editorial

Severe Oligodontia of Permanent Teeth in a Non-Syndromic Young Patient

Del Corso G*Department of Biomedical and Neuromotor Sciences,
University of Bologna, Italy***Corresponding author:** Giacomo Del Corso,
Department of Biomedical and Neuromotor Sciences,
Italy**Received:** June 06, 2017; **Accepted:** June 15, 2017;**Published:** June 23, 2017**Editorial**

Oligodontia represents the absence of more than 6 teeth excluding third molars. Oligodontia of permanent teeth is a severe problem for patients. Usually the absence of teeth is related to a genetic syndrome, but in some cases it is related to a non-syndromic isolated familial trait [1]. Syndromic oligodontia is accompanied with changes on the skin, nails, eyes or skeleton [2]. Few studies in literature describe non-syndromic patients with severe oligodontia of permanent teeth [3-4].

Our finding refers to a 10-year-old asiatic boy who was referred to our dental clinic because his parents were worried about the absence of permanent teeth. Intraoral examination revealed the presence of deciduous teeth and complete anodontia of permanent teeth excluded the first molars. Buccal mucosa was normal. The radiographic evaluation revealed the absence of permanent teeth and germs, apart from the germs of second molars and the erupted first molars (Figure 1). His parents present a normal dentition and they referred the same in their respective families. The boy was non syndromic, the facial and nails examination revealed no abnormality. A diagnosis of non-syndromic severe oligodontia was made. Oral rehabilitation with implant-supported prosthesis will have to be made in adult age. Control and maintenance of deciduous teeth is fundamental in order to maintain them until the adult age.

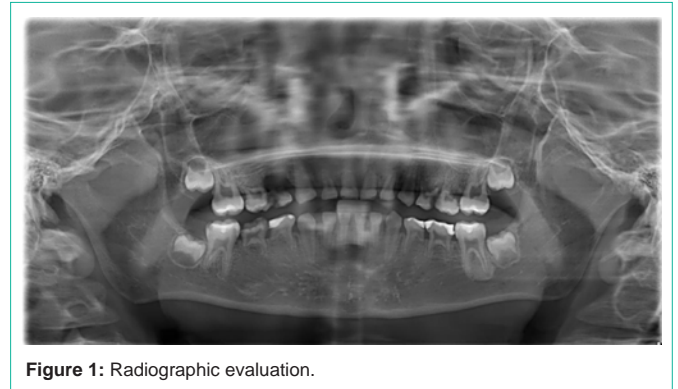


Figure 1: Radiographic evaluation.

This case is the first described in the literature so far and it represents the extreme variability of genetic disorders of the oral mouth.

Bibliography

1. Kotsiomi E, Kassa D, Kapari D. Oligodontia and associated characteristics: assessment in view of prosthodontic rehabilitation. *Eur J Prosthodont Restor Dent.* 2007; 15: 55-60.
2. Schalk-van der Weide Y, Beemer FA, Faber JA, Bosman F. Symptomatology of patients with oligodontia. *J Oral Rehabil.* 1994; 21: 247-261.
3. Rathee M, Malik P, Dua M, Yadav V. Early functional, esthetic, and psychological rehabilitation of preschool child with nonsyndromic oligodontia and anodontia in mixed dentition stage through conservative systematic approach: A casereport with 5-year follow-up. *Contemp Clin Dent.* 2016; 7: 232-235.
4. Moses J, Gurunathan D, Rangeeth BN, Kannan KS. Non-syndromic oligodontia of primary and permanent dentition: 5 year follow up- a rare case report. *J Clin Diagn Res.* 2013; 7: 776-779.