

Case Report

Extensive Amalgam Tattoo (Amalgam Pigmentation) on the Palatal Mucosa: A Case Report

Fiqhi MK^{1*}, Essaoudi MA², Khalfi L¹ and Khatib KE¹

¹Department of Plastic, Maxillofacial and Oral Surgery, Mohammed V Military Teaching Hospital, Rabat, Morocco

²Department of Anatomic Pathology, Mohammed V Military Teaching Hospital, Rabat, Morocco

*Corresponding author: Fiqhi Mohammed Kamal, Department of Plastic, Maxillofacial and Oral Surgery, Mohammed V Military Teaching Hospital, Rabat, Morocco

Received: March 02, 2018; Accepted: April 03, 2018; Published: April 10, 2018

Abstract

Introduction: Amalgam tattoo is the most common exogenous oral pigmentation, caused by traumatic implantation of dental amalgam into soft tissue.

Observation: We report a case of large amalgam pigmentation on right hard palate.

Discussion: Amalgam tattoo can sometimes be confused with melanotic lesions, being then biopsied. Once the diagnosis of amalgam tattoos has been established, the removal of lesions is not necessary, except for esthetic reasons.

Keywords: Amalgam tattoo; Oral mucosa; Pigmentation

Introduction

Oral pigmentations may be classified into two major groups on the basis of their clinical appearance: focal and diffuse pigmentations. All pigmented oral cavity lesions should be viewed with suspicion to eliminate a malignant melanoma. This article deals with an extensive amalgam tattoo lesion on palatal mucosa which required a biopsy for a definitive diagnosis.

Case Presentation

A 56-year-old man with an unremarkable medical history was referred to the department of maxillofacial surgery on suspicion of mucosal melanoma. Clinical examination found a large brown flat macula located on the right hard palate adjacent to a restored tooth 16 with presence of amalgam fillings (Figure 1). There was no lymphadenopathy. Panoramic X-ray did not show any abnormalities. A biopsy was performed under local anesthesia. Histology showed brownish-black pigment along the collagenous fibres and in the vascular sheaths. No melanocytes or naevus cells were found (Figure 2). The findings suggested the diagnosis of amalgam tattoo. The patient didn't need any further treatment.

Discussion

Amalgam tattoos are common exogenous pigmented lesions of the oral mucosa occurring mainly by accidental displacement of metal particles in oral soft tissues during restorative dental procedures using amalgam. The diagnosis is simple, clinically amalgam tattoo presents as a slate-gray, bluish or black macule, Lesions are usually well circumscribed, uniformly pigmented, measuring from 0.1 to 2 cm [1], they affect mainly the mandibular gingival mucosa, followed by the buccal mucosa, floor of mouth, tongue, retromolar mandibular area, lips, and palate [2]. Periapical X-rays may be useful to detect the radio-opacity related to amalgam. However, less than 25% of amalgam pigmentations are radio-opaque since their metallic particles are very small or are too dispersed to be visible in a radiographic study [2,3].

Amalgam tattoo may be a cause for biopsy when confused with melanosis (especially when there is no radiopacity) or when they are

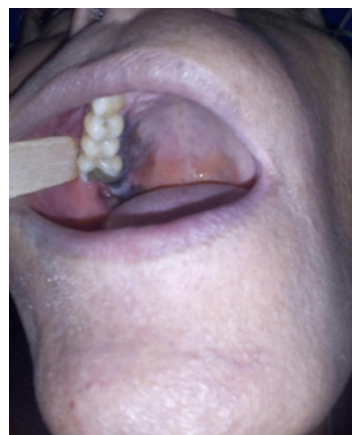

Figure 1: 56-year old man with large mucosal pigmentation, extending from the right maxillary canine to the tuberosity.

often located away from any restorations, in the present case, a biopsy was performed due to the large extension of the lesion. Microscopic examination reveals an intact surface epithelium, fine golden-brown granules disposed along connective tissue fibers and basement membrane staining of collagen a golden-brown color (this may be the only sign of an amalgam tattoo); dense fibrosis and scarring are usually present; granulomatous reaction may be associated [4]. Diagnostic of amalgam tattoo can be difficult to discern from other pigmented elements of the oral mucosa including mucosal melanoma, naevocellular nevus and blue nevus, Hemangioma, Post-inflammatory pigmentation, Smoker's melanosis, drug induced hyperpigmentation and oral pigmentation associated with systemic diseases (like Addison's disease, Albright's syndrome, Acromegaly, and Nelson's syndrome) [5]. The removal of amalgam tattoo is not necessary, except for cosmetic reasons. If the pigmentation is cosmetically unacceptable, surgical excision and transplantation of oral mucosal tissue has been suggested. Q-switched ruby laser and Q-switched alexandrite laser have been used with favorable outcome [4]. In the present case, there was no need to remove the pigmentation,

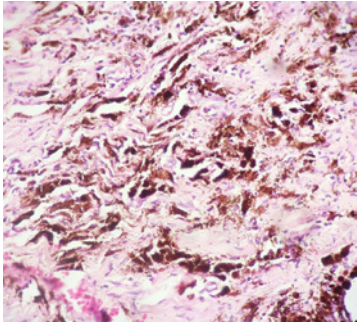


Figure 2: Histological section of the palatine mucosa; HESx40 showing deposition of fine particles along reticular fibers and vascular basement membrane.

as it did not cause any esthetic or functional discomfort to the patient.

Conclusion

Amalgam tattoo is one of the most frequent causes of exogenous pigmentation in the oral mucosa. The reported case shows an unusual form of extensive amalgam tattoo probably due to continual migration of metal particles to the palatal mucosa during chewing. The therapy most often involves surgical excision while in the recent period the laser therapy has provided exceptional results.

References

1. Meleti M, Vescovi P, Mooi WJ, Van der Waal L. Pigmented lesions of the oral mucosa and perioral tissues: a flow-chart for the diagnosis and some recommendations for the management. *Oral Surg Oral Med Pathol oral Radiol Endod.* 2008;105: 606-616.
2. Buchner A, Hansen LS. Amalgam pigmentation (amalgam tattoo) of the oral mucosa. A clinicopathologic study of 268 cases. *Oral Surg Oral Med Oral Pathol.* 1980; 49:139-147.
3. Amano H, Tamura A, Yasuda M, Yamanaka M, Takeuchi Y, Sasaoka K, et al. Amalgam tattoo of the oral mucosa mimics malignant melanoma. *J Dermatol.* 2011; 38: 101-103.
4. Buchner A. Amalgam tattoo (amalgam pigmentation) of the oral mucosa: clinical manifestation, diagnosis and treatment. *Refuat Hapeh Vehashinayim (1993).* 2004; 3: 25-28.
5. Eisen D. Disorders of pigmentation in the oral cavity. *Clin Dermatol.* 2004;70:682-683