

## Clinical Image

# Multidisciplinary Approach of Bilateral Lateral Incisor Anodontia Therapy

Mladenovic R<sup>1\*</sup>, Djordjevic F<sup>1</sup>, Ckonjovic N<sup>2</sup> and Mladenovic K<sup>3</sup>

<sup>1</sup>Faculty of Medicine, University of Pristina, Department for Dentistry, Kosovska Mitrovica, Serbia

<sup>2</sup>Health Center, Kosovska Mitrovica, Serbia

<sup>3</sup>Faculty of Medical Sciences, University of Kragujevac, Kragujevac, Serbia

\*Corresponding author: Rasa Mladenovic, Faculty of Medicine, University of Pristina, Department for Dentistry, Kosovska Mitrovica, Serbia

Received: July 05, 2019; Accepted: July 11, 2019;

Published: July 18, 2019

## Clinical Image

Case of a multidisciplinary approach in the aesthetic and functional therapy of bilateral lateral incisor Anodontia in a 14-year-old girl. In addition to the frenectomy and fixed orthodontics, adhesive bridges were made, up to the permanent prosthetic solutions (fixed prosthesis, implantology) after 18 years of age. In one visit, with the direct technique was made an adhesive bridge on both sides with GC ever Stick C&B (GC Europe) and a set of GC Gradia composite materials (GC, Europe) (Figure 1). This technique does not require tooth grinding and can be easily modified or removed from the tooth without damaging teeth, and meets aesthetics and function.

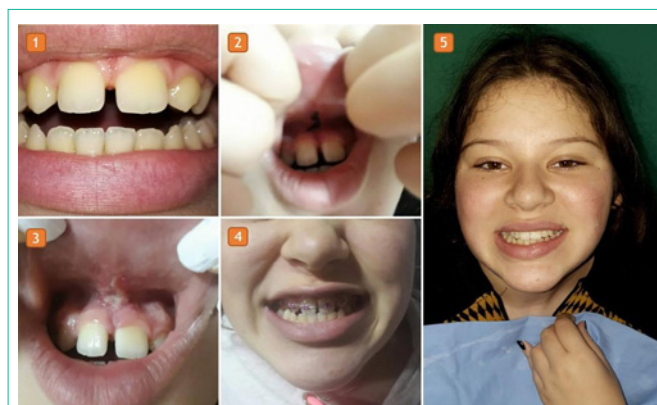


Figure 1: Clinical procedure.