

Clinical Image

Oculocardiac Reflex: An Unusual Trigger during Dental Surgery

Arora V* and Alex Lee A

Department of Anesthesiology & Amp, Pain Medicine,
University of Washington, Seattle WA, USA

***Corresponding author:** Vivek Arora, Department
of Anesthesiology & Amp, Pain Medicine, University of
Washington, Seattle WA, USA

Received: April 25, 2020; **Accepted:** May 13, 2020;

Published: May 20, 2020

Clinical Image

The Oculocardiac reflex can be triggered by manipulation of the periorbital structures during ophthalmological and oral maxillofacial procedures [1]. When a Ring-Adair-Elwyn (RAE) naso-Endotracheal Tube (ETT) is used, adequate fixation is necessary to prevent tube displacement. Custom-made supports e.g. surgical scrub brush, foam pieces or surgical towels positioned over the forehead are commonly used to support the preformed curvature of nasal RAE ETT's [2]. This image was created to represent the causative mechanism of OCR in a 48yr-old-male who developed severe bradycardia during dental implant placement under general anesthesia with a nasal RAE ET. A folded surgical towel under the RAE tube had slipped over the orbit transmitting pressure from the surgeon's hand above the drapes onto the globe, thus triggering the OCR. Although unclear at the time of hemodynamic instability this cause was revealed when surgical drapes were removed at the end of the procedure.

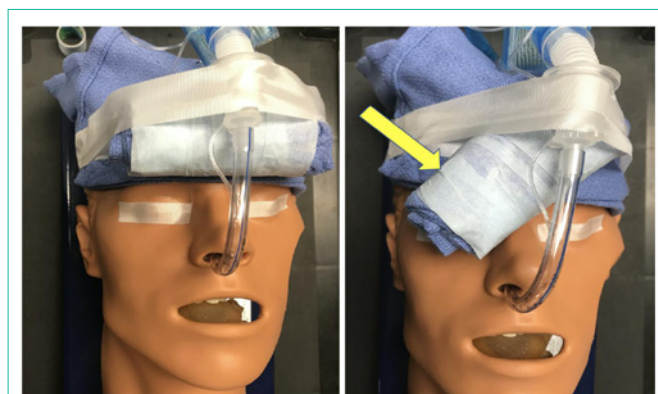


Figure 1: Oculocardiac Reflex: An Unusual Trigger During Dental Surgery.

References

1. Doyle DJ, Mark PW. Reflex bradycardia during surgery. *Can J Anaesth.* 1990; 37: 219-222.
2. Farbod F, Tuli P, Robertson BF, Jackson IT. Endotracheal tube fixation methods for optimal stability: a comparison of adhesive tape, suture, and tape-suture fixation. *J Craniofac Surg.* 2010; 21: 1250-1251.