

## Research Article

# Diode Laser Treatment of Onychomycosis: A New Horizon in Management

**Mosbeh A\*, Aladl A and Abdo HM**

Department of Dermatology, Al-Azhar University, Egypt

**\*Corresponding author:** Al-Sadat Mosbeh,

Department of Dermatology, Faculty of Medicine, Al-Azhar University, Abbasyia, Cairo, Egypt

**Received:** December 07, 2017; **Accepted:** December 08, 2017; **Published:** December 12, 2017**Abstract**

**Objective:** To investigate if Diode laser-808 nm treatment has the potential to eradicate onychomycosis.

**Patients and Methods:** Forty patients with a total of 102 mycotic toe nails were randomized to the treatment group (808-nm Diode laser) or control group (no laser treatment). We conducted four laser treatments at 4 to 6 week intervals. In both groups, a local antimycotic agent was applied to the sole of the foot, the area between the toes and the skin directly surrounding the nails. The primary endpoint was complete remission of the onychomycosis after 12 months (fungal culture and histology); secondary endpoints included clinical improvement (Onychomycosis Severity Index, OSI) and the occurrence of pain or other adverse events.

**Results:** A comparison of both groups' OSI scores showed no significant differences at baseline ( $P > 0.05$ ). In both groups, toenails had solely a *Trichophyton rubrum* infection. The primary endpoint of mycological remission (i.e. no evidence of infection in fungal culture and PAS stain), while the secondary endpoint is improvement of clinical appearance of the nails using the Onychomycosis Severity Index (OSI). In the OSI scores, there were no statistically confirmed differences between the two groups. No adverse effects were observed in either the laser or the control group.

**Conclusion:** The Diode laser 808-nm shows a long-term efficacy as a monotherapy. Its role as an adjuvant therapy should be investigated in upcoming trials.

**Keywords:** Diode laser 808 nm; Onychomycosis

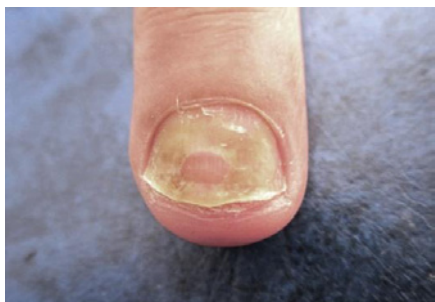
## Introduction

In more than 99% of patients, onychomycosis is caused by a dermatophyte infection. The most common causative pathogen is *Trichophyton rubrum* and the second most common is *Trichophyton mentagrophytes* [1,2]. Only rarely are molds and candidal species the cause [1,3]. Onychomycosis is the most widespread nail disorder occurring in adults [4,5]. The reported prevalence ranges between 2 and 13%. The risk of infection increases significantly with increasing age. About 30% of patients between the ages of 60 and 70 years of age have infection and among 70-year-olds about 50% [2,6]. The incidence appears to be rising in all age groups [5]. The treatment of onychomycosis remains challenging. Both topical and systemic antifungal agents are associated with treatment failures, need for long-term therapy, high rates of recurrence, and significant costs [7-11]. The commonly used ciclopirox or amorolfine (Loceryl<sup>®</sup>, Galderma) nail lacquer take a long time to eradicate the infection and rarely completely cures severe onychomycosis [9]. Also, most patients have concomitant fungal infection of the foot which goes untreated. Systemic treatment is usually with terbinafine, itraconazole, or fluconazole. The list of adverse effects and possible drug interactions is long [12,13]. At present there is no cost-effective, safe, effective, and easy-to-use alternative. Along with photodynamic treatment [14], in recent years [15] there have been increasing reports on the successful use of laser treatment for onychomycosis. Still, very few

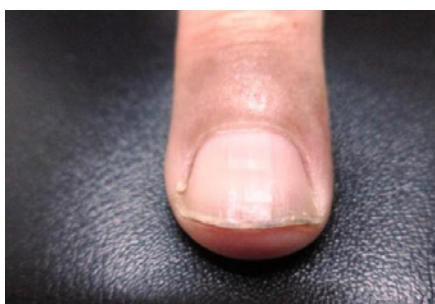
data are available. So far, only three clinical studies have examined the positive effect of treatment with Diode laser (808 nm) [16,17] and diode laser with wavelengths of 870/930 nm [18]. There are also a few publications on *in vitro* results of laser therapy. Kozarev and colleagues treated *Trichophyton rubrum* *in vitro* once with long-pulsed Nd: YAG laser (wavelength: 1064 nm, fluence: 40 J/cm<sup>2</sup>, spot size: 4 mm, pulse duration: 35 ms) and reported a significant, visible regression of the fungus after three days [16]. The biological and physical effects of laser treatment on dermatophytes are still uncertain and have been variously discussed in published studies. The advantages of laser treatment of onychomycosis are self-evident. In the present study, we conducted our own tests using the protocols for treatment of *Trichophyton rubrum* *in vitro* which have been reportedly successful.

## Patients and Methods

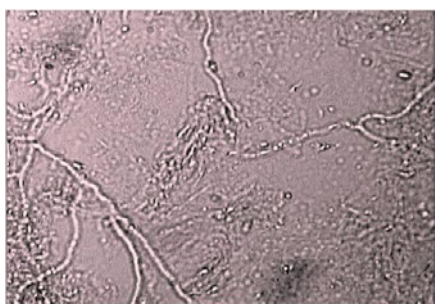
It is a prospective study was performed at Dermatology Department, Al-Azhar University hospitals, Cairo, Egypt. Patients over the age of 18 with a clinical diagnosis of distolateral subungual onychomycosis were enrolled consecutively; the diagnosis was confirmed by Koh 20% and means of positive dermatophyte culture on a selective agar plate (ServoPlate<sup>®</sup> IVD, Servoprax GmbH, Germany) after incubation at 30 °C for 4 weeks (Figures 1,3-5). If the fungal culture was negative, a histopathological examination



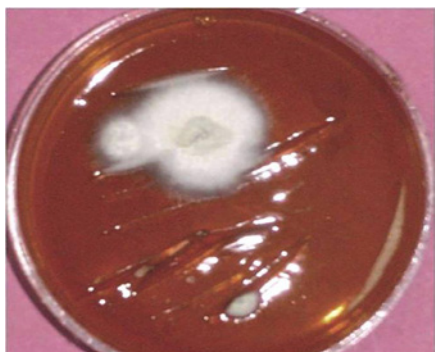
**Figure 1:** Distal and lateral subungual onychomycosis affecting right middle finger before laser treatment.



**Figure 2:** Same patient 3 months after laser treatment.

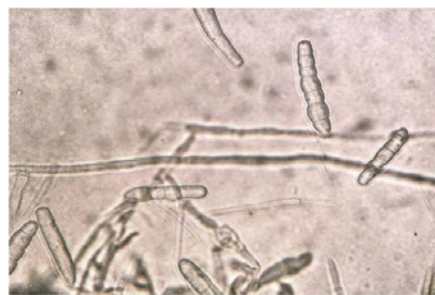

**Figure 3:** KOH test: long tubular branched septate hyphae with some arthroconidia (KOH mount x 200).

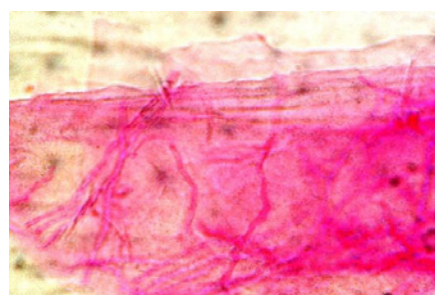


**Figure 4:** Macroscopic morphology of *T. rubrum*: surface- colony is white cottony, flat to slightly raised, suede-like texture.

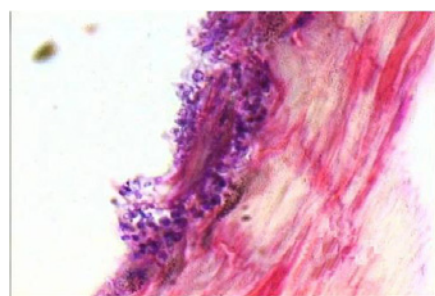
was done using periodic acid-Schiff (PAS) stain on representative nail clippings (Figures 6,7). Nails with a negative PAS stain were not included.



**Figure 5:** Microscopic morphology of *T. rubrum*: typical smooth thin-walled cigar-shaped septate macroconidia (water 200 x).



**Figure 6:** PAS-positive reddish branching hyphae within the nail plate (PAS staining x 200).



**Figure 7:** PAS-positive arthrospores within the under surface of the nail plate (PAS staining x 200).

Ages Eligible for Study: 18 Years to 80 Years (Adult, Senior)

Genders Eligible for Study: Both

Accepts Healthy Volunteers: No

**Inclusion criteria**

- Confirmed subungual onychomycosis in a great toe that does not extend to the eponychium
- Fitzpatrick Skin Type I-IV
- Written and verbal informed consent
- Able to comply with study instructions and to return to the clinic for required visits
- Agrees to refrain from other active topical, laser or light-based treatment to the great toes
- Agrees to the use of Naftin Gel between the toes to prevent/control tinea pedis

### Exclusion criteria

- Pregnancy, breastfeeding or planning to become pregnant
- History of cutaneous photosensitivity, porphyria and hypersensitivity to porphyrins or photodermatoses
- Any skin pathology or condition that could interfere with the evaluation or that requires the use of interfering topical or systemic therapy
- Coagulation disorder or current use of anti-coagulation medication (including aspirin use of greater than 81 mg per day)
- Any condition which, in the investigator's opinion, would make it unsafe for the subject to participate
- Enrolled in an investigational drug or device trial, or has been treated with an investigational device or received an investigational drug within 30 days
- Oral Lamisil within 1 year, Sporanox or over-the-counter topicals within 1 month, or other prescription anti-fungal medications or topicals within 6 months
- Evidence of diabetic neuropathy or peripheral vascular disease related to diabetes, or a loss of protective sensation in the affected foot
- Psoriasis, lichen planus, infection involving the lunula, prior surgical treatment of the affected great toe within 1 year, or a history of trauma to the affected great toe
- Immunocompromised status, or with existing (or history of) cancer/skin malignancy
- Distal nail thickness of greater than 2mm in the affected great toenail

### Laser treatment

Laser treatment was performed using an 808-nm linear scanning diode laser which is mainly indicated for hair removal, vascular lesion treatments and achieving non-ablative skin rejuvenation, and the first two systems are routinely used for hair removal. The parameter settings used were selected according to the results of the first experiment: 808 nm, a fluence of 9-27 J/cm<sup>2</sup> and a pulse duration of 6 ms at a spot size of 12/12 (6-well plates) or 12/50 mm (glass Petri dishes).

### Study design

We conducted a single-blind randomized controlled pilot study from February 2014 to December 2015. The study protocol was reviewed by the ethics committee of the Medical Faculty, Al-Azhar University.

An independent medical assistant randomized the patients to the treatment group or the control group. The randomization list was generated using a web-based program (<http://www.random.org/lists/>), and the randomized allocation took place by assigning even numbers to the treatment group and odd numbers to the control group.

### Treatment protocol

Twenty-four hours before starting treatment, all patients

were informed about the laser treatment, potential side-effects and therapeutic alternatives; they then gave their written consent. Patients were not invoiced for their laser treatment. Since the laser beam cannot evenly penetrate a discoloured or hyperkeratotic nail plate, these parts of the nail were debrided down to a thickness of approximately 1 mm by a certified podologist using a high-speed nail grinder. This occurred immediately prior to the beginning of the trial and prior to the third session (out of four). Laser treatment was performed using an FDA-approved Diode laser 808 nm (PinPoint™ Footlaser™). The technical treatment parameters corresponded to the manufacturer's recommendations and were as follows: fluence of 20 J/cm<sup>2</sup>; pulse duration of 0.1 ms; spot size of 1.5 mm; pulse rate of 30 Hz. Regardless of initial clinical or mycological findings, the entire nail plate, the lateral and the proximal nail wall of all nails (including the nail matrix) were treated. The laser pulses were applied in a checkerboard pattern with minimal overlapping. A total of five laser passes (alternating in a transversal and longitudinal direction) were administered on each toe. All in all, four treatments were conducted by a medical assistant under a physician's supervision at intervals of 4-6 weeks. The patients and the assistant wore adequate eye protection at every session.

All patients were instructed to treat the soles of their feet, the area between the toes and the skin directly surrounding the nails with an antimycotic cream containing amorolfine (Loceryl™ cream, Galderma Laboratorium GmbH) for the duration of the entire study period. This step was taken to provide adequate prophylaxis against re-infection in the event of a therapeutic response and to ensure that the treatment outcomes were not skewed. Patients were also given information on appropriate hygiene (e.g. sprinkling an antimycotic powder in the shoes, wearing cotton socks). Patients in the control group were not treated with the laser; all other conditions were identical to those in the treatment group.

### Assessment of therapeutic endpoints

The primary endpoint was defined as the proportion of the nails where mycological remission could be determined; this was defined as the absence of pathogens in fungal culture and histopathological examination (PAS stain) 12 months after the final laser treatment. If one of these methods revealed evidence of a fungal infection, the primary endpoint was failed. In such cases, the patients were treated in compliance with German therapeutic guidelines for onychomycosis [6].

The secondary endpoint was the clinical appearance of the nails using the Onychomycosis Severity Index (OSI). To this end, photos were taken at the beginning and at the end of the study using the same digital single-lens reflex camera (Canon EOS 350D with an EF-S 60 mm f/2.8 macro USM lens, Canon Inc., Tokyo, Japan) at a standardized distance and under identical lighting conditions. The assessment was performed by two independent blinded investigators who were not otherwise involved in the study; they multiplied the score for the affected area (0-5 points) by the score for the proximity of the affected area to the nail matrix (1-5 points) as described in [7]. Ten more points were added if longitudinal lines or subungual hyperkeratoses were visible. The total score also led to three categories of onychomycosis severity: 'mild' (equating to a score of 1-5), 'moderate' (6-15) and 'severe' (16-35).

**Table 1:** Number of complete remission of infections in the total study population.

	Laser	Control	P -value
Number of complete remission	15/64	10/38	> 0.05

**Table 2:** Comparison of OSI scores at the beginning and end of the trial (in the total study population).

Group	Number of nails	OSI at the beginning of treatment	OSI after 6 months	Differences
Laser	64	24.1 ± 5.8	22.3 ± 6.1	2.5 ± 1.1
Control group	38	25.1 ± 4.9	23.7 ± 5.1	2.1 ± 1.2
P value	> 0.05			

**Adverse effects and pain**

To document the profile of adverse effects, the treating medical assistant used a survey prior to every session to record the occurrence of oedema, burning, blisters, (new occurrences of) onychodystrophy, infections, nerve damage or delayed wound healing. Pain during laser treatment was quantified using a visual analogue scale to answer the question ‘How intense is your pain right now?’ (0 = ‘no pain’ to 10 = ‘most intense pain’).

**Statistical analysis**

All statistical calculations were performed using the statistical software package SAS, Release 9.3 (SAS Institute Inc., Cary, NC, USA). Absolute and relative frequencies were given for quality characteristics; mean, standard deviation, minimum and maximum values were determined for quantitative variables. To detect group differences, a variance analysis with repeated measurements was performed using the SAS procedure, SAS MIXED. This approach permits to observe concurrently whether there is a distinction between groups (treatment vs. control group), whether changes occur over time (beginning vs. end) and if interactions can be confirmed. The P-value of the interaction indicates whether temporal changes in both groups have a significant difference. Furthermore, t-tests for two independent samples were taken to compare groups at a particular point in time (beginning vs. end). The Wilcoxon test for paired samples was used to determine the severity between the points ‘beginning’ and ‘end’. The outcome of the statistical analysis was deemed significant when the P-value was below 0.05. Findings with P-values between 0.05 and 0.10 were considered ‘slightly significant’.

**Results**

The treatment group consisted of 12 female and 10 male patients with a mean age of 49.3 ± 22 years. In the control group, 8 woman and 10 men were enrolled with a mean age of 45.9 ± 20 years. The treatment group comprised a total of 64 toenails with distolateral subungual onychomycosis; a total of 38 were in the control group. A comparison of both groups’ OSI scores showed no significant differences at baseline (P > 0.05) (Figure 1,2). In both groups, toenails had solely a Trichophyton rubrum infection. The primary endpoint of mycological remission (i.e. no evidence of infection in fungal culture and PAS stain), while the secondary endpoint is improvement of clinical appearance of the nails using the Onychomycosis Severity Index (OSI) (Figure 3-7). In the OSI scores, there were no statistically confirmed differences between the two groups. In the treatment group, patients used the visual analogue scale to indicate pain during treatment at a median score of 5 (minimum of 1, maximum of 7). No

**Table 3:** Comparison of disease severity at the beginning and end of the trial based on OSI scores (in the total study population).

	Laser group		Control group	
	Beginning	End of course	Beginning	End of course
Mild (1-5)	4	30	3	15
Moderate (6-15)	42	12	29	11
Severe (16-35)	18	7	6	2
P value	> 0.05			

other adverse effects were observed in either the laser or the control group (Tables 1-3).

**Discussion**

In a previous study, two sessions of treating mycotic nails with a short-pulsed 1064-nm-Nd: YAG laser led to negative fungal cultures in 70% of cases 9 months later; this was histologically confirmed in 20% by means of a positive PAS stain [5]. In compliance with the manufacturers recommendations for the device used in the study, the laser sessions were performed on toenails that were not debrided.

To optimize the treatment protocol, in this subsequent trial, the hyperkeratotic parts of the nail were debrided, and the number of sessions was increased from two to four. To further improve the comparability of findings, we performed all treatments on a population that was as homogeneous as possible, i.e. all nails enrolled had a clinically uniform manifestation of distolateral onychomycosis with subsequent confirmation of Trichophyton rubrum alone. Furthermore, the duration of follow-up was extended to 6 months. In contrast to the studies published to date, we defined mycological remission in the fungal culture and PAS stain as the medically relevant primary endpoint; since this is not automatically equivalent to clinical resolution of the nail.

The findings of this study were unequivocal, albeit unexpected: in long-term follow-up, monotherapy with the short-pulsed 808-nm-Nd: YAG laser showed a mycological remission and clinical (cosmetic) improvement.

The following points should be discussed in order to better interpret our current findings in detail, especially the differences with regard to previous researches [4,5]. A transient improvement and subsequent worsening (as described in) [5] could be regarded as evidence that several laser treatment sessions are needed over a longer period of time to achieve at least a clinical (cosmetic) improvement.

In addition, it is worth discussing whether debriding hyperkeratotic parts of the nail might have a direct effect on laser-tissue interaction due to a decrease in the number of potential target chromophores. It remains unclear whether the tendency towards longer treatment intervals (2-4 vs. 4-6 weeks) in this study had a paradoxical effect. *In vitro* studies have shown that sub lethally damaged mycelia can regenerate within a few days, [8] and in some cases even increased growth in fungal cultures may occur [9].

Our current findings appear to indicate that larger-scale studies are not necessarily justified. We demonstrated that the OSI score improved by a mean 2.0 points in the treatment group, and in the control group. If we assume that this relatively minor difference in the OSI scoring system has a rather subordinate clinical relevance,

further research with a larger population (and thus, more a narrow confidence interval) would not yield more compelling findings than the results of this pilot study.

When summarizing all of the results of the randomized controlled trials on laser treatment of onychomycosis published to date, [5,10-17] there are hardly any correlating endpoints which make it possible to compare the wide range of findings. Thus, no valid conclusions for practical application can be found, in particular because the findings of numerous studies entailed a follow-up period of 3-6 months, [11,13-16] mycological diagnostics that were inadequate or lacking altogether, [10,13-17] an insufficient number of treatment sessions [10] or a study population with inhomogeneous clinical involvement [11,12] and varying fungal species (dermatophytes, moulds and yeasts) [10-12].

Such discrepancies in published results notwithstanding, it would be desirable to gain greater insights into the possible mechanism(s) of action of treating onychomycosis with non-ablative laser devices. For example, at present it is still unclear which chromophores constitute the relevant target of laser treatment. In this context, the varying thermal relaxation times of mycelia and spores have not yet been studied. Importantly, not only does the thermal relaxation time play a key part here, but so does the peak temperature achieved and the duration of this temperature's impact on the organisms and the surrounding skin. Whether or not the relatively short exposure periods are sufficient to kill dermatophytes is open to discussion. The findings of our own *in vitro* study show that this is not the case [4].

Other *in vitro* studies, however, suggest that the use of diode (808 and 890 nm) and Nd: YAG laser devices (1064 nm) can achieve temperatures which inhibit the growth of certain fungal species in culture (e.g. *Candida guilliermondii* or *Trichophyton interdigitale*) while also stimulating the growth of *Trichophyton rubrum*, the most common cause of onychomycosis [9].

Using real-time video thermography, Paasch and co-workers investigated the heat-profile of irradiated nails [18]. Treatment was performed using 808- and 980-nm linear scanning diode lasers. For the 808-nm laser, they achieved mean peak temperatures between 74.1 °C and 112.4 °C. Theoretically, these temperatures are high enough to kill even the spores; it is still not known, however, how long these temperatures need to be maintained to achieve complete pathogen eradication without damaging the surrounding tissue.

## Conclusion

An overview of the current state of research gives rise to the conclusion that at present, we have not (yet) achieved the technical conditions needed for reliable laser treatment of onychomycosis [19]. Initial evidence of potential use of the laser as a complement to guideline-compliant systemic therapy has only recently been published [16,20]. The proper role of laser treatment as an adjuvant modality should thus be examined in further research.

## References

1. US FDA Medical Device 510(k) Clearances. 510(k) number: K093547. Decision date: October 15, 2010. PinPointe FootLaser, PinPointe USA, Inc. [WWW document] 2010.

2. Helou J, Maatouk I, Hajjar MA, Moutran R. Evaluation of Nd: YAG laser device efficacy on onychomycosis: a case series of 30 patients. *Mycoses*. 2016; 59: 7-11.
3. Evaluation Study for the Efficacy and Safety of PinPointe FootLaser in Treatment for Onychomycosis.
4. Hees H, Raulin C, Bäuml W. Laser treatment of onychomycosis: an *in vitro* pilot study. *J Dtsch Dermatol Ges*. 2012; 10: 913-918.
5. Hees H, Jäger MW, Raulin C. Treatment of onychomycosis using the 1064 nm Nd: YAG laser: a clinical pilot study. *J Dtsch Dermatol Ges*. 2014; 12: 322-329.
6. Seebacher C, Brasch J, Abeck D, Cornely O, Effendy I, Ginter-Hanselmayer G, et al. Onychomycosis. *J Dtsch Dermatol Ges*. 2007; 50: 321-327.
7. Carney C, Tosti A, Daniel R, Scher R, Rich P, DeCoster J, et al. A new classification system for grading the severity of onychomycosis: onychomycosis severity index. *Arch Dermatol*. 2011; 147: 1277-1282.
8. Carney C, Cantrell W, Warner J, Elewski B. Treatment of onychomycosis using a submillisecond 1064-nm neodymium:yttrium-aluminum-garnet laser. *J Am Acad Dermatol*. 2013; 69: 578-582.
9. Paasch U, Mock A, Grunewald S, Bodendorf MO, Kendler M, Seitz AT, et al. Antifungal efficacy of lasers against dermatophytes and yeasts *in vitro*. *Int J Hyperthermia*. 2013; 29: 544-550.
10. Hollmig ST, Rahman Z, Henderson MT, Rotatori RM, Gladstone H, Tang JY, et al. Lack of efficacy with 1064-nm neodymium:yttrium-aluminum-garnet laser for the treatment of onychomycosis: a randomized, controlled trial. *J Am Acad Dermatol*. 2014; 70: 911-917.
11. Landsman AS, Robbins AH, Angelini PF, Wu CC, Cook J, Oster M, et al. Treatment of mild, moderate, and severe onychomycosis using 870- and 930-nm light exposure. *J Am Podiatr Med Assoc*. 2010; 100: 166-177.
12. Landsman AS, Robbins AH. Treatment of mild, moderate, and severe onychomycosis using 870- and 930-nm light exposure: some follow-up observations at 270 days. *J Am Podiatr Med Assoc*. 2012; 102: 169-171.
13. Zhang RN, Wang DK, Zhuo FL, Duan XH, Zhang XY, Zhao JY, et al. Long-pulse Nd: YAG 1064-nm laser treatment for onychomycosis. *Chin Med J (Engl)*. 2012; 125: 3288-3291.
14. Waibel J, Wulkan AJ, Rudnick A. Prospective efficacy and safety evaluation of laser treatments with real-time temperature feedback for fungal onychomycosis. *J Drugs Dermatol*. 2013; 12: 1237-1242.
15. Ortiz AE, Truong S, Serowka K, Kelly KM. A 1320-nm Nd: YAG laser for improving the appearance of onychomycosis. *Dermatol Surg*. 2014; 40: 1356-1360.
16. Xu Y, Miao X, Zhou B, Luo D. Combined oral terbinafine and long-pulsed 1064-nm Nd: YAG laser treatment is more effective for onychomycosis than either treatment alone. *Dermatol Surg*. 2014; 40: 1201-1207.
17. Li Y, Yu S, Xu J, Zhang R, Zhao J. Comparison of the efficacy of long-pulsed Nd: YAG laser intervention for treatment of onychomycosis of toenails or fingernails. *J Drugs Dermatol*. 2014; 13: 1258-1263.
18. Paasch U, Nenoff P, Seitz AT, Wagner JA, Kendler M, Simon JC, et al. Heat profiles of laser-irradiated nails. *J Biomed Opt*. 2014; 19: 18001.
19. Gupta AK, Simpson FC, Heller DF. The future of lasers in onychomycosis. *J Dermatolog Treat*. 2015; 13: 1-6.
20. Renner R, Grusser K, Sticherling M. 1064-nm diode laser therapy of onychomycosis: results of a prospective open treatment of 82 toenails. *Dermatology*. 2015; 230: 128-134.