

Clinical Image

Subacute Thyroiditis with Non-Toxic Hyperfunctioning Thyroid Nodules

Samer El-Kaissi*, Christine Hughes and Hussein Saadi

Department of Endocrinology, Cleveland Clinic Abu Dhabi, UAE

*Corresponding author: Samer El-Kaissi, Cleveland Clinic Abu Dhabi, Medical Subspecialties Institute, Department of Endocrinology, PO Box 112412, Al Maryah Island, Abu Dhabi, UAE

Received: August 15, 2016; Accepted: August 22, 2016;

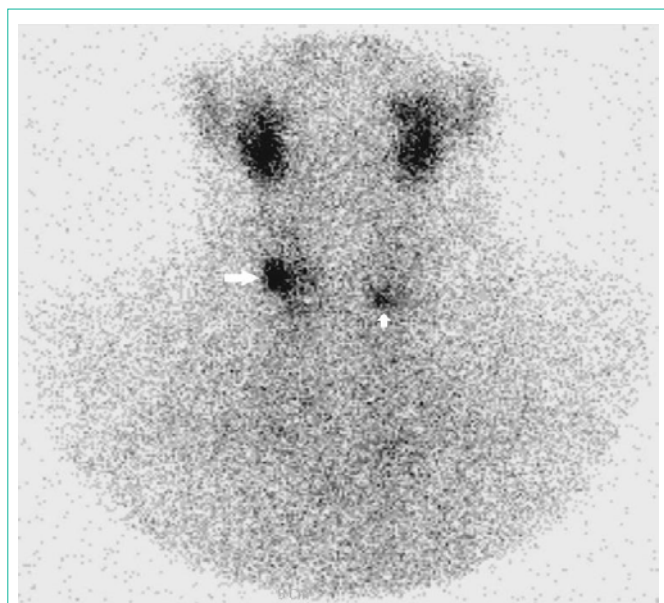
Published: August 23, 2016

Keywords

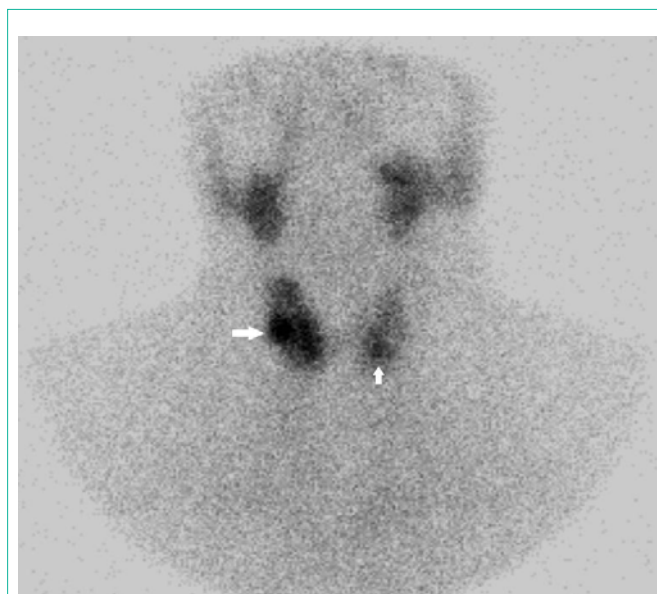
Thyroiditis; Thyroid nodule; Multinodular goitre; Hyperthyroidism

Clinical Image

A 46-year old woman presented with a 4-week history of subacute Thyroiditis following an upper respiratory tract infection. She had thyroid gland tenderness, symptoms of thyrotoxicosis, increased erythrocyte sedimentation rate [45mm/hr], raised free-T4 [29pmol/L] with thyrotropin suppression [0.005mIU/L] and normal free-T3 [5.64pmol/L]. Thyroid ultrasound revealed six small-moderate size nodules. Thyroid 99mTc pertechnetate scan during the thyrotoxic phase (Panel A) showed two foci of increased uptake with little activity in the rest of the gland raising the possibility of coexistent Autonomously Functioning Thyroid Nodules [AFTN] [1].



Panel A: Thyroid 99mTc pertechnetate scan during the hyperthyroid phase showing two foci of increased uptake (white arrows) with little uptake in the rest of the gland. Total tracer uptake 0.2% (normal range 0.2-3%).



Panel B: Thyroid 99mTc pertechnetate scan after resolution of hyperthyroidism and discontinuation of all medications, approximately 10-weeks after the initial scan in Panel A. This scan shows improved tracer uptake in the thyroid at 0.6% (normal range 0.2-3%) but the foci of increased uptake in the right midzone and left lower zone are still apparent (white arrows).

Treatment consisted of oral prednisolone and a β -blocker and in light of the thyroid scintigraphy findings, low-dose carbimazole was added. Repeat nuclear scanning after resolution of thyrotoxicosis and discontinuation of all medications (Panel B) showed persistently increased uptake in the two foci with improved uptake in the rest of the gland. The patient remained asymptomatic and euthyroid after 6-months.

The presence of AFTN on thyroid scintigraphy in a hyperthyroid patient (Panel A) raises the possibility of a toxic multinodular goitre, although the history of neck tenderness, elevated ESR and normal free-T3 were more consistent with subacute thyroiditis and non-toxic hyperfunctioning thyroid nodules. It is estimated that up to 50% of patients with AFTN on thyroid scintigraphy have a normal serum TSH [2]. Non-toxic AFTN can progress to overt hyperthyroidism at 4% per annum depending on iodine intake, patient's age and adenoma size.

References

1. Corvilain B. The natural history of thyroid autonomy and hot nodules. *Ann Endocrinol (Paris)*. 2003; 64: 17-22.
2. Treglia G, Trimboli P, Verburg FA, Luster M4, Giovannella L, et al. Prevalence of normal TSH value among patients with autonomously functioning thyroid nodule. *Eur J Clin Invest*. 2015; 45: 739-744.