

Case Report

A Chinese Woman with Congenital Adrenal Hyperplasia due to 21-Hydroxylase Deficiency after Adrenalectomy: What Did We Ignore of?

Kun Zhang, Xiao Ji, Chunyu Wang, Yaxi Chen, Junrong Ma and Xijie Yu*

Laboratory of Endocrinology and Metabolism, State Key Laboratory of Biotherapy, West China Hospital, Sichuan University, China

***Corresponding author:** Xijie Yu, Laboratory of Endocrinology and Metabolism, State Key Laboratory of Biotherapy, West China Hospital, Sichuan University, No. 37 Guoxue Xiang, Chengdu, Sichuan, People's Republic of China, Tel: 862885422362; Fax: 862885423459; Email: xijieyu@hotmail.com

Received: August 22, 2014; **Accepted:** August 28, 2014; **Published:** August 29, 2014

Abstract

Congenital adrenal hyperplasia (CAH) is not a rare disease, but the possibility of misdiagnosis or late diagnosis is high especially in primary hospitals in China. Here, we report a case of a 53-year-old Chinese woman with CAH due to 21-hydroxylase deficiency after adrenalectomy. The primary physicians gave no diagnosis of CAH and directly performed the surgery for the possibility of compression caused by the large adrenal mass. Postoperatively, the patient experienced repeated hyperkalemia and cutaneous and gingival hyper pigmentation. Meantime, physicians ignored the patient with a history of noncompliance and postoperatively the patient was in danger many times. This study reinforces the close association between CAH and adrenal adenoma. CAH should be considered and baseline follicular-phase early-morning 17-hydroxyprogesterone levels should be measured when discovered adrenal mass or nodule incidentally. Meanwhile, risk for noncompliance should be considered before surgery.

Keywords: CAH; Adenoma; Adrenalectomy; CYP21A2 gene mutations; Noncompliance

Introduction

Congenital Adrenal Hyperplasia (CAH) is a group of inherited autosomal recessive disorders caused by deficiency in one of the enzymes necessary for cortical biosynthesis [1, 2]. The incidence ranges from 1:10,000 to 1:20,000 in births [3]. The most common type of CAH, accounting for approximately 90% cases, is due to 21-Hydroxylase (21-OH) deficiency [4]. The 21-hydroxylase enzyme converts 17-Hydroxy Progesterone (17-OHP) to 11-deoxycortisol and progesterone to deoxycorticosterone, precursors for cortisol and aldosterone respectively. When the enzyme is inadequate or absent the cortisol synthesis will be blocked, which leads to the chronic stimulation of Adrenal Cortex by adrenocorticotropic hormone (ACTH) and the accumulation of cortisol precursors [5]. Some of the precursors are diverted to the biosynthesis of sex hormones, which may cause phenotypes of androgen excess, such as androstenedione and DHEAS. The degree of enzyme activity is strongly in accordance with the clinical severity of CAH. Complete enzyme deficiency leads to classic Salt-Wasting (SW) form presenting as failure to thrive, vomiting, hyperkalemia, dehydration and shock. Partial enzyme deficiency results in classic Simple-Virilizing (SV) isoform characterizing by prenatal ambiguous genitalia in females and pseudo precocious puberty in both sexes. Patients with mild enzyme deficiency caused Non-Classic (NC) isoform, maybe asymptomatic or only present hirsutism, acne and precocious puberty later [5,6].

The CYP21A2 gene is located on the short arm of chromosome 6, HLA III region, adjacent to a pseudo gene (now named CYP21P) [7]. 21-OH deficiency is caused by compound-heterozygous or homozygous mutations in CYP21A2 gene. More than 90% of the point mutations result from intergenic recombination of DNA

sequences between CYP21 and closely adjoined homologous CYP21P gene [8]. The degree of mutations compromising enzyme activity is strongly associated with the clinical severity of CAH. Patients carrying "severe" mutations which destroy all CYP21 activity present the classical SW isoform, whether homozygous or heterozygous mutations. Some "mild" mutations maintain partial enzyme activity, which result in non-classical isoform of CAH. The chronic stimulation of adrenal cortex in 21-OHD is associated with elevated prevalence of the adrenal tumors. Moreover, lack of adherence to regular treatment is also associated with development of adrenal adenoma [9,10]. Clinical physician and surgeon usually ignore this connection.

Case Presentation

A 53-year-old Chinese woman consulted for repeated fatigue and cutaneous and gingival hyper pigmentation over eight-month period after unilateral adrenalectomy. During this period, the patient was admitted to the local hospital three times for hyperkalemia (plasma K peaked 6.05 mmol/L). Before adrenalectomy, she had no history of aforementioned symptoms. She was referred to hospital for knee joint pain and occasionally discovered adrenal mass by Computed Tomography (CT) abdomen. Further questioning history and physical examination revealed that she was a short fat woman and BMI was 27.4 kg/m² (weight 56.8 kg with the height of 144 cm). She was born with clitoromegaly and labial fusion, and did not accept regular treatment and had no discomfort ordinarily. At present, her clitoris was enlarged measured the longitudinal axis of 3.6 cm and transverse diameter of 2.2 cm with small pubic hair (Figure 1). The urethral meatus was normal while the major and minor labia and vaginal introitus were not observed. She was primary amenorrhea with no marital and obstetric history. The systemic skin and gums showed abundant

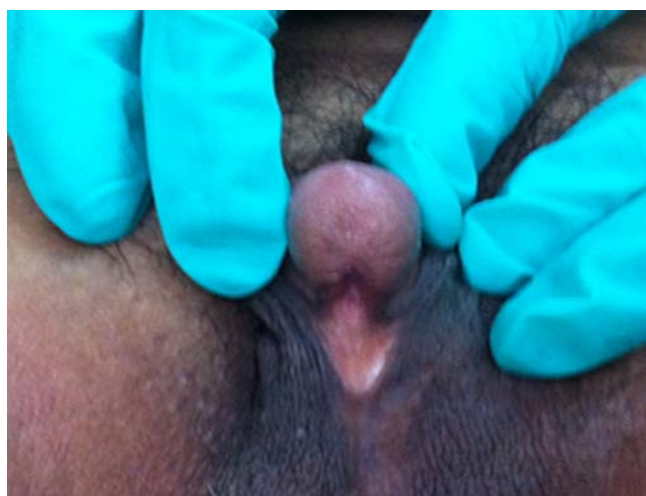

Figure1: Appearance of clitoris in patient whose longitudinal axis measured 3.6cm and transverse diameter 2.2cm.

pigmentation because of postoperative complication. Physical examination revealed normal blood pressure (112/73mmHg), pulse rate (60bpm) and body temperature (36.7°C). The chromosomal analysis showed a normal 46, XX female karyotype.

Endocrine evaluation: The endocrine evaluation was not performed before the operation. Postoperative endocrine assays revealed high levels of serum 17OHP: 12.13ng/mL (normal: 0.1-0.8), serum testosterone: 11.48nmol/mL (normal: 0.5-2.6), ACTH: 1026ng/L (normal: 5-78) and low level of PTC: 38.18nmol/L (normal: 147.3-609.3), serum aldosterone level was normal. Blood electrolyte revealed hyperkalaemia with serum potassium 6.05mmol/L, chlorine 117.1mmol/L and sodium 138.5mmol/L. A pelvic ultrasound revealed a small uterus (diameter < 1.3cm).

Imaging examination: Before surgery, abdominal CT showed a lagenon-homogeneous density mass (diameter > 6cm) in her right adrenal gland with a predominance of lipid augmentation and multiple areas of calcification and a small tubercle in her left adrenal gland (Figure 2). The local hospital performed laparoscopic unilateral adrenalectomy followed by histopathological examination confirmed the diagnosis of adrenal adenoma.

Mutational analysis of CYP21A2 gene: After informed consent was acquired from the patient and her brother, a genetic testing

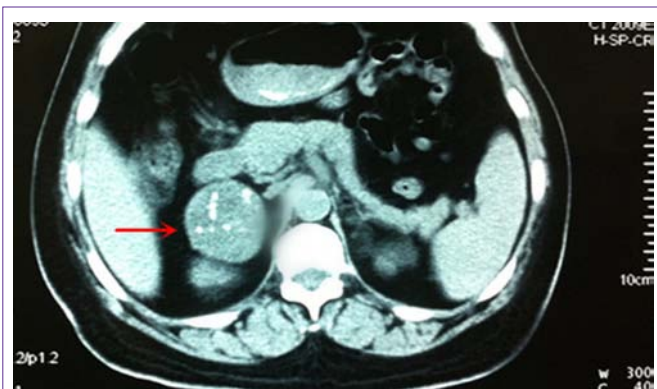


Figure2: A right adrenal mass (diameter > 6cm) before surgery.

was performed. The genetic analysis showed the patient had two heterozygous mutations in the CYP21 gene: a C-to-T transition at nucleotide 1069 resulting in the conversion of an arginine into a tryptophan (Arg357Trp) (Figure 3A) and a C-to-G transition at intron 2 (I2 splice) (Figure 3B). Arg357Trp and I2 splice were two of the most frequent point mutations accounting for 19% and 27% respectively [11]. The previous reports showed that the mutations were presented in SW and SV in the compound heterozygous state.

Discussion

In this case, there are two questions to be taken into consideration. Firstly, many studies reported that 21-OH deficiency could be a predisposing factor for adrenal tumors in patients with CAH [12]. It was assumed that the formation of adrenal tumors could be associated with adrenocortical hyperplasia caused by chronic stimulation of ACTH in CAH patients [13]. Recently the exaggerated response of 17-OHP after ACTH stimulation was further pointed out [14]. Moreover, studies reported clinical silent macro nodular adrenal hyperplasia and adrenocortical adenomas in 80% of CAH patients with homozygous mutations and 45% of CAH patients with heterozygous mutations [12]. Further, Baumgartner et al [15] reported a higher frequency of classic CAH carriers (16%) and of manifest CAH (2%) due to 21-OH deficiency in patients with adrenal adenomas than in the general population. Hence, we should pay attention to the close association between CAH and adrenal adenoma.

With widespread applications of abdominal CT scan, more and more adrenal masses are discovered. Appropriate hormonal evaluation needs to be performed. However, some physicians usually disregarded of CAH when discovered adrenal incidentalomas by abdominal CT scan, especially with no obvious clinical manifestation such as silent or mild NCCAH [12,16]. We recommend that CAH should be considered and baseline follicular-phase early-morning 17-OHP levels should be measured, especially in patients with a history of genital ambiguity. ACTH stimulation test and genotyping may be performed when the value of 17-OHP was equivocal [17]. However, in this case, the physician did not consider of the point when

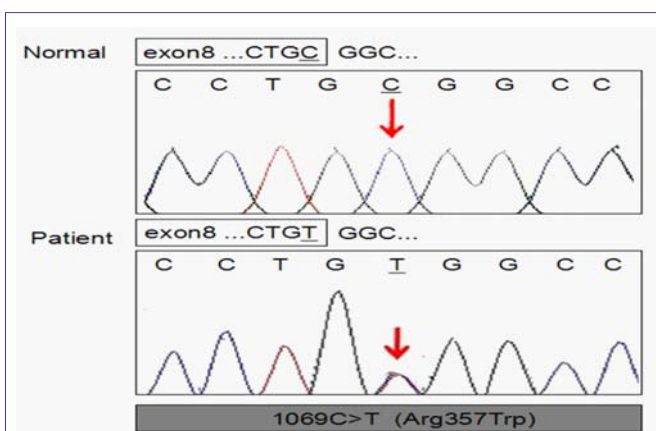


Figure 3a: Sequencing of CYP21A2 genomic DNA from the patient with 21-hydroxylase deficiency. A: 1069C>T (Arg357Trp), B: 293-13C>G (I2 splice). Genomic DNA was extracted from whole blood cell of the patient and a normal control. The DNA was amplified by polymerase chain reaction (PCR) with genetic sequencing technique of Sanger Chain Terminal Method.

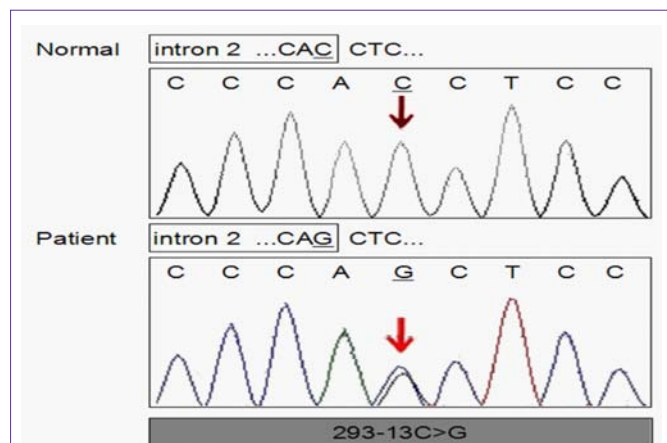


Figure 3b: Sequencing of CYP21A2 genomic DNA from the patient with 21-hydroxylase deficiency. A: 1069C>T (Arg357Trp), B: 293-13C>G (I2 splice). Genomic DNA was extracted from whole blood cell of the patient and a normal control. The DNA was amplified by polymerase chain reaction (PCR) with genetic sequencing technique of Sanger Chain Terminal Method.

discovered adrenal mass. And they did not evaluate hormonal levels and performed the surgery just for the possibility of compression caused by the large adrenal mass. Unfortunately, the patient suffered adrenal crisis postoperatively.

Secondly, bilateral adrenalectomy in the management of the patients with CAH is controversial. Some studies argued that laparoscopic bilateral adrenalectomy as a definitive therapy was superior to conventional medical treatment for classical congenital adrenal hyperplasia [18,19]. Bilateral laparoscope adrenalectomy may improve fertility and weight loss, and lower doses of Glucocorticoid (GC), but increase the risk of postoperative complications mainly owing to deprivation of the protective actions from the adrenal. Van Wyk et al [20] described that 18 published cases of adrenalectomy in CAH, adrenal crises or other serious surgical complications were observed in five patients of their suboptimal glucocorticoid substitution.

Risk for noncompliance or medicine abuse should be considered before surgery. Actually, some physicians pay little attention to this point. Adrenalectomy may not be an optimum for patients with a history of noncompliance or medicine abuse, because it could be fatal for them postoperatively without adequate substitution therapy. If necessary, physicians should make good communications with patients and her family preoperatively. In our patient, she experienced adrenal crisis many times after surgery, mostly due to take the medicine not according to the instruction. Later, we emphasized the importance of close substitution treatment with her and her family many times, and got good effect.

Acknowledgments

This work was supported by grants from the National Natural Science Foundation of China (No. 81370969 to Yu X, No. 81101920 to Ma J), the Ministry of Education of the People's Republic of China (No. 20130181110066 to Yu X).

Conclusion

From this case, we conclude that additional efforts are required to improve the specialized knowledge of Chinese physician or surgeon, especially in primary hospitals in China. When discovered adrenal

mass or nodule incidentally by CT, CAH should be considered and baseline follicular-phase early-morning 17-hydroxyprogesterone level should be measured. Meanwhile, we should not ignore of the importance of patient individuality, including social background, medical compliance, and risk for noncompliance should be considered before surgery.

References

1. New MI. An update of congenital adrenal hyperplasia. *Ann N Y Acad Sci.* 2004; 1038: 14-43.
2. Staniš M, Nesoviš M. [Congenital adrenal hyperplasia]. *Med Pregl.* 1999; 52: 447-454.
3. van der Kamp HJ, Wit JM. Neonatal screening for congenital adrenal hyperplasia. *Eur J Endocrinol.* 2004; 151: 71-75.
4. Riepe FG, Sippell WG. Recent advances in diagnosis, treatment, and outcome of congenital adrenal hyperplasia due to 21-hydroxylase deficiency. *Rev Endocr Metab Disord.* 2007; 8: 349-363.
5. White PC, Speiser PW. Congenital adrenal hyperplasia due to 21-hydroxylase deficiency. *Endocr Rev.* 2000; 21: 245-291.
6. Speiser PW, Azziz R, Baskin LS, Ghizzoni L, Hensle TW, Merke DP, et al. Congenital adrenal hyperplasia due to steroid 21-hydroxylase deficiency: an Endocrine Society clinical practice guideline. *J Clin Endocrinol Metab.* 2010; 95: 4133-4160.
7. Yang Z, Mendoza AR, Welch TR, Zipf WB, Yu CY. Modular variations of the human major histocompatibility complex class III genes for serine/threonine kinase RP, complement component C4, steroid 21-hydroxylase CYP21, and tenascin TNX (the RCCX module). A mechanism for gene deletions and disease associations. *J Biol Chem.* 1999; 274: 12147-12156.
8. Lee HH. CYP21 mutations and congenital adrenal hyperplasia. *Clin Genet.* 2001; 59: 293-301.
9. Khardori R. Adrenal tumor complicating untreated 21-hydroxylase deficiency in a 5 1/2-year-old boy. *Arch Pediatr Adolesc Med.* 1994; 148: 994-995.
10. Kurtoglu S, Atabek ME, Keskin M, Patiroglu TE. Adrenocortical adenoma associated with inadequately treated congenital adrenal hyperplasia. *Journal of pediatric endocrinology & metabolism.* JPEM. 2003; 16: 1311-1314.
11. Khan AH, Aban M, Raza J, Ul Haq N, Jabbar A, Moatter T. Ethnic disparity in 21-hydroxylase gene mutations identified in Pakistani congenital adrenal hyperplasia patients. *BMC Endocr Disord.* 2011; 11: 5.
12. Jaresch S, Kornely E, Kley HK, Schlaghecke R. Adrenal incidentaloma and patients with homozygous or heterozygous congenital adrenal hyperplasia. *J Clin Endocrinol Metab.* 1992; 74: 685-689.
13. Newfield RS, New MI. 21-hydroxylase deficiency. *Ann N Y Acad Sci.* 1997; 816: 219-229.
14. Seppel T, Schlaghecke R. Augmented 17 alpha-hydroxyprogesterone response to ACTH stimulation as evidence of decreased 21-hydroxylase activity in patients with incidentally discovered adrenal tumours ('incidentalomas'). *Clin Endocrinol (Oxf).* 1994; 41: 445-451.
15. Wagnerova H, Lazurova I, Habalova V, Dudasova D, Vrzgula A. The prevalence of 21-hydroxylase deficiency in adrenal incidentalomas - hormonal and mutation screening. *Experimental and clinical endocrinology & diabetes: official journal, German Society of Endocrinology [and] German Diabetes Association.* 2008; 116: 272-275.
16. Chevalier N, Carrier P, Piche M, Chevallier A, Wagner K, Tardy V, et al. Adrenocortical incidentaloma with uncertain prognosis associated with an inadequately treated congenital adrenal hyperplasia. *Ann Endocrinol (Paris).* 2010; 71: 56-59.
17. Costa-Barbosa FA, Tonetto-Fernandes VF, Carvalho VM, Nakamura OH, Moura V, Bachega TA, et al. Superior discriminating value of ACTH-stimulated serum 21-deoxycortisol in identifying heterozygote carriers for 21-hydroxylase deficiency. *Clin Endocrinol (Oxf).* 2010; 73: 700-706.
18. Castillo OA, López-Fontana G, Vitagliano G. Laparoscopic synchronous bilateral adrenalectomy. *Arch Esp Urol.* 2011; 64: 114-120.

19. Gmyrek GA, New MI, Sosa RE, Poppas DP. Bilateral laparoscopic adrenalectomy as a treatment for classic congenital adrenal hyperplasia attributable to 21-hydroxylase deficiency. *Pediatrics*. 2002; 109: 28.
20. Van Wyk JJ, Ritzen EM. The role of bilateral adrenalectomy in the treatment of congenital adrenal hyperplasia. *J Clin Endocrinol Metab*. 2003; 88: 2993-2998.