

## Case Report

# Extramedullary Multiple Myeloma in the Thyroid with Papillary Thyroid Cancer Metastasis to a Parathyroid Gland

Saberi S<sup>1\*</sup>, Schaldenbrand JD<sup>2</sup> and Kimball BC<sup>3</sup>

<sup>1</sup>Ann Arbor Endocrinology and Diabetes PC, USA

<sup>2</sup>Department of Pathology, St Joseph Mercy Hospital

<sup>3</sup>IHA General Surgery Ann Arbor, St Joseph Mercy Hospital, USA

**\*Corresponding author:** Saberi S, Ann Arbor Endocrinology and Diabetes Associates PC, 5333 McAuley Dr, RHB Rm 5115, Ypsilanti, MI 48197, USA, Tel: 734-434-4430; Fax: 734-434-7634; Email: Sima.Saberi@stjoeshealth.org

**Received:** November 01, 2014; **Accepted:** November 28, 2014; **Published:** November 30, 2014

## Abstract

**Objective:** To describe a case of amyloid present in the thyroid gland of a patient with papillary thyroid cancer metastasizing to a parathyroid gland.

**Methods:** We present a case report and review the relevant literature.

**Results:** A 66 year old man with untreated multiple myeloma and subclinical hypothyroidism presents for subclinical hypothyroidism evaluation. He was found to have an abnormal thyroid on physical exam resulting in a thyroid ultrasound being obtained showing a multinodular goiter. Fine needle aspiration of a right thyroid nodule revealed papillary thyroid cancer. Thyroidectomy pathology showed papillary thyroid cancer invading a right inferior parathyroid gland and amyloid in the background thyroid tissue. Due to the presence of amyloid in the thyroid and concern for deterioration in his kidney function, treatment for his multiple myeloma was initiated but the patient expired shortly thereafter from sepsis.

**Conclusion:** Thyroid involvement in multiple myeloma is rare and is a poor prognostic sign. Papillary thyroid cancer metastasizing to the parathyroid gland is also uncommon and its prognosis continues to be debated.

**Keywords:** Papillary thyroid cancer; Parathyroid gland metastasis; Amyloid; Multiple myeloma

## Case Presentation

A 66 year old man with a history of cutaneous T-cell lymphoma diagnosed in 1997, melanoma of the left thigh diagnosed in 2002, untreated multiple myeloma diagnosed in 2008 during the routine evaluation of an elevated serum protein (initial bone marrow biopsy in 2009 with 10% plasma cells and last bone marrow biopsy in 2014 with 46% plasma cells), and subclinical hypothyroidism since at least 2012 presents to the endocrine clinic to discuss his subclinical hypothyroidism. Two months prior to his evaluation in the endocrine clinic he had been started on levothyroxine 50 mcg daily by his primary care physician for a TSH of 7.37 mIU/mL (RR 0.34-3.0 mIU/mL). After starting levothyroxine he noted an improvement in his fatigue and cold intolerance. He had no history of radiation to his head or neck. He had been having hoarseness of his voice episodically for 3 to 4 months prior to presentation but he was not experiencing any dysphagia or shortness of breath. On physical exam his thyroid was bulky and he had 2+ pitting edema in his lower extremities. Due to his abnormal thyroid on physical exam a thyroid ultrasound was obtained. This showed a multinodular goiter with a mid right 3.2 x 1.7 x 2 cm and mid left 2 x 1 x 1.7 cm nodules and no abnormal lymphadenopathy. Right thyroid nodule fine needle aspiration revealed Papillary Thyroid Cancer (PTC). He underwent total thyroidectomy with central compartment dissection. Pathology showed a 4 cm right PTC with isthmus extension, central neck lymph node metastasis, and direct invasion of an inferior right parathyroid gland (Figure 1). The background thyroid tissue and adipose tissue

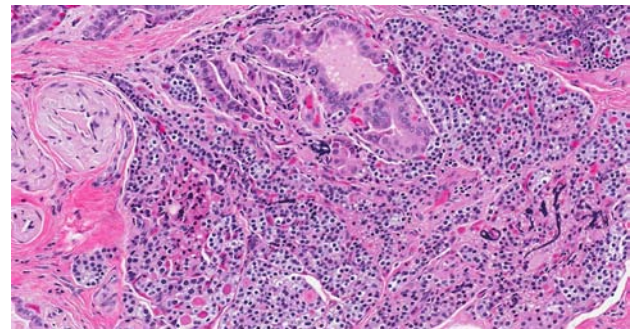


Figure 1: Papillary carcinoma with colloid invades parathyroid (200x, H+E).

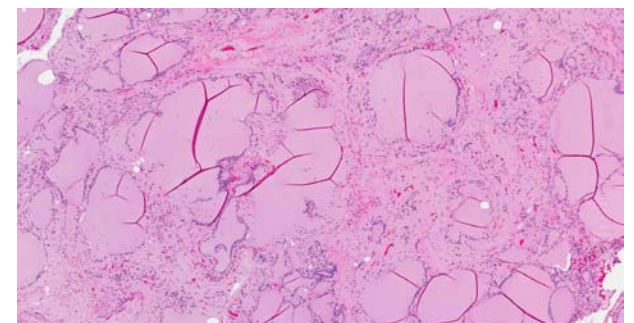


Figure 2: (Non-tumor) thyroid showing widely separated macro-follicles due to stromal amyloid deposits (100x, H+E).

vessels contained amyloid (Figure 2). Four weeks postoperatively his thyroglobulin level was 46 ng/ml (TSH 99.59 mIU/mL). Hypothyroid whole body scan showed uptake in the thyroglossal duct and right thyroid bed; he received 125 mCi radioactive iodine. Because of his lower extremity edema that had been present for over 3 months he followed up with his primary care physician who found him to have proteinuria. Subsequently he was referred to a nephrologist at which time he was noted to have a decrease in his GFR to 43 ml/min with a serum creatinine of 1.61 mg/dl. Therapy for his multiple myeloma was initiated due to the presence of amyloid in the thyroid and the decline in his kidney function. The patient expired from sepsis.

## Discussion

Metastasis to the thyroid gland account for 7.5% of thyroid cancers [1]. The most common cancers metastasizing to the thyroid are lung, esophagus, breast and kidney. Thyroid involvement in multiple myeloma is rare with 3 case reports in the literature [2-4]. Extramedullary multiple myeloma typically carries a poor prognosis and is associated with shorter overall survival [5,6]. Autoimmune thyroid disease has been associated with a higher risk of developing multiple myeloma (odds ratio 5.68; confidence interval 1.69-19.13) [7].

Metastasis to the parathyroid gland typically is from breast, leukemia, melanoma, lung and soft tissue [8]. Thyroid cancer metastasizing to the parathyroid gland is rare and has been seen with papillary thyroid cancer, follicular thyroid cancer and anaplastic thyroid cancer [9]. Incidence rates of PTC metastasizing to a parathyroid gland range between 1.7-7.9% [10,11]. Thyroid cancer more commonly directly invades the parathyroid gland [9,10]. However, it is also hypothesized that metastasis can occur by hematogenous or lymphatic means as direct invasion has not been seen in all cases [8,9]. Chrisoulidou et al found no association with patient age or tumor size for thyroid cancer metastasizing to a parathyroid gland [9]. However a study by Kakudo et al found that patients with parathyroid gland metastasis were more likely to be male, older, have more advanced stage disease, and shorter disease free survival [11]. No correlation has been found between histologic features of thyroid cancer and invasion pattern [8]. There has been conflicting data about the outcomes of these patients as one study showed no change in disease free survival compared to patients with minimal extrathyroidal extension [10] while another study has shown a shorter disease free survival [11].

## Conclusion

Thyroid involvement in multiple myeloma is rare and is a poor prognostic sign. Papillary thyroid cancer metastasizing to the parathyroid gland is also uncommon and its prognosis continues to be debated. This case highlights two rare processes and the important associations of which to be aware.

## References

1. Papi G, Fadda G, Corsello SM, Corrado S, Rossi ED, Radighieri E, et al. Metastases to the thyroid gland: prevalence, clinicopathological aspects and prognosis: a 10-year experience. *Clin Endocrinol (Oxf)*. 2007; 66: 565-571.
2. Alarion N, Kelly A, Fouilhoux G, Darcha C, Trechot I, Da Costa V, et al. Case of thyroid involvement by multiple myeloma. *J Clin Oncol*. 2013; 31: e380-382.
3. Weisser F, Reuter C, Taverna C. Extramedullary manifestations of multiple myeloma in the thyroid gland and in the lungs: excellent response to therapy. *Ann Hematol*. 2010; 89: 1183-1184.
4. Serefhanoglu S, Sayinalp N, Haznedaroglu IC, Goker H, Cetiner D, Aksu S, et al. Extramedullary plasmacytomas of the thyroid and pericardium as initial presentation of multiple myeloma. *Ann Hematol*. 2008; 87: 853-854.
5. Usmani SZ, Heuck C, Mitchell A, Szymonifka J, Nair B, Hoering A, et al. Extramedullary disease portends poor prognosis in multiple myeloma and is over-represented in high-risk disease even in the era of novel agents. *Haematologica*. 2012; 97: 1761-1767.
6. Varettoni M, Corso A, Pica G, Mangiacavalli S, Pascutto C, Lazzarino M. Incidence, presenting features and outcome of extramedullary disease in multiple myeloma: a longitudinal study on 1003 consecutive patients. *Ann Oncol*. 2010; 21: 325-330.
7. Dalamaga M, Karmaniolas K, Papadavid E, Pelecanos N, Migdalis I. Association of thyroid disease and thyroid autoimmunity with multiple myeloma risk: a case-control study. *Leuk Lymphoma*. 2008; 49: 1545-1552.
8. Tang W, Kakudo K, Nakamura MD Y, Nakamura M, Mori I, Morita S, et al. Parathyroid gland involvement by papillary carcinoma of the thyroid gland. *Arch Pathol Lab Med*. 2002; 126: 1511-1514.
9. Chrisoulidou A, Mandanas S, Mitsakis P, Iliadou PK, Manafis K, Flaris N, et al. Parathyroid involvement in thyroid cancer: an unforeseen event. *World J Surg Oncol*. 2012; 10: 121.
10. Ito Y, Kakudo K, Hirokawa M, Fukushima M, Tomoda C, Inoue H, et al. Clinical significance of extrathyroid extension to the parathyroid gland of papillary thyroid carcinoma. *Endocr J*. 2009; 56: 251-255.
11. Kakudo K, Tang W, Ito Y, Nakamura Y, Yasuoka H, Morita S, et al. Parathyroid invasion, nodal recurrence, and lung metastasis by papillary carcinoma of the thyroid. *J Clin Pathol*. 2004; 57: 245-249.