

Case Report

A Rare Sinus Histioproliferative Disorder: Rosai-Dorfman Disease, a Report of 2 Cases and Review of Literature

Subash Bhatta^{1*}, Asmita Shrestha¹ and Prashant Bhatta²

¹Department of Otorhinolaryngology and Head & Neck Surgery, Institute of Medicine, Nepal

²Department of Otorhinolaryngology and Head & Neck Surgery, College of Medical Sciences, Nepal

*Corresponding author: Subash Bhatta, Department of Otorhinolaryngology and Head & Neck Surgery, Institute of Medicine, Tribhuvan University Teaching Hospital, Kathmandu, Nepal

Received: November 30, 2020; Accepted: December 15, 2020; Published: December 22, 2020

Introduction

Rosai-Dorfman disease also known as sinus histiocytosis proliferative disorder was first described by Destombes in 1965. It was further studied and classified as a separate disease by Rosai and Dorfman in 1969 [1]. In this, non-malignant histiocytes infiltrate the lymph nodes and extra nodal tissues. It is characterized by painless lymphadenopathy mostly involving the head and neck region, however any other organ system can be involved like skin and soft tissues, central nervous system, gastrointestinal tract and salivary glands. Patient often presents with fever, malaise, lethargy and painless swelling in various region, involving both lymphatic and non-lymphatic parts. It is diagnosed by histopathology, which shows typical findings of enlarged lymph node sinuses with abundance of lymphocytes and multinucleated giant cells showing emperipoiesis with absence of birbeck granules. There is supporting evidence from raised ESR, neutrophilia and occasionally normochromic normocytic anaemia. Treatment is required only once the patient is symptomatic or has cosmetic disfigurement. Surgery is the main modality of treatment in the resectable disease. Medical therapy includes oral corticosteroids, radiotherapy and immunosuppressant.

Two Cases of Rosai-Dorfman Disease

Case 1

A female child of 8 years old presented with complaint of painless swelling in left lateral neck for 3 months, which was gradually progressive in size with mild difficulty in neck movement towards the side of the swelling. There was no history of fever, cough, dysphagia and change in voice. The history and family history were unremarkable. On examination, single, non-tender 7x6 cm diffuse swelling was present along the left lateral neck with ill-defined margin just below tragus of left pinna extending up to the anterior border of left sternocleidomastoid muscle. It was firm in consistency, mobile with free overlying skin (Figure 1).

Ultrasonography of abdomen and pelvis was normal

Her blood parameters showed TLC 12000/cu mm, N85%, L12%,

Abstract

Rosai-Dorfman disease is a rare sinus histioproliferative disorder with characteristic features of lymph node enlargement in head and neck region. We are reporting two cases of Rosai-Dorfman disease, both females one of 8 years old and another 66 years old who presented with painless neck swelling and were diagnosed by biopsy and fine needle aspiration cytology. There were no other symptoms except for neck swelling. They were treated medically with oral corticosteroids and had significant improvement.

Keywords: Rosai-dorfman; Biopsy; Corticosteroids

M2%, E1%, Hemoglobin 14.5 gm/dl, ESR 36mm/first hour and CRP was reactive. Renal function, liver function and thyroid function tests were normal. HbsAg, HCV and HIV were negative. Routine urine examination and random blood sugar were normal. Chest X-ray was normal. Rheumatoid factor, dsDNA, ANA and ANCA were negative.

For further evaluation, excisional biopsy was done under general anaesthesia, which showed histiocytic lymphadenopathy and dilated sinuses filled with histiocytes, there was presence of multinucleated giant cells with emperipoiesis and absence of birbeck granules (Figure 2). For immuno-histochemistry S 100 was done and it was positive. The diagnosis of Rosai-Dorfman disease was made from the clinical findings and histopathological features. Patient was started on 1 mg/kg oral prednisolone tapering over 1 and half months. After 1 month follow-up, the swelling had decreased in size so oral prednisolone was added for 1 more month. Then on further follow-up on third month, the swelling was not visible although it was palpable measuring 0.5x0.5cm. The patient was kept on oral steroid for total of two and half months post-operatively. Currently the patient is on regular 3 monthly follow-up.

Case 2

A 66 years old female presented with complaint of single painless swelling in left submandibular region for 4 years and



Figure 1:

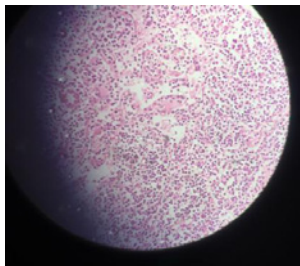


Figure 2:

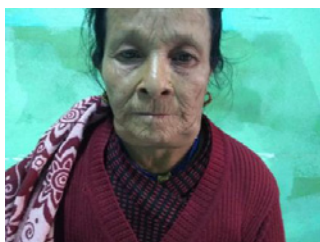

Figure 3:

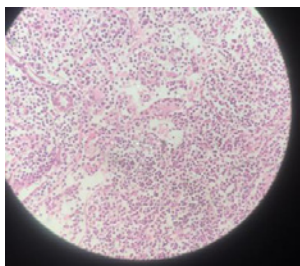


Figure 4:

similar swelling in right submandibular region for 3 years that was gradually progressive in size. There was no relation in size of swelling with food intake and there were no systemic complaints. She is hypertensive under Tablet Amlodipine 10mg once a day for 4 years. On examination, there was bilateral single swelling, non-tender with no local rise of temperature, right measuring 5x4 cm and left measuring 3x4 cm with well-defined margin, mobile and not fixed to overlying skin (Figure 3). Her blood parameters showed TLC 9000/cu mm, N62%, L31%, M4%, E2%, B1%, Hemoglobin 11.5 gm/dl, ESR 43mm/first hour and CRP was reactive. Renal function, liver function and thyroid function tests were normal. Hbs Ag, HCV and HIV tests were negative. Routine urine examination and random blood sugar were normal. ECG and chest X-ray were normal. Rheumatoid factor, dsDNA, ANA and ANCA were negative. Her ultrasonography of neck showed heteroechoic vascular, well-defined lesion in bilateral submandibular glands, right side measuring 3.6x1.8 cm and left measuring 2.5x1.6 cm. Fine needle aspiration cytology showed mixed population of lymphoid cells and proliferation of histiocytes with lymphophagocytosis. Multinucleated giant cells with emperipoiesis also noted (Figure 4). For immunohistochemistry S 100 was done and it was positive. From these findings, the diagnosis of Rosai-Dorfman disease was made. Patient was started on low dose oral steroid at 0.5mg/kg/day due to her cardiac problem tapering over one and half month. On further follow-up the swelling had gradually decreased

but not completely resolved. She took oral prednisolone for total of one and half months. Currently she is on 3 monthly follow-up.

Literature Review

We reviewed literatures on Rosai-Dorfman disease. It is sinus histiocytosis with massive lymphadenopathy involving class II histiocytes. It is a non langerhan cell histiocytosis, named after two pathologists Ronal F Dorfman and Juan Rosai [2]. Some studies have shown it to be the result of local inflammation in the lymph node region causing the migration of histiocytes [3], old French literature considers it to be a lipid storage disorder [4], other studies have shown that the congenital disorder of the lymph node to be responsible for the accumulation of histiocytes [5], many studies have also speculated viral infections as the cause of the disease likely EBV, Kliebsella, Brucella and Herpes simplex [1,6]. Levine et al in their study have shown most common viral agents to be Herpes simplex virus and Epstein bar virus [7]. There is no uniform consensus for the exact cause of this disorder. Most of the studies have also suggested it to be idiopathic [8-10]. A rare disease, Rosai-Dorfman is distributed worldwide, predominantly affecting young people with male predominance. Mean age of onset is 20.6 years with male to female ratio of 1.4:1, if there is only neurological involvement then mean age of presentation is 34.83 years [8], Dalia et al showed it to be more common in 10-20 years of age [11] and Lai et al., have showed it to be common in early adulthood [12]. It is a multisystem involving disease, with lymphatic structure predilection however there is 43% chances of involvement of nonlymphatic structures [1], while some studies showed extranodal involvement to be in one third of cases [3,13]. Main presenting complain is painless multiple cervical lymphadenopathy in 90% of cases [1]. The most frequently involved lymph nodes are cervical lymph nodes in more than 70% of cases [2,4], Lai et al showed involvement of inguinal lymph nodes in almost all of the patients in their center [12]. Most common extranodal site to be involved is central nervous system than Gastrointestinal system and cutaneous system [1,10,14]. The lesions involving the extranodal sites are slow growing and small in size than those involving nodal sites [1,3], so this may be the cause for late presentation of the cases involving extranodal regions. Fever, anaemia, leukocytosis, elevated erythrocyte sedimentation rate and polyclonal hypergammaglobulinemia are often found [1,13,15]. Hence the routine blood and urine parameters along with test such as ANA, dsDNA, TFT, LFT, RFT, RA factor, ESR and CRP has to be done. The derangement in TFT was the commonest and was observed in 18% of patients [16] RFT and LFT were also raised but exact figure couldn't be speculated. ESR and CRP were found to be raised in almost all patients [1,9,10]. Diagnosis is confirmed by fine needle aspiration cytology followed by biopsy, while biopsy being only the option in extranodal disease. Rosai-Dorfman disease cells exhibit emperipoiesis, the nondestructive phagocytosis of lymphocytes or erythrocytes, which is the hallmark of the disease and required for diagnosis [2,11,12]. Normal lymph node structure is altered by sinusoidal dilatation containing histiocytes, lymphocytes and plasma cells. In extranodal disease there is more fibrosis and less number of histiocytes [8,11]. Immunohistochemistry is very vital, especially when the histopathological report is not diagnostic, the stains are positive for CD68, CD163 and S100 and negative for CD1a [10-12]. The immunohistochemistry is very essential in differentiating for

more sinister differentials like lymphoma, metastatic lymph nodes and other systemic diseases [3]. Imaging modalities are important for the extent of disease than for diagnosis, ultrasonography is ideal for the nodal sites while computed tomography and magnetic resonance imaging has to be done for central nervous system involvement.

Rosai-Dorfman disease being a non-malignant condition, the treatment is advised only in symptomatic patients or if there is involvement of vital structures. Most of the times watchful waiting alone is the best modality of treatment with 20-30 % resolving within 6 months period [1,9]. For intracranial involvement, surgery is the best modality of choice with the aim of complete tumor removal [1,9,13]. The chance of recurrence after excision of intracranial tumor was about 10%, it was mostly due to incomplete removal [13]. Surgery also remains best modality of treatment for disease that is resectable like isolated lymph node, disease involving single salivary gland and when not attached to vital structure [1,13,17,18]. Even if the mass is attached to vital structure, there is no single report of it infiltrating the mass [9]. For the patients who do not want surgery the various modality of treatments are oral corticosteroids, radiotherapy and chemotherapy [1,13,15]. Steroids are used as the first line of therapy, as a second line of therapy after surgical excision and for the recurrent cases. The results with the use of steroids are variable, studies have shown regression of the mass in upto 40 to 60% of cases [4,13], but it was not clear whether the resolution was due to steroids or spontaneous as the natural history of the disease. Radiotherapy has shown to be effective but is not used routinely due to its side effects, 30-50 Gy of targeted radiotherapy is required [1,13]. Other systemic therapy that are tried with variable results are immunomodulators like methotrexates, 6-mercaptopurine, azathioprine and vincristine. Only few studies have reported their use and there is no evidence of their impact upon the disease. We could find one study, which has shown the good effect of dapson in the management of cutaneous disease that was refractory to oral and systemic steroids, 100mg of dapson was used daily and there was significant improvement within 3 months [7].

Discussion

Rosai-Dorfman is a rare non-malignant disorder predominantly involving lymph nodes. Although mostly idiopathic, immune mediation and the underlying infections are also associated, no direct causal relationship is found so far with any particular infection. There is variation in age of its presentation as mentioned above, most suggesting it to be occurring in early adulthood and is common in males. In our report, it is present in extreme of ages, first case 8 years old and second case 66 years old. Both patients in our report are female. Most of the patients, some study suggesting more than 90% [19], presents with bilateral multiple cervical lymphadenopathy without pain. Systemic features like malaise, fever, weight loss, loss of appetite and generalized weakness may be present. In our report, in first case there was unilateral cervical lymph node involvement with no associated systemic features whereas second case had bilateral single swelling and complained of mild lethargy and weakness. Laboratory investigations in Rosai Dorfman show presence of neutrophilia, elevated erythrocyte sedimentation rate, anaemia and hypergammaglobulinaemia [4]. In our report, ESR was raised in both the cases with 36 and 43 in first and second case respectively, CRP was positive in both cases, first case showed neutrophilia with neutrophil

count of 85%. Other blood and urine parameters were not remarkable in both the patients. Among various immunohistochemistry markers, only S-100 was done and it was positive in both the cases. It can affect any organ of the body however, the literature suggesting the exact incidence could not be found. Head and neck is the most common site of involvement and in which nasal cavity and salivary glands were most frequently involved. Both of our cases had neck involvement with no other head and neck sites involved. Since extranodal sites are also frequently involved, Ultrasonography neck, abdomen and pelvis was done for both the cases. It didn't show any other site of involvement in first case. There was enlarged inguinal lymph node in second case for which general surgery was consulted and USG guided FNAC was performed that showed similar finding as Rosai-Dorfman disease and same treatment was advised. In our cases with the typical clinical findings, histopathology showing dilated lymph node sinuses filled with histiocytes showing evidence of emperipoiesis and with exclusion of other differentials, the diagnosis of Rosai-Dorfman disease was made. No exact treatment has been advised for this disease. In about 20% of cases it is self-resolving [1], treatment is only needed when it is symptomatic. In symptomatic patients, appropriate option is surgery [1]. The prognosis of surgery is good in disease involving only central nervous system or single organ system [13]. Surgery plays a vital role if required to maintain the airway patency. Other options of treatment include systemic steroids, radiotherapy and immune suppressive drugs as mentioned previously. There are many studies showing the efficacy of steroid and some studies have shown radiotherapy to be effective. In our report, counseling was done about the natural history of disease, patients were given options of surgery or systemic therapy, both the cases agreed for systemic therapy. We started steroid at the dose of 1mg per kg for first case for two and half months and 0.5mg per kg for second case for one and half months. In second case, low dose was used as she was hypertensive under medication for 4 months. There was significant improvement in both the cases after 2 months, swelling was markedly reduced in size. At present, both the patients are in 3 monthly regular follow up.

Conclusion

Rosai-Dorfman is a benign disease with characteristic findings of histiocytosis of the lymph nodes, which requires precise and efficient approach with high degree of suspicion from both clinician and pathologists. Only the symptomatic patients require treatment however, other differentials must be ruled out.

References

1. Dalia S, Sagatys E, Sokol L, Kubal T. Rosai-Dorfman Disease: Tumor Biology, Clinical Features, Pathology, and Treatment. *Cancer Control* [Internet]. 2014; 21: 322-327.
2. Rosai J, Dorfman RF. Sinus histiocytosis with massive lymphadenopathy. A newly recognized benign clinicopathological entity. *Arch Pathol* [Internet]. 1969; 87: 63-70.
3. McPherson CM, Brown J, Kim AW, Demonte F. Regression of intracranial Rosai-Dorfman disease following corticosteroid therapy. *J Neurosurg* [Internet]. 2006; 104: 840-844.
4. Sennes L, Koishi H, Cahali R, Sperandio F, Butugan O. Rosai-Dorfman disease with extranodal manifestation in the head. *Ear Nose Throat J* [Internet]. 2004; 83: 844-847.
5. American Medical Association. College of American Pathologists. *Archives of pathology & laboratory medicine*. American Medical Association.

6. Agarwal P, Prakash P, Handa A, Gupta A. Rosai-Dorfman disease with sinonasal mucosal involvement. *JACM* [Internet]. 2012; 13: 225-228.
7. Levine PH, Jahan N, Murari P, Manak M, Jaffe ES. Detection of human herpesvirus 6 in tissues involved by sinus histiocytosis with massive lymphadenopathy (Rosai-Dorfman disease). *J Infect Dis* [Internet]. 1992; 166: 291-295.
8. Mantilla JG, Goldberg-Stein S, Wang Y. Extranodal Rosai-Dorfman Disease. *Am J Clin Pathol* [Internet]. 2016; 145: 211-221.
9. Pulsoni A, Anghel G, Falcucci P, Matera R, Pescarmona E, Ribersani M, et al. Treatment of sinus histiocytosis with massive lymphadenopathy (rosai-dorfman disease): Report of a case and literature review. *Am J Hematol* [Internet]. 2002; 69: 67-71.
10. Cai Y, Shi Z, Bai Y. Review of Rosai-Dorfman Disease: New Insights into the Pathogenesis of This Rare Disorder. *Acta Haematol* [Internet]. 2017; 138: 14-23.
11. Dalia S, Sagatys E, Sokol L, Kubal T. Rosai-Dorfman Disease: Tumor Biology, Clinical Features, Pathology, and Treatment. *Cancer Control* [Internet]. 2014; 21: 322-327.
12. Lai KL, Abdullah V, Ng KS, Fung NS, van Hasselt CA. Rosai-dorfman disease: Presentation, diagnosis, and treatment. Andersen P, editor. *Head Neck* [Internet]. 2013; 35: E85-E88.
13. Adeleye AO, Amir G, Fraifeld S, Shoshan Y, Umansky F, Spektor S. Diagnosis and management of Rosai-Dorfman disease involving the central nervous system. *Neurol Res* [Internet]. 2010; 32: 572-578.
14. Kumar R, Garg K, Dash C, Sharma MC. Rosai-Dorfman disease: An unusual isolated cavernous sinus lesion. *Neurol India* [Internet]. 2016; 64: 1331-1332.
15. Rosai J, Dorfman RF. Sinus histiocytosis with massive lymphadenopathy: a pseudolymphomatous benign disorder. Analysis of 34 cases. *Cancer* [Internet]. 1972; 30: 1174-1188.
16. Wenig BM, Abbondanzo SL, Childers EL, Kapadia SB, Heffner DR. Extranodal sinus histiocytosis with massive lymphadenopathy (Rosai-Dorfman disease) of the head and neck. *Hum Pathol* [Internet]. 1993; 24: 483-492.
17. American Medical Association, College of American Pathologists. *Archives of pathology & laboratory medicine*. American Medical Association.
18. Wimmer DB, Ro JY, Lewis A, Schwartz MR, Caplan R, Schwarz P, et al. Extranodal Rosai-Dorfman Disease Associated With Increased Numbers of Immunoglobulin G4 Plasma Cells Involving the Colon: Case Report With Literature Review. *Arch Pathol Lab Med* [Internet]. 2013; 137: 999-1004.
19. Jani PA, Banjan D. A case of sinus histiocytosis with massive lymphadenopathy (Rosai-Dorfman syndrome) from western India. *Mcgill J Med* [Internet]. 2008; 11: 156-159.