

Research Article

Capsular Interposition Arthroplasty for End-Stage Hallux Rigidus: Short-Term Results

Kanazawa K*, Yoshimura I, Hagio T, Minokawa S and Yamamoto T

Department of Orthopaedic Surgery, Fukuoka University School of Medicine, Japan

*Corresponding author: Kanazawa K, Department of Orthopaedic Surgery, Fukuoka University School of Medicine, 7-45-1 Nanakuma, Jonan-ku, Fukuoka, 814-0180, Japan

Received: May 02, 2018; Accepted: May 31, 2018;

Published: June 11, 2018

Abstract

Background: Hallux rigidus is a common consequence of degenerative arthritis of the first Metatarsophalangeal (MTP) joint. Capsular Interposition Arthroplasty (CIA) is a motion-sparing procedure that has been shown to be effective as an alternative to fusion in end-stage hallux rigidus.

Objective: The study aimed to assess the results of CIA in patients with hallux rigidus.

Methods: Ten patients (10 feet) with Grade III hallux rigidus (per the Hattrup classification) underwent CIA of the first MTP joint in our institution. The mean age was 67.1 years and mean duration of follow-up was 16.8 months (range, 12-23). Preoperative and postoperative Ranges of Motion (ROMs) of the hallux MTP joint were measured and compared. Clinical evaluations involved the 5 subscales of the Self-Administered Foot Evaluation Questionnaire (SAFE-Q) and the Japan Society for Surgery of the Foot (JSSF) score.

Results: The mean ROM for extension improved from 6.5° to 31.0°, and mean ROM for flexion improved from 11.5° to 26.0°. The mean SAFE-Q scale scores significantly improved in all patients after surgery. The mean JSSF score significantly improved from a preoperative 49.9 points to a postoperative 82.5 points. The overall complication rate was 10% (1/10), and involved the breakage of a K-wire in 1 foot.

Conclusion: CIA is an acceptable choice for patients with grade III hallux rigidus who desire preservation of articular function.

Keywords: Hallux rigidus; Degenerative arthritis; First metatarsophalangeal joint; Operative technique; Motion-sparing procedures; Capsular interposition arthroplasty

Abbreviations

Capsular Interposition Arthroplasty (CIA); Japan Society for Surgery of the Foot (JSSF); Metatarsophalangeal (MTP); Range/S of Motion (ROM/s); Self-Administered Foot Evaluation Questionnaire (SAFE-Q)

Introduction

Hallux rigidus is a degenerative arthritis of the first Metatarsophalangeal (MTP) joint that results in a limited range of motion due to osteophyte formation and joint space narrowing [1-3]. This disease was initially described by Davies-Colley in 1887 as hallux flexus [4]. Conservative treatment may include use of insoles and nonsteroidal anti-inflammatory drugs in the early stages. If nonoperative treatment fails, surgery may be considered. Various surgeries have been prescribed for hallux rigidus, including cheilectomy, proximal phalangeal osteotomy, metatarsal osteotomy, Capsular Interposition Arthroplasty (CIA), MTP fusion (arthrodesis), hemiarthroplasty, and total joint replacement (implant arthroplasty) [1]. Cheilectomy, proximal phalangeal osteotomy, and metatarsal osteotomy are applied in the early disease stage. However, CIA, arthrodesis, and implant arthroplasty are applied in the end stage, but no surgical procedures are established in this stage. CIA is a low-cost

and motion-sparing procedure that uses autologous tissue [5-7], all of which are the reasons why CIA is the first-line surgery for end-stage hallux rigidus in our institution. The purpose of this study was to present our institution's experience and the short-term clinical results of CIA for end-stage hallux rigidus.

Materials and Methods

This was a retrospective and descriptive study of 10 patients (10 feet) with end-stage osteoarthritis of the MTP joint (Hattrup Grade III, hallux rigidus per the Hattrup classification [2]) treated by CIA from November 2010 to November 2015 in our institution. The study cohort was comprised of 10 patients (10 feet), including 8 women and 2 men. Mean age at surgery was 67.1 years (range, 51-80 years) and mean duration of follow-up was 16.8 months (range, 12-23 months). Clinical and radiographic studies were performed at the initial examination and at every outpatient visit until final follow-up. All charts were reviewed to collect the preoperative and postoperative (final follow-up) Range of Motion (ROM) measurements of the hallux MTP joint and the Japan Society for Surgery of the Foot (JSSF) scores [8]. The JSSF is a 100-point clinical score comprising three items: a pain score (40 points maximum), functionality (45 points maximum), and alignment (15 points maximum). Data was also available for the Self-Administered Foot Evaluation

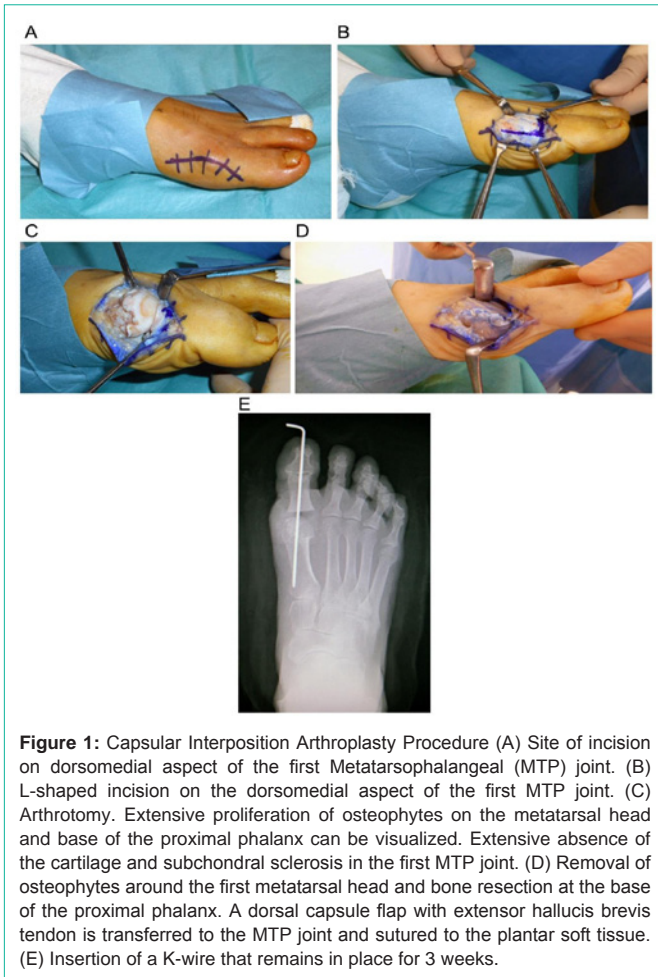


Figure 1: Capsular Interposition Arthroplasty Procedure (A) Site of incision on dorsomedial aspect of the first Metatarsophalangeal (MTP) joint. (B) L-shaped incision on the dorsomedial aspect of the first MTP joint. (C) Arthrotomy. Extensive proliferation of osteophytes on the metatarsal head and base of the proximal phalanx can be visualized. Extensive absence of the cartilage and subchondral sclerosis in the first MTP joint. (D) Removal of osteophytes around the first metatarsal head and bone resection at the base of the proximal phalanx. A dorsal capsule flap with extensor hallucis brevis tendon is transferred to the MTP joint and sutured to the plantar soft tissue. (E) Insertion of a K-wire that remains in place for 3 weeks.

Questionnaire (SAFE-Q) scores [9,10], which use 5 subscales: 1: Pain and Pain-Related, 2: Physical Functioning and Daily Living, 3: Social Functioning, 4: Shoe-Related, and 5: General Health and Well Being. The subscales were scored between zero to 100. This questionnaire is at the time of the final postoperative visit. Statistical analysis was performed using SPSS software (IBM, Chicago, USA). Preoperative and final follow-up clinical data (ROM measurements, JSSF score and SAFE-Q scores) were compared using a paired t-test. A P Value of <0.05 was considered statistically significant.

Operative Technique

Surgery was performed with all patients in a supine position, under epidural anesthesia, using both intravenous sedation and a pneumatic ankle tourniquet with the pressure set at 250 mmHg. A curved incision was made from the dorsomedial aspect of the first MTP joint, taking care to protect the dorsomedial sensory nerve and extensor hallucis longus tendon.

The technique was performed as described by Hamilton et al. [5] and Mroczek and Miller [6]. The extensor hallucis brevis tendon was released from the dorsal joint capsule and then the extensor hallucis brevis tendon was transected approximately 3cm proximal to the joint. The joint capsule was incised in an L-shape on the dorsomedial aspect of the first MTP joint. Osteophytes on the metatarsal head and the base of the proximal phalanx were resected as completely

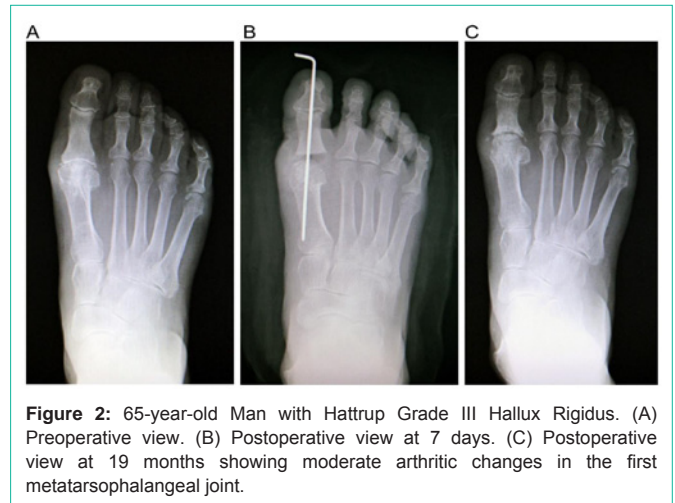


Figure 2: 65-year-old Man with Hatrup Grade III Hallux Rigidus. (A) Preoperative view. (B) Postoperative view at 7 days. (C) Postoperative view at 19 months showing moderate arthritic changes in the first metatarsophalangeal joint.

as possible, particularly on the plantar side. An osteotomy was then performed, including resection of 30% of the dorsal metatarsal head and 3mm of the base of the proximal phalanx in a dorsal-based wedge shape. The dorsal capsule with the extensor hallucis brevis was then transferred to the MTP joint. A 3-0 absorbable suture was then used to anchor the plantar soft tissue and a 2.0mm K-wire placed to achieve transarticular fixation (interphalangeal and MTP joint) for 3 weeks (Figure 1).

Postoperative Management

A short leg splint was applied postoperatively and worn for 3 weeks. Weight-bearing was permitted on the first postoperative day on the hindfoot. The K-wire was removed 3 weeks postoperatively after which patients were allowed to wear normal shoes.

Results and Discussion

We observed significant improvement in all SAFE-Q subscale scores, JSSF scores, and ROM measurements. The mean ROM for extension improved from 6.5° to 31.0°, and the mean ROM for flexion improved from 11.5° to 26.0°. The mean SAFE-Q scale scores significantly improved in all patients after surgery. The mean JSSF score significantly improved from preoperative 49.9 points to postoperative 82.5 points (Tables 1-3). No participants developed metatarsalgia. The overall complication rate was 10% (1/10), one patient had K-wire breakage in one foot.

A large variety of surgical procedures have been described for surgical treatment of hallux rigidus according to the degree of deformity [1-3,5,6,11-17]. Surgical procedures for hallux rigidus have been classified as motion-sparing and motion-sacrificing [5,6]. Motion-sparing procedures include first metatarsal osteotomy (Green-Waterman osteotomy) [12], cheilectomy, proximal phalangeal osteotomy (Moberg osteotomy) [11], and CIA [5-7], whereas motion-sacrificing procedures include total joint replacement and arthrodesis.

CIA, arthrodesis and implant arthroplasty are currently indicated for advanced stages of hallux rigidus. Arthrodesis is still regarded as the most appropriate surgical procedure in patients with advanced hallux rigidus disease (grade III per the Hatrup classification) [3]. Its disadvantages include long recovery time, loss of ROM, non-union,

Table 1: Mean (\pm standard deviation) pre- and post-operative outcomes scores of the on SAFE-Q Subscales.

Subscale	Preoperative	Postoperative	P value*
Pain and Pain-Related	36.3 \pm 7.8	82.7 \pm 5.3	0.001
Physical Functioning and Daily Living	46.1 \pm 9.3	86.82 \pm 5.5	0.002
Social Functioning	16.3 \pm 11.0	95.4 \pm 9.7	0.001
Shoe-Related	25.8 \pm 9.2	90.0 \pm 7.7	0.002
General Health and Well-Being	47.5 \pm 11.8	96.5 \pm 6.7	0.001

*P value <0.05 was considered statistically significant.

Table 2: Mean (\pm standard deviation) pre- and post-operative range of motion measurements (in degrees).

	Preoperative	Postoperative	P value
Extension	6.5 \pm 2.1	31.0 \pm 8.3	0.001
Flexion	11.5 \pm 5.1	26.0 \pm 6.7	0.002

P value <0.05 was considered statistically significant.

Table 3: Mean (\pm standard deviation) pre- and post-operative outcomes Japan Society for Surgery of the Foot (JSSF) scores.

	Preoperative	Postoperative	P value*
JSSF scale	49.9 \pm 5.4	82.5 \pm 7.8	0.003

*P value <0.05 was considered statistically significant.

shoe wearing limitations, and interphalangeal joint degenerative osteoarthritis [3,13,17]. Implant arthroplasty preserves joint mobility; however, these disadvantages indicate the risk of implant failure and high costs [7,18,20]. CIA reportedly achieves excellent results [5,6,13-15]. In addition, CIA is a low-cost procedure using autologous tissue and does not have risks such as loss of ROM, non-union, and shoe wearing limitations [5-7]. These are the reasons why CIA is the first-line surgery for end-stage hallux rigidus in our institution. However, complications include shortening of the hallux, resulting in lateral transfer metatarsalgia, as has been reported in previous studies [13-15]. In our study, only one patient had a complication (10%), that is, K-wire breakage. The complication occurred after 1 week postoperatively. The patient was non-compliant and started full weight bearing from postoperative day 4 without permission. No participants developed metatarsalgia. These data suggest that to prevent excessive shortening, the minimum requirement is first proximal phalanx osteotomy.

In this study, one patient had MTP joint space narrowing and degenerative changes were observed at the final follow-up (Figure 2). Interpositioning the dorsal capsule with the extensor hallucis brevis does not provide the joint with sufficient cushioning for motion Akiyama et. al. [19] reported two cases involving one patient where there was narrowing of the joint space within 12 months after CIA. However, the authors described a good clinical outcome 4 years after surgery. We presume that the autologous tissue interposition was worn away by the motion of the MTP joint. However, although short-term results are satisfactory, the improvement of the new procedure appears necessary to provide a long-term cushion for the joint Berlet et.al. [17] used allogenic biological materials to perform soft tissue interposition arthroplasty and reported excellent short-term results Aynardi et.al. [16] reported formation of a fibrocartilage cap over the first metatarsal head after CIA with such allografts. Using allografts may be advantageous in some patients with osteoarthritis. However,

it does increase the cost. Overall, autologous tissue interposition is a low-cost procedure, has low failure and complication rates, and has promising results for improvement of ROM, pain relief, and activities of daily living [6,7,13,15].

This study has some limitations. This is a retrospective study with a small number of cases (10 feet) and a short postoperative follow-up period (16.8 months).

Conclusion

We demonstrated that CIA is an effective surgical treatment for end-stage hallux rigidus with improvement in ROM of the hallux MTP joint and improvement in symptoms (pain and activities of daily living) at a mean follow-up of 16.8 months.

Declaration

Ethics approval and consent to participate

Ethical approval was not necessary, per Fukuoka University - Medical Ethics Review Board, for this type of follow up study due to chart review.

Human and animal rights

The study was performed in accordance with the Declaration of Helsinki.” as your study does involve data collected from human participants.

Consent for publication

Written consent was obtained by all participants for prospective data collection, follow up exams and publication of the clinical results and images in international journals.

Acknowledgement

We would like to thank Editage (www.editage.jp) for English language editing.

References

- Simpson GA, Hembree WC, Miller SD, Hyer CF, Berlet GC. Surgical strategies: hallux rigidus Surgical Techniques. *Foot Ankle Int.* 2011; 32: 1175-1186.
- Hattrup SJ, Johnson KA. Subjective result of hallux rigidus following treatment with cheilectomy. *Clin Orthop Relat Res.* 1988; 226: 182-191.
- Coughlin MJ, Shumas PS. Hallux rigidus. Grading and long-term results of operative treatment. *J Bone Joint Surg Am.* 2003; 85: 2072-2088.
- Colley ND. Contraction of the metatarsophalangeal joint of the great toe. *Br Med J.* 1887; 1: 728.
- Hamilton WG, O'Malley MJ, Thompson FM, Kovatis PE. Roger Mann Award 1995. Capsular interposition arthroplasty for severe hallux rigidus. *Foot Ankle Int.* 1997; 18: 68-70.
- Mroczek KJ, Miller SD. The modified oblique Keller procedure: a technique for dorsal approach interposition arthroplasty sparing the flexor tendons. *Foot Ankle Int.* 2003; 24: 521-522.
- Ozan F, Bora OA, Filiz MA, Kement Z. Interposition arthroplasty in the treatment of hallux rigidus. *Acta Orthop Traumatol Turc.* 2010; 44: 143-151.
- Niki H, Aoki H, Inokuchi S, Ozeki S, Kinoshita M, Kura H, et al. Development and reliability of a standard rating system for outcome measurement of foot and ankle disorders I: development of standard rating system. *J Orthop Sci.* 2005; 10: 457-465.
- Niki H, Tatsunami S, Haraguchi N, Aoki T, Okuda R, Suda Y, et al. Validity and reliability of a Self-Administered Foot Evaluation Questionnaire (SAFE-Q). *J*

- Orthop Sci. 2013; 18:298-320.
10. Niki H, Haraguchi N, Aoki T, Ikezawa H, Ouchi K, Okuda R, et al. Responsiveness of the Self-Administered Foot Evaluation Questionnaire (SAFE-Q) in patients with hallux valgus. *J Orthop Sci.* 2017; 22: 737-742.
 11. Moberg E. A simple operation for hallux rigidus. *Clin Orthop Relat Res.* 1979; 142: 55-56.
 12. Dickerson JB, Green R, Green DR. Long-term Follow-up of the Green-Watermann osteotomy for hallux limitus. *J Am Podiatr Med Assoc.* 2002; 92: 543-544.
 13. Mackey RB, Thomson AB, Kwon O, Mueller MJ, Johnson JE. The modified oblique keller capsular interpositional arthroplasty for hallux rigidus. *J Bone Joint Surg Am.* 2010; 92: 1938-1946.
 14. Roukis TS. Outcome Following autogenous soft tissue interpositional arthroplasty for end-stage hallux rigidus: a systematic review. *J Foot Ankle Surg.* 2010; 49: 475-478.
 15. Vulcano E, Chang AL, Solomon D, Myerson M. Long-Term Follow-Up of Capsular Interposition Arthroplasty for Hallux Rigidus. *Foot Ankle Int.* 2018; 39: 1-5.
 16. Aynardi MC, Atwater L, Dein EJ, Zahoor T, Schon LC, Miller SD. Outcomes after Interpositional Arthroplasty of the First Metatarsophalangeal Joint. *Foot Ankle Int.* 2017; 38: 514-518.
 17. Berlet GC, Hyer CF, Lee TH, Philbin TM, Hartman JF, Wright ML. Interpositional arthroplasty of the first MTP joint using a regenerative tissue matrix for the treatment of advanced hallux rigidus. *Foot Ankle Int.* 2008; 29: 10-21.
 18. Aslan H, Citak M, Bas EG, Duman E, Aydin E, Ates Y. Early results of HmeiCAP resurfacing implant. *Acta Orthop Traumatol Turc.* 2012; 46: 17-21.
 19. Akiyama Y, Niki H, Hirano T, Mitsui H, Endo W, Maeda S, et al. Clinical results of capsular interposition arthroplasty for severe hallux rigidus. *J Jpn Soc Surg Foot.* 2015; 36: 126-129.
 20. Erkokcak OF, Senaran H, Altan E, Aydin BK, Acar MA. Short-term functional outcomes of first metatarsophalangeal total joint replacement for hallux rigidus. *Foot Ankle Int.* 2013; 34: 1569-1579.