

## Case Report

## Suicidal Ingestion of a Caustic Substance: A Case Report

Focardi M<sup>1\*</sup>, Grifoni R<sup>1</sup>, Pinchi V<sup>1</sup>, Pieri L<sup>1</sup>, Bonari A<sup>2</sup>, Pompilio I<sup>2</sup>, Arcangeli G<sup>2</sup>, Castiglione F<sup>3</sup> and Norelli GA<sup>1</sup>

<sup>1</sup>Department of Health Sciences, Forensic Medicine Section, Forensic Medicine Section, University of Florence, Italy

<sup>2</sup>Department of Clinical and Experimental Medicine, Health Services Research Section, Laboratory of Hygiene and Industrial Toxicology, Italy

<sup>3</sup>Department of Biomedicine, Careggi Hospital, University of Florence, Italy

\*Corresponding author: Focardi M, Department of Health Sciences, Forensic Medicine Section, University of Florence, 50134 Florence, Italy, Tel. + 39-055-2751770; E-mail: martinafocardi@gmail.com

Received: May 06, 2015; Accepted: June 15, 2015;

Published: June 19, 2015

## Abstract

In infants and children accidental ingestion of caustic substances can occur, in adults otherwise chemical exposure may be related to suicidal behaviors. Acid or alkali agents can cause chemical burns from mild to extensive injuries in digestive tract mucosa. Sometimes death due to an organ perforation occurs. The authors present a case of a 48-year-old man, found dead in his apartment, wearing only pants and socks. Near the body no objects or substances. A caustic substance was then found inside his car. Autopsy and chemical investigations were performed. The external examination of the body showed no traumatic injuries, except for some burn perioral lesions. At the autopsy, were found esophageal brownish mucosa, necrosis of the stomach, thrombosis of the gastric vessels and dark peritoneal fluid coating the bowels. Histological analyses of gastric mucosa showed cells with intensely eosinophilic cytoplasm and with condensation and fragmentation of nuclei and their progressive loss. Chemical investigations were made but did not provide useful information. Considering the circumstantial data and the autopsy findings, death was attributed to caustic ingestion. Severity of caustic exposure depends on the type of the substances but alkali may play a direct role in the lethal process by digestive burns, producing liquefaction necrosis.

**Keywords:** Caustic ingestion; Suicidal; Chemical injuries

## Introduction

Substances with a pH of less than 2 (strong acids) or higher than 12 (strong alkalis) are corrosives. Caustic ingestion represents a health public problem worldwide, despite the efforts and the educational campaigns to reduce its occurrence. Ingestion is the most frequent route of exposure [1]. Accidental ingestion occurs in infants and children of less of six years old, especially between 1 and 4. Otherwise in adolescents and adults may be related to suicidal behaviors [2-4]. In the United States an incidence of 5000 to 15000 cases per year is estimated [5-7]. The type of corrosive agents varies country to country. Reports from Denmark, Israel, UK, Spain, and Australia showed that alkaline agents are most commonly used [8]; in developing countries the majority of caustic ingestion is due to acids [9]. Caustic ingestion induces a local toxicity leading to damage for the upper gastrointestinal system, ranging from mild to extensive injuries [10]. Corrosive substances may cause massive hemorrhage and acutely gastrointestinal tract perforation or lead to aortoenteric, gastrocolic or gastrobronchial fistulas in the longer term. The latter may occur 2 to 10 weeks after ingestion [11-12]. Long-term complications include an increased risk of esophageal carcinoma and esophageal and/or gastric stenosis. The mortality rate after caustic ingestion has been reported between 7 and 14% [13].

Severe caustic exposure can lead to an organ perforation or directly to death [14]. Patients may present a combination of various symptoms or none at all depending on the pH of the agent, its concentration, physical properties, contact time, route of exposure and tissues involved [15]. Voluntary ingestion usually causes more extensive burns due to the high quantity taken.

## Case Presentation

The Authors present a case of a 48-year-old married man, found

dead in his parents' apartment. The corpse was slumped on the kitchen floor, in a crouched position, near to the boiler, wearing only pants and socks. The man was suffering from depression because of work and his physical condition (loss of short term memory after viral encephalitis) and had already announced several times his intention to commit suicide. The last time he was seen by his wife was in the morning of the day before. During the first inspection of the site, no objects or substances were found in the apartment. About two days later, caustic substances were then noticed inside his car: they were contained in some jars that resulted half empty. The substance was constituted by sodium hydroxide and potassium hydroxide. The autopsy was ordered.

## Materials and Methods

A complete autopsy was performed including external, internal, histochemical and toxicological investigations. Histological samples

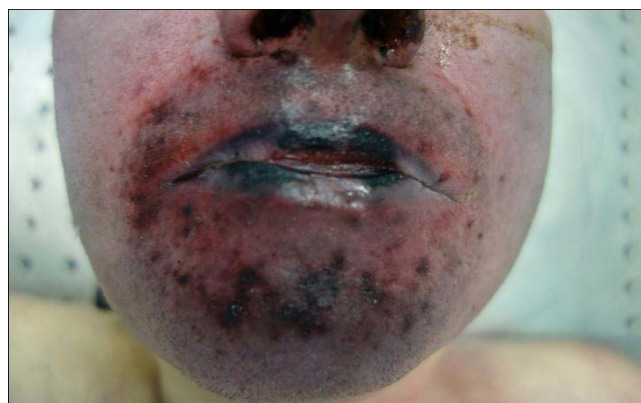
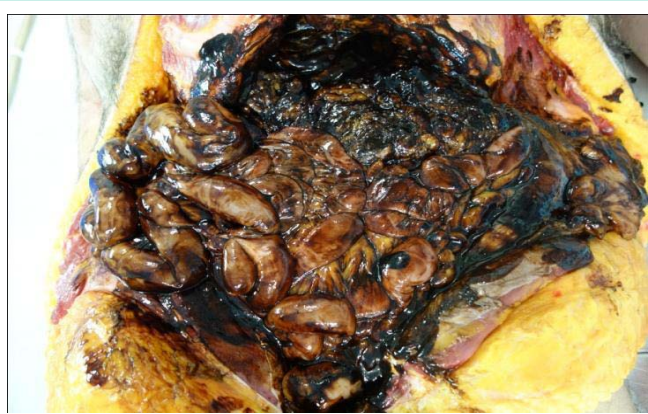
Figure 1: Blackish burn perioral lesions.



**Figure 2:** Dark peritoneal fluid coating the bowels.

were fixed with 10% formaldehyde for more than 1 week and embedded in paraffin; the blocks were sectioned to 4-5 micron thickness and analyzed by hematoxylin-eosin stain. Chemical analyses were performed to detect the concentration of sodium and potassium on samples of ascites fluid collected from the abdominal cavity, stored frozen at  $-20^{\circ}\text{C}$  until time of testing. After thawing and centrifugation at  $1300 \times g$  for 10 min at room temperature, the supernatant of each sample was analyzed with a V-Lyte Integrated Multisensor<sup>®</sup> electrolyte detector on Dimension Vista1500<sup>®</sup> System (Siemens Healthcare Diagnostics, Germany) (Sample Control: Liquid Assayed Multiquel<sup>®</sup> Level 1,2, Biorad Laboratories Ltd, USA).

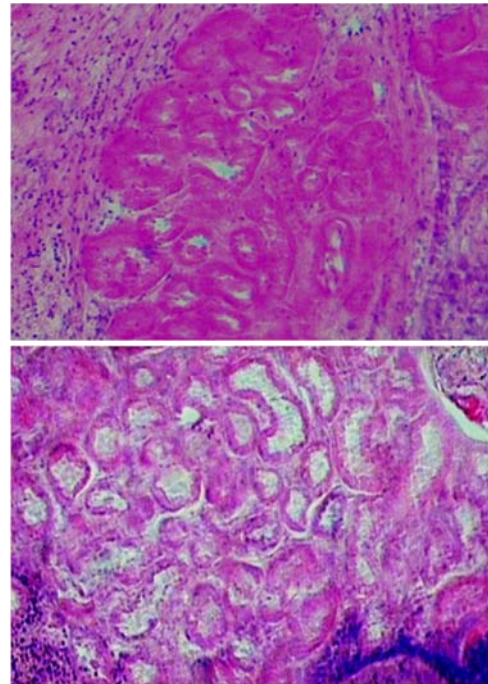
## Results

At the external examination, no traumatic injuries were found, except for some blackish burn perioral lesions especially on the chin (Figure 1), blackish liquid coming out from oral cavity and an excoriation on the back due to the contact with the radiator in the kitchen as he fell on the floor.

At the autopsy, the esophagus had blackish mucosa with no macroscopic areas of necrosis in its proximal tract. The larynx demonstrated no injuries except for a dark aspect of the epiglottis. The trachea was undamaged. Both lungs displayed congestion and upon squeezing them, a mix of blood and foam was found. Opening the abdomen, 800 cc of dark peritoneal fluid coating the bowels was found (Figure 2). Small intestine was agglomerated and the duodenum showed black hemorrhagic mucosal spots. Esophageal mucosa was brownish and the stomach walls were extensively perforated, with necrosis and severe burn lesions. Gastric vessels showed evidence of local diffuse thrombosis. There were signs of diffuse congestion of the organs and cerebral edema.

Toxicological analyses revealed  $\text{Na}^+$  179 mmol/L (int. ref. on serum 136.0 – 145.0 mmol/L) and  $\text{K}^+$  30.3 mEq/L (int. ref. on serum 3.5 – 5.1 mmol/L).

Haematoxylin and eosin staining sections showed congestion, cerebral edema, pulmonary atelectasis, focal and superficial liquefactive necrosis of the esophageal and gastric mucosa, caused by lytic processes made by protease richness of tissues. In addition gastric mucosa showed cells with progressive loss of nuclei and with cytoplasmic eosinophilia weakly evident (Figure 3-4).



**Figure 3-4:** Cells of gastric mucosa show progressive loss of nuclei and a cytoplasm extremely eosinophilic: liquefactive necrosis.

## Discussion

Alkalis contain bases dissolved in water. Lye is a general term for alkali found in cleaning products. Alkaline materials have a great degree of penetration and combine with tissue proteins to form proteinates, and with fats to form soap in addition to water, allowing the caustic substance to reach deeper tissue layers. Typically the esophagus is the first to be damaged [16]; the stomach is often intact in 80% of cases [17]. However, alkali damage of the stomach has also been reported. The conventional acceptance that acids affect stomach mucosa more commonly than alkalis, due to the protective esophageal eschar, has recently been questioned. Extensive esophageal damage and perforations after acid ingestion have been observed. Compared with alkalis, ingestion of a strong acid determines a higher incidence of systemic complications [18].

The microscopic examination after acid ingestion showed detachment of the esophageal epithelium, superficial and focal necrosis of the mucosa [19]. Lye usually causes liquefactive necrosis, which can determine a complete destruction of the upper gastrointestinal tract and damage adjacent organs [20]. It is possible that some of the findings at autopsy represent postmortem changes due to prolonged exposure to caustic agents waiting autopsy examination [21].

However the higher concentration of the product, the greater its ability to provoke severe injury; the effect of the time of contact of the caustic substance with tissue is similar to the effect of its concentration [22].

In this case, the features and the site of the lesions, as well as the find of a caustic substance in the car of the victim, increase the suspicion of ingestion of strong basic substances. That's the reason

why chemical examinations were performed on the endoperitoneal liquid. The Author detected the sodium and potassium concentration but not hydroxide because it can't be evaluated being a volatile substance.

Even if the concentration values of Potassium and Sodium are respectively about 5 and 1.2 times greater than normal serum values, these results are not diagnostic because they could be due to storage condition (two months at  $-20^{\circ}\text{C}$ ) and in vitro hemolysis, so chemical analysis did not provide useful information about the mechanism of death [23-24].

Considering the rarity of local spontaneous thrombosis of gastric vessels, the type of traumatic lesions found at the autopsy and the histological results, the cause of death, due to cardio-respiratory failure resulting from massive gastric necrosis with endoperitoneal blackish liquid ascites and thrombosis of gastric vessels, was most likely secondary to the ingestion of strong alkaline substance, in hypothesis also compatible, by nature, with those found in the boot of the car of man.

## Conclusions

Chemical injuries due to caustic exposure are an uncommon cause of death. Having great potential for tissue destruction, alkali may play a direct role in the lethal process by digestive burns, producing liquefaction necrosis. A link between the autopsy findings and the circumstances allows the Authors to conclude the death was connected to suicide by caustic ingestion.

## References

- Bronstein AC, Spyker DA, Cantilena LR Jr, Green JL, Rumack BH, Dart RC. 2010 Annual Report of the American Association of Poison Control Centers' National Poison Data System (NPDS): 28th Annual Report. *Clin Toxicol (Phila)*. 2011; 49: 910-941.
- Christesen HB. Epidemiology and prevention of caustic ingestion in children. *Acta Paediatr*. 1994; 83: 212-215.
- Poddar U, Thapa BR. Benign esophageal strictures in infants and children: results of Savary-Gilliard bougie dilation in 107 Indian children. *Gastrointest Endosc*. 2001; 54: 480-484.
- Vijayanath V, Nagaraja Rao K, Raju GM, Anitha MR. Forensic issues in suicide due to acid ingestion in a case of major depressive disorder. *Am J Forensic Med Pathol*. 2012; 33: 156-158.
- Schaffer SB, Hebert AF. Caustic ingestion. *J La State Med Soc*. 2000; 152: 590-596.
- Arévalo-Silva C, Eliashar R, Wohlgelernter J, Elidan J, Gross M. Ingestion of caustic substances: a 15-year experience. *Laryngoscope*. 2006; 116: 1422-1426.
- Lupa M, Magne J, Guarisco JL, Amedee R. Update on the diagnosis and treatment of caustic ingestion. *Ochsner J*. 2009; 9: 54-59.
- Lakshmi CP, Vijayahari R, Kate V, Ananthakrishnan N. A hospital-based epidemiological study of corrosive alimentary injuries with particular reference to the Indian experience. *The National Medical Journal of India*. 2013; 26: 131-136.
- Ramasamy K, Gumaste VV. Corrosive ingestion in adults. *J Clin Gastroenterol*. 2003; 37: 119-124.
- Mamede RC, de Mello Filho FV. Ingestion of caustic substances and its complications. *Sao Paulo Med J*. 2001; 119: 10-15.
- Byard RW. Lethal aorto-oesophageal fistula - characteristic features and aetiology. *J Forensic Leg Med*. 2013; 20: 164-168.
- Byard RW. Caustic ingestion-a forensic overview. *J Forensic Sci*. 2015; 60: 812-815.
- Cabral C, Chirica M, de Chaisemartin C, Gornet JM, Munoz-Bongrand N, Halimi B, et al. Caustic injuries of the upper digestive tract: a population observational study. *Surg Endosc*. 2012; 26: 214-221.
- Poley JW, Steyerberg EW, Kuipers EJ, Dees J, Hartmans R, Tilanus HW, et al. Ingestion of acid and alkaline agents: outcome and prognostic value of early upper endoscopy. *Gastrointest Endosc*. 2004; 60: 372-377.
- Osman M, Russell J, Shukla D, Moghadamfalahi M, Granger DN. Responses of the murine esophageal microcirculation to acute exposure to alkali, acid, or hypochlorite. *J Pediatr Surg*. 2008; 43: 1672-1678.
- Pavelites JJ, Kemp WL, Barnard JJ, Prahlow JA. Deaths related to chemical burns. *Am J Forensic Med Pathol*. 2011; 32: 387-392.
- Moore WR. Caustic ingestions. Pathophysiology, diagnosis, and treatment. *Clin Pediatr (Phila)*. 1986; 25: 192-196.
- Contini S, Scarpignato C. Caustic injury of the upper gastrointestinal tract: a comprehensive review. *World J Gastroenterol*. 2013; 19: 3918-3930.
- Advenier AS, Dorandeu A, Charlier P, Lorin de la Grandmaison G. Microscopic acute lesions after caustic exposure. *Forensic Sci Int*. 2014; 234: 57-63.
- Oakes DD. Reconsidering the diagnosis and treatment of patients following ingestion of liquid lye. *J Clin Gastroenterol*. 1995; 21: 85-86.
- Matshes EW, Taylor KA, Rao VJ. Sulfuric acid injury. *Am J Forensic Med Pathol*. 2008; 29: 340-345.
- Mattos GM, Lopes DD, Mamede RC, Ricz H, Mello-Filho FV, Neto JB. Effects of time of contact and concentration of caustic agent on generation of injuries. *Laryngoscope*. 2006; 116: 456-460.
- Frank JJ, Bermes EW, Bickel MJ, Watkins BF. Effect of in vitro haemolysis on chemical values for serum. *Clin Chem*. 1978; 11: 1966-1970.
- Dimeski G, Clague AE, Hickman PE. Correction and reporting of potassium results in haemolysed samples. *Ann Clin Biochem*. 2005; 42: 119-123.