

Special Article - Forensic Anthropology

# Scrutiny of Four Conventional Visual Traits of Mandible for Sex Estimation in Indian Population

Vineeta Saini\*

Department of Forensic Medicine, Institute of Medical Sciences, India

\*Corresponding author: Vineeta Saini, Saini Sadan, Shri Hariom Shakti Ashram, Sector 12A, Gurgaon, Haryana, India

Received: July 05, 2017; Accepted: July 31, 2017;

Published: August 29, 2017

## Abstract

Population variability in the magnitude of the expression of sexual dimorphism of various skeletal parts has been acknowledged by several anthropologists. Several morphological traits are in use for a long period for sex determination from mandible. In spite of quick and easy, these methods have been constantly criticized for the high rate of inter and intra observer error in sex classification. The present study investigates whether the traditional visual parameters of human mandible are sexually dimorphic in North Indian population or it is just an old wife's tale. A total of 189 adult mandibles (143 male and 46 females) of North Indian origin with age range 18 to 70 years collected from the Department of Forensic Medicine, IMS, BHU, and Varanasi. All pathological, fractured, deformed, or edentulous mandibles were excluded from the study. Four traditional morphological parameters of mandible (chin shape, gonial flaring, contour of lower border and muscular attachments) were carefully observed for sex discrimination. An inter and intra observer error test using Kohen's Kappa was also calculated. It was observed that the contour of lower border and muscular attachments provided the lowest (62.96%) and the highest (83.59%) sexing accuracy respectively. It is also noted that the lowest and highest inter and intra-observer errors showed by contour of lower border and muscular attachments respectively. The gonial flaring provided a sexing accuracy of 78.35%. The causes of variability in classification accuracies of different population along with the ambiguity regarding the "Rocker" shaped mandible are also discussed.

**Keywords:** Visual parameters; Indian population; Mandible; Sex determination

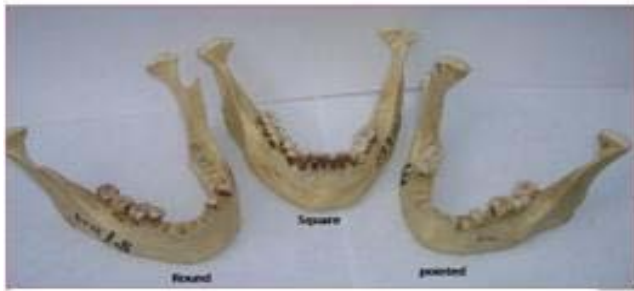## Introduction

The recovery of fragmentary and pathological skeletal remains, in forensic investigations, requires easy and rapid techniques for biological profiling and reconstruction of the scene history [1]. In biological profiling include sex determination makes the base for the further investigation related to age and stature estimation. Sex determination can be made either by using a visual or metric examination of the skeletal remains. Visual traits are a useful option for determining sex because the traits can be assessed easily and quickly without equipment thus the best approach for field investigation [2]. Non metric or visual traits also provide a means for determining sex when metric analyses are not possible due to fragmentation, trauma, or the lack of an appropriate reference sample. Non metric traits are assessed visually according to an ordinal scoring system that encompasses the range of trait expression between males and females or categorically. Non metric traits can be used without concern of population affiliation, and have thus become readily employed in sex estimation [2,3], although some traits are proved to be population specific such as mandibular ramus flexure [4]. Traditional linear measurements are not able to capture the shape differences of some complex and rounded structures, e.g. orbit shape, or prominence of the glabella or chin. For that reason, with a greater emphasis put on shape rather than size, visual assessment methods provided the most valuable tool to assess shape differences [5]. These traits are

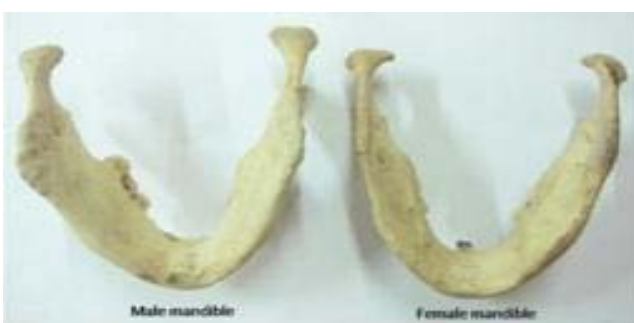sometimes called morphoscopic because it deals with the visual assessment of morphological characteristics of the bone [6]. Schulz [7] conducted one of the first non metric studies of the mandible for ancestral differences between Europeans and Africans.

As evident from the past studies, craniofacial region is the most dimorphic and easily sexed portion of skeleton after pelvis, providing accuracy up to 92%. But the facial bones are fragile in nature and usually the first to be destroyed by taphonomic processes except mandible which is the largest, strongest and most dimorphic, bone of craniofacial skeleton [8]. Previously several studies have mentioned the use of mandibular macroscopic traits for sex identification [4,9-11] with some studies quoting a high accuracy up to 97.1% [12,13]. Hu, et al. [9], studied 13 mandibular morphoscopic traits for sex discrimination in a sample of 107 modern Koreans (74 males, 33 females) and found that the simultaneous use of, the shape of the base of mandible and the shape of the chin-is the best method for predicting sex, to an accuracy over 90%. Sexual dimorphism of the mandible is primarily characterized by size, which is population-specific. However, the degree, pattern and classification accuracy of sexual dimorphism in mandibles that is valid for one population may not be the same for another [10].

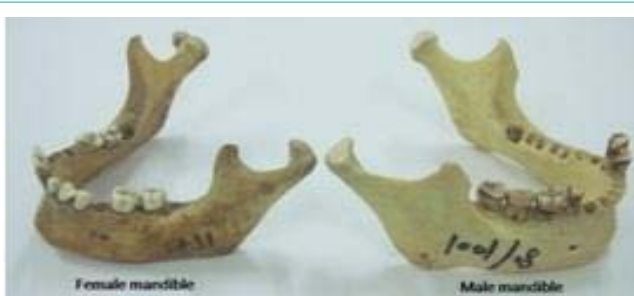So in the present study four visual parameters (i.e. chin shape, gonial flaring, contour of lower border and muscular attachments) are investigated for sex estimation. Though the shape differences in



**Figure 1:** Showing mandibles with round, square and pointed chin.



**Figure 2:** Showing gonial flaring, eversion in male inversion in female mandible.



**Figure 3:** Showing contour of lower border, straight female mandible and undulating male mandible.

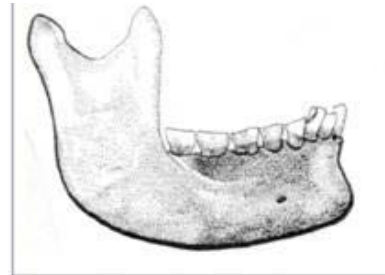
human mandibles are mentioned by all forensic anthropologists, but studies on Indian population are scanty. Therefore the aim of this study is to examine the ability and applicability of these variables in North Indian population and to ascertain whether these visual traits are population specific or not.

## Materials and Methods

A total of 189 mandibles, 143 males (18 to 70 years, mean age 38.58 years) and 46 females (20-60 years, mean age 31.75 years), were collected from Department of Forensic Medicine, IMS, BHU, Varanasi, India. All pathological, fractured, deformed mandibles were excluded from the study. The number of females was limited as compared to males because all samples were forensic cases. The four well known morphological characteristics were observed.

### The shape of the chin

It was classified into pointed, square or round. The chin shape was analyzed from inferior and anterior views. Relative development



**Figure 4:** Showing typical rocker shaped mandible.

of the mental protuberance and the mental tubercles determine the shape of the chin [7]. Three basic shapes have been noted:

**Round:** The chins in which there is either equal (but moderate) development of both protuberance and tubercles or only slight development of the mental tubercles.

**Square:** Those type of chin in which the mental tubercles display significant development combined with either a weak or moderated development of the mental protuberance.

**Pointed:** This category includes those mandibles in which there is a marked development of the mental protuberance combined with either a slight or moderate development of the mental tubercles. Male mandibles show predominantly square or round chin shape and female is characterized by pointed and round mandible [7] (Figure 1).

### The divergence of the gonial flaring

The direction of gonial flaring was classified inverted (inward), everted (outward) or straight. The outward flaring of the gonial region of the mandible is said to be a male characteristic while a classical inversion of gonion is seen in female mandibles (Figure 2).

### The contour of the lower border of mandible

Shape of the lower border of the mandible was classified into undulating, rocker and straight. Usually males show undulating or rocker-shaped lower border while female mandible shows a straight lower border [7]. Contour of the mandible was analyzed according to the presence and depth of the antegonial notch. If the inferior mandibular border appears to have no curvature, it is classified as "straight". Any superior concave curvature (antegonial notch) of the border located around the second molar is scored as "undulating" [7] (Figure 3).

### Muscular attachments

Muscular markings on mandible are divided in rough or smooth muscular attachments. Varying bony ridges or protuberances of different sizes may develop at muscle attachment points. A ramus that is flat and smooth to the touch is classified as smooth while ramus with ridging or raised attachment points was classified as rough [7].

To eliminate bias, the mandibles were observed separately for each trait at one time.

### Statistical analysis

**Cohen's kappa coefficient:** It is a statistical measure of inter-rater agreement for qualitative (categorical) items. Inter-rater reliability (kappa statistics) is a measure used to examine the compatibility between two observers on the assignment of categories

**Table 1:** Showing chin shape in North Indian population.

Sex	Chin Shape					
	Round		Square		Pointed	
	No	%	No	%	No	%
Male n=143	47	32.87	53	37.06	43	30.07
Female n=46	20	43.48	01	2.17	25	54.34

**Table 2:** Showing gonial flaring in North Indian population.

Sex	Gonial flaring					
	Eversion		Inversion		Straight	
	No	%	No	%	No	%
Male n=143	113	79.02	24	16.78	6	5.59
Female n=46	17	36.95	27	58.69	2	4.34

**Table 3:** Showing shape of the lower border of mandible North Indian population.

Sex	Contour of the lower border of mandible					
	Undulating		Straight		Rocker	
	No	%	No	%	No	%
Male n=143	88	61.58	55	38.46	0	0
Female n=46	15	32.61	31	67.39	0	0

**Table 4:** Showing muscular attachments on the ramus and body of mandible in the studied population.

Sex	Muscular attachment			
	Rough		Smooth	
	No	%	No	%
Male n=143	123	86.01	20	13.98
Female n=46	11	23.91	35	76.09

of a categorical variable. It is an important measure in determining how well an implementation of some coding or measurement system works. Previous researchers reported difficulties in identifying the visual traits due to its subjective nature, so inter and intra-observer errors were also calculated by Kappa statistics.

For error analysis a random sample of 40 mandibles (20 males and 20 females) was taken. For this, four traits were scored one by one separately by first observer. After one week the traits were again scored. For inter observer variability second observer examined the traits one by one (one trait at one time). The time gap between each session was two weeks to avoid any bias. The data was analyzed using SPSS 16.00 statistical package.

**Results**

Table 1, 2, 3 and 4 shows the number and percentage of males and females represents chin shape, gonial flaring, contour (shape) of lower border of mandible and muscular attachments. Table 1 clearly

**Table 5:** Showing Correct classification accuracies for each trait.

Sex	Chin shape		Gonial flaring		Shape of lower border		Muscular attachments	
	No of mandible	%	Number of mandibles	%	Number of mandibles	%	Number of mandibles	%
Male n=143	99 (square+round)	69.2	121 (everted+ straight)	84.60	88 (undulating)	61.5	123 (rough)	86.0
Female n=46	25 (Pointed)	54.34	27 (inverted)	58.70	31 (straight)	67.4	35 (smooth)	76.1
Overall accuracy N=189	124	65.61	148	78.35	119	62.96	158	83.59

**Table 6:** Showing intra observer error.

Trait	Kappa values	Significance	Interpretation
Gonial flaring	.688	.001	Substantial agreement
Shape of lower border	.894	.000	Almost perfect agreement
Chin shape	.634	.002	Substantial agreement
Muscular attachments	.560	.012	Moderate agreement

**Table 7:** Inter observer errors.

Trait	Kappa values	Significance	Interpretation
Gonial flaring	.762	.001	Substantial agreement
Shape of lower border	.794	.000	Substantial agreement
Chin shape	.765	.000	Substantial agreement
Muscular attachments	.529	.015	Moderate agree

shows that males cannot be identified on the basis of chin shape. All three types of chin shape are predominant in males. While in females only one mandible is found with square chin, means females have either pointed or round chin. Table 2 provides showed that straight gonion is very uncommon in North Indian population. Table 3 shows the complete absence of Rocker shaped mandible. Table 5 shows correct classification accuracies for males and females. This classification accuracy is based on previously defined criteria. For example, undulating mandibular border criteria is set for males and straight mandible for females. So in this way, the muscular attachment provided the best classification (83.59) for sex followed by gonial flaring (78.35). Lower border of mandible performed poor classification rate providing only about 63% sexing accuracy.

Table 6 presents the results of intra observer error in identifying the traits on first and second occasions. The kappa values are in range of (0.560-0.894). The highest kappa value is obtained for shape of lower border of mandible (0.894), which implies that this trait is easy to identify in comparison to other traits.

Table 7 provided results of agreement between first and second observer. The kappa values lied in between 0.529 to 0.794. Highest agreement is obtained for shape in lower border (0.794).

**Discussion**

Mandible can differentiate between sexes as the stages of mandibular development, growth rates, and duration are distinctly different in both sexes as shown by the metric study on same population [8]. Additionally, masticatory forces applied are distinctive for males and females, which influence the shape of the mandibular ramus and body.

**Chin shape**

The chin shape is a morphoscopic trait which is used to differentiate the sexes from a long time, and in general it is round

or square in males and pointed in females [7,9]. Hu, et al. [9] found in a study of Korean mandibles that the shape of the chin in most males was generally bilobate or square (91.7%), whereas the chin in females was either square (45.5%) or pointed (54.5%). Ongkana and Sudwan [14] studied Thai mandibles and found that square shape was shown by 50% of males followed by bilobed and pointed, while females showed pointed chin (54%) followed by square (45.8%). Berg and Taala [15] mentioned in their book that males are larger in both size and expression of traits. Males are inclined toward a more square or bilobate chin shape, particularly the US White sample. They also found that Black and White males were more predisposed to a partial or complete rocker shaped jaw as compared to females. Nagaraj and associates [16] studied 90 (M: F; 53:37) South Indian mandibles and found that 90.7% of males had either a bilobate or square chin, whereas 72.2% of females had a pointed chin. Further they added that sex determination based only on the shape of the chin is not sufficiently reliable. Recently Deana and Alves [11] investigated this trait in Brazilian population and found that the square shape was more frequent in males and the pointed form more frequent in females. The bilobate shape presented similar percentages for Black males, Black females and White females; the White males had the lowest percentage. The accuracy in determining sex using this morphological indicator was 82.7% in Black males, 61.9% in White males, 73.0% in Black females and 75.0% in White females. Inconsistent with the previous study on Korean, Thai, South-Indian and Brazilian mandibles, application of chin morphology for identifying sex of North Indian population revealed only a marginal level of sexual dimorphism. As in present study all three shape of chin was present in males, though square shape was little predominant. But female mandibles showed either pointed or rounded chin shape (97.8%) (Table 1).

### Gonial flaring

Gonial eversion (flaring) has been remain a males trait in many textbooks and research papers, though its use as sex indicator is rigorously investigated in last 2 decades [7,9,11,14,17,18]. In a previous study conducted by Angel and Kelley [19] indicated the population-specific nature rather than sex-specific frequencies for the trait. They found that European Americans were more likely to possess straight rami than Africans. The same has been detected in the study of Parr [7]. He found that Europeans are more likely to display a straight gonion while Africans show a slightly higher degree of the more extreme forms of eversion. Loth and Henneberg [18] studied a large sample consisted of 609 known sex Africans, American whites and blacks, and Paleo Amerindians from birth to over 90 years. They found only 45% sex classification accuracy using gonial eversion. Further they added that apart from the hereditary nature of this feature, bilateral eversion is uncommon and not limited to males, at least a third of individuals were indeterminate and little more than half of females have no eversion. On the other hand Grottenthaler and associates [20] found that gonial eversion, identified 75.4% males, and 45.2% females and 69.3% overall sex classification accuracy. They further concluded that it is prone to intra as well as inter-observer bias but have some merit as sex indicators, and showed marked functional and adaptive responses and may not be suitable for all samples. Furthermore, they attributed the trait to be influenced by local tooth loss, the closer the tooth to the gonion, the higher the rate of misclassification.

It is evidenced that loss of teeth initiates remodeling of both the body and the ramus of the mandible. The number of teeth lost also has a decisive influence on the gonial angle and the molar loss, in particular, influences the remodeling of the alveolar process, mandibular angle and the glenoid fossa [4,20].

Schutzkowaski [17] reported the presence of gonial eversion even at birth in the archaeological Spital fields sample. He observed 25 males and 15 females ranging in age from 0 to 5 years, and claimed that eversion was associated with males but the lack of the trait was not associated with females.

Ongkana and Sudwan [14] found that Thai males showed 50% outward flaring of gonion while 50% females showed straight gonion followed by inversion and eversion (25% both). In a recent study on Brazilian population, Diana and Alves [11] found that in white individuals the males presented the everted shape more frequently than the females, and the females presented the inverted shape more frequently than the males, however, no statistically significant difference was observed. The accuracy in determining sex using this morphological indicator was 93.1% for black males, 95.2% in white males, 34.3% in black females and 26.6% in white females. In the present study, we found that about 79% males showed a typical eversion of gonion. While the presence of inversion was found in only 58.69% females. Interestingly about 37% female mandibles showed eversion, which quite differs from the previous studies (Table 2). But it must be noted that the eversion was not as prominent as in males.

### Contour of the lower border of mandible

Hu, et al. [9] examined Korean mandible for the contour of the lower border of the mandible and found this variable was most significant for identifying sex. In their study rocker-shaped mandibles predominated in males (68.1%), whereas most females (84.6%) exhibited a straight mandibular base. Ongkana and Sudwan [14] found that antegonial notch was present (i.e. the undulating mandible) in 65.5% males while females showed straight border (70.8%). Chole, et al. [21] evaluated 1060 panoramic radiographs of Indians and found that males have greater antegonial depth than females, i.e. females tend to have more straight mandibles. In a study on South Indian population, Nagaraj, et al. (2016) found that all male mandibles (53) showed rocker-shaped, whereas all female mandibles (37) exhibited a straight inferior border of the mandible. In a study on Brazilians, Diana and Alves [11] found that the undulating shape of the contour of the base of the mandible was not present in the studied sample. White and Black individuals of both sexes presented the rocker shape more frequently than the straight shape. No statistical differences were observed for this morphological indicator between the sexes.

### Ambiguity in the definition of Rocker shaped mandible

Actually Hu, et al. [9] (2006) had a misconception regarding the term "Rocker shaped". They classified undulating mandible as rocker shaped in their studies see figure 1 B in Hu, et al. [9] and the same misconception is still continued. Several studies mentioned the same undulating mandibles as Rocker shaped [11,16] but the term "rocker" is applied to the mandible that has a convex or inferiorly-curving border. According to Weisler and Swindler, [22] one of the most striking features of a Polynesian skull is the "rocker" shaped mandibles, which is usually absent in other human populations.

The features of rocker shape mandible include absence of antegonial notch, and a convex lower border of the mandible extending around the gonial region onto the posterior surface of the ascending ramus which results in a mandible making contact only at one point (below the second permanent molar) on each side when placed on a plane surface. Thus the mandible is unstable and rocks back and forth and is known as rocker shaped [22] see Figure 4 [as cited in 23]. Geographically, the Polynesian population resides in Hawaii, New Zealand and Easter Island. They share the same origins as the indigenous peoples of maritime Southeast Asia, Madagascar, and Taiwan.

The first quote regarding Polynesian rocker-shaped jaw was mentioned by Scott (1893) but he did not mention the term "Rocker". The term was first coined by Martin (1928), which is the most frequent form of Polynesian mandible, which occurs in about 80% of Polynesians [23]. The rocker form only starts to appear in late childhood, from about 11 years of age. Polynesian mandibles below this age display, like their counterparts elsewhere, distinct antegonial notches and open gonial angles. Houghton [23] argued that the growth changes during the period of maturation of individuals of this group lead to the development of this particular mandibular form. So basically the Korean [9], South Indians [16] and Brazilian [11] males have undulating mandibles which they classified in their studies as Rocker shaped. While in the present study the trait "Rocker" was totally absent. The typical male feature "undulating" could identify only 61.5% males. On the other hand, 67.4% females showed straight border (Table 3) so we can say that it is not the criteria for differentiating male and female mandible.

### Muscular attachments

The group of muscles associated with movements of the jaw is called as masticatory muscles. There are four muscles including the masseter, temporalis, medial pterygoid and lateral pterygoid. The outer appearance of male mandibles is usually irregular and rough, whereas that of females is likely to be even and smooth. This contradiction may be caused by the relative development of the musculoskeletal system in different sexes. Further, on average, females produce weaker muscle forces during mastication, resulting in smoother surfaces of muscle attachments and smaller sized mandibles. Therefore, mandibular size and shape are affected by variable lifestyles, dietary behavior, and racial groups.

Parr [7] showed in his study that Africans have more robust muscle attachment sites than Europeans. Typical male mandibles are larger, with rougher surfaces of muscle attachments, while female mandibles are smaller in size with smooth surfaces of muscle attachments [24]. This trait was effectively identified males and females with 84% accuracy.

Trends towards masculinization in older females, especially in terms of skull morphology, have been documented previously [20]. In the present study we found a reflection of this pattern, especially in muscular development. Females more than 40 years frequently showed the masculine characters like undulating mandibular base and rough muscular attachments (but not so rough as in males).

### Inter and intra observer errors

Cohen's kappa coefficient is a statistic which measures inter-

rater agreement or qualitative (categorical) items. It is believed to be a much robust measure than simple percent agreement calculation, since  $\kappa$  also consider the possibility of the agreement occurring casually. Cohen suggested the Kappa result be interpreted as follows: values  $\leq 0$  as indicating no agreement and 0.01-0.20 as none to slight, 0.21-0.40 as fair, 0.41-0.60 as moderate, 0.61-0.80 as substantial, and 0.81-1.00 as almost perfect agreement [25]. Shape of lower border of mandible showed highest Kappa values in inters and intra-observer examination i.e. the trait is easiest to identify but provided lowest classification accuracy. On the other hand poorest agreement, as measured by the k statistic, was shown by muscular attachments within and between observers i.e. the trait is difficult to identify, but interestingly this trait provides highest classification accuracy of 83.59%.

Nicholson and Harvati, [26] found a complex combination of population history, climate and function affecting mandibular morphology. Hormonal and endocrine growth regulators also control sex differences. Many visible sex traits are absent in infancy and childhood, but developing fully in puberty as a result of endocrine stimulus [4,24]. Size and specific muscular shape, which develop during puberty, arise as the most diagnostic sex-related characters. Males produce stronger muscle forces, resulting in rough surfaces of muscle attachments, especially at the coronoid process and gonion [24,27]. Sexual dimorphism in mandibular morphology is influenced by several factors including genetic and environmental factors, with sexual selection [28]. Previous research on same population suggested that improved nutrition and healthcare also affect the growth and craniofacial morphology [29].

### Conclusion

The roughness of muscular attachments was the best trait for identifying males and females with highest classification accuracy of 83.59% followed by gonial flaring (78.35%). The present study demonstrated that how comprehensibility of trait definition, instead of number of character traits, is crucial for effectively determining sex by the morphoscopic method. It is also concluded that the morphological traits are also affected by population variation, a visual trait which is highly dimorphic in one population may provide lower sexing accuracy in other population. The results of this investigation open the door to further inquiry concerning population variation in the morphology of the human mandibular shape. Further analysis is in progress to enlarge the sample size, including additional different age groups to this research as well as adding a series of measurements of the cranium and mandible to see if there are true distinctions between different age groups or if the differences are an artifact of size, shape, or functional variation between sexes. However, we hope to contribute to the ongoing discussion of modern human variation and the accuracy and consistency of metric and non-metric techniques in relation to forensic anthropology.

### Acknowledgment

I am highly thankful to my mentors Prof. SK Tripathi and Prof SN Shamal and statistician Prof. TB Singh for their valuable support during research in IMS, BHU, Varanasi.

### References

1. Kranioti EF, Bastir M, Sanchez-Meseguer A, Rosas A. A geometric-

- morphometric study of the Cretan humerus for sex identification. *Forensic Sci Int.* 2009; 189: 111.e1-111.e8.
2. Langley NR, Dudzik B, Cloutier A. A Decision Tree for Nonmetric Sex Assessment from the Skull. *J Forensic Sci.* 2017.
  3. Rogers TL. Determining the sex of human remains through cranial morphology. *J Forensic Sci.* 2005; 50: 493-500.
  4. Loth SR, Henneberg M. Mandibular ramus flexure: a new morphologic indicator of sexual dimorphism in the human skeleton. *Am J Phys Anthropol.* 1996; 99: 473-485.
  5. Gonzalez PN, Bernal V, Perez SI. Analysis of Sexual Dimorphism of Craniofacial Traits Using Geometric Morphometric Techniques. *Int J Osteoarchaeol.* 2009.
  6. Vitek C. A Comparison in Osteological Measurements of Two Populations from East Tennessee. The University of Tennessee. 2005.
  7. Parr NML. Determination of Ancestry from Discrete Traits of the Mandible. University of Indianapolis. 2005.
  8. Saini V, Srivastava R, Rai RK, Shamal SN, Singh TB, Tripathi SK. Mandibular ramus: an indicator for sex in fragmentary mandible. *J Forensic Sci.* 2011; 56 Suppl 1: S13-16.
  9. Hu KS, Koh KS, Han SH, Shin KJ, Kim HJ. Sex determination using nonmetric characteristics of the mandible in Koreans. *J Forensic Sci.* 2006; 51: 1376-1382.
  10. Saini V, Srivastava R, Rai RK, Shamal SN, Singh TB, Pandey AK, Tripathi SK. Sex determination using mandibular ramus flexure: A preliminary study on Indian population. *J Forensic Leg Med* 2011;18:208-212.
  11. Deana NF, Alves N. Nonmetrical sexual dimorphism in mandibles of Brazilian individuals. *Biomed Res.* 2017; 28: 4233-4238.
  12. Schmittbuhl M, Le Minor JM, Taroni F, Mangin P. Sexual dimorphism of the human mandible: Demonstration by elliptical Fourier analysis. *Int J Leg Med* 2001; 115:100-101.
  13. Schmittbuhl M, Le Minor JM, Schaaf A, Mangin P. The human mandible in lateral view: elliptical fourier descriptors of the outline and their morphological analysis. *Ann Anat.* 2002; 184: 199-207.
  14. Ongkana N, Sudwan P, Morphologic Indicators of Sex in Thai Mandibles. *Chiang Mai Med J.* 2010; 49: 123-128.
  15. Berg GE, Taala SC. Biological affinity in forensic identification of human skeletal remains beond black and white. Taylor and Francis. 2014.
  16. Nagaraj T, Veerabasvaiah BT, James L, Goswami RD, Narayanan S, Keerthi I. Use of non-metric characteristics of mandible in sex determination. *J Med Radiol Pathol & Surg.* 2016; 2: 1-4.
  17. Schutkowski H. Sex determination of infant and juvenile skeletons: I. Morphognostic features. *Am J Phys Anthropol.* 1993; 90: 199-205.
  18. Loth SR, Henneberg M. Gonial eversion: facial architecture, not sex. *Homo.* 2000; 51: 81-89.
  19. Angel LJ, Kelley JO. Inversion of the Posterior Edge of the Jaw Ramus: New Race Trait. In *Skeletal Attribution of Race.* George W. Gill and Stanley Rhine, eds. Pp.1-9. Albuquerque: University of New Mexico Press. 1990.
  20. Kemkes-Grottenthaler A, Löbig F, Stock F. Mandibular ramus flexure and gonial eversion as morphologic indicators of sex. *Homo.* 2002; 53: 97-111.
  21. Chole RH, Patil RN, Chole SB, Gondivkar S, Gadball AR, Yuwanati MB. Association of Mandible Anatomy with Age, Gender, and Dental Status: A Radiographic Study. *ISRN Radiology.* 2013.
  22. Weisler MI, Swindler D. Rocker jaws from the Marshall Islands: Evidence for interaction between eastern Micronesia and west Polynesia. *People and Culture in Oceania.* 2002; 18: 23-33.
  23. Houghton P. Polynesian mandibles. *J Anat.* 1978; 127: 251-260.
  24. Vodanovic M, Dumancic J, Demo Z, Mihelic D. Determination of sex by discriminant function analysis of mandibles from two Croatian archeological sites. *Acta Somatica Croat.* 2006; 40: 263-277.
  25. McHugh ML. Interrater reliability: the kappa statistic. *Biochem Med (Zagreb).* 2012; 22: 276-282.
  26. Nicholson E, Harvati K. Quantitative analysis of human mandibular shape using three-dimensional geometric morphometrics. *Am J Phys Anthropol.* 2006; 131: 368-383.
  27. Rosas A, Bastir M. Thin-plate spline analysis of allometry and sexual dimorphism in the human craniofacial complex. *Am J Phys Anthropol.* 2002; 117: 236-245.
  28. BejdovĀj S, KrajĀĀek V, VelemĀnskĀj J, HorĀĀk M, VelemĀnskĀĀ P. Changes in the sexual dimorphism of the human mandible during the last 1200 years in Central Europe. *Homo.* 2013; 64: 437-453.
  29. Saini V. Significance of temporal changes on sexual dimorphism of cranial measurements of Indian population. *Forensic Sci Int.* 2014; 242: 300.