

Special Article - Current Endoscopic Therapy in Japan

Endoscopic Band Ligation for Bleeding Colonic Diverticulosis

Yuzo Otaki*, Satohiro Matsumoto, Hiroyuki Miyatani and Yukio Yoshida

Department of Gastroenterology, Saitama Medical Center, Jichi Medical University, Japan

*Corresponding author: Yuzo Otaki, Department of Gastroenterology, Saitama Medical Center, Jichi Medical University, 1-847 Amanuma, Omiya, Saitama, Saitama 330-8503, Japan, Tel: +81 48 647 2111; Fax: +81 48 648 5188; Email: srtkotkyz@gmail.com

Received: December 19, 2014; Accepted: February 23, 2015; Published: February 25, 2015

Abstract

Bleeding colonic diverticulosis is the most common underlying disease causing severe lower gastrointestinal bleeding, and endoscopic hemostasis is commonly used to control the bleeding. While a number of reports have been published on endoscopic hemostasis, no standard procedure has been established yet. However, Endoscopic Band Ligation (EBL) has been reported to be beneficial. We performed EBL in 4 patients with bleeding colonic diverticulosis. All of them visited our hospital with the chief complaint of bloody stool and underwent emergency colonoscopy. Hemostasis was achieved in a single session in all patients, and neither rebuilding nor any complication was observed. Because EBL is relatively easy to perform and may be expected to be associated with a low rebleeding rate, it is useful for the treatment of bleeding colonic diverticulosis.

Keywords: Bleeding colonic diverticulosis; Endoscopic band ligation; Endoscopic variceal ligation

Abbreviations

EBL: Endoscopic Band Ligation; EVL: Endoscopic Variceal Ligation

Introduction

The prevalence of colonic diverticulosis is increasing in both Western and Asian countries [1,2]. Colonic diverticulosis is considered as the most common underlying disease causing severe lower gastrointestinal bleeding, accounting for approximately 30–40% of all cases of lower gastrointestinal bleeding [3]. Colonoscopy, which enables diagnosis and therapeutic intervention in patients presenting with lower gastrointestinal bleeding, is often the first modality used for detailed examination of colonic bleeding [4]. For endoscopic hemostasis, although a variety of methods, including local injection of epinephrine, contact coagulation, hemostatic clipping or combinations of these methods, have been reported, hemostatic clips are the most frequently used [5,6]. However, because of the relatively high rate of rebleeding (22–34%) in patients undergoing hemostatic clipping for the control of colonic bleeding, further therapeutic innovation is desired [7,8]. In recent years, Endoscopic Band Ligation (EBL) using an Endoscopic Variceal Ligation (EVL) device has been reported to be useful for the treatment of bleeding

colonic diverticulosis [9-13]. We report our experience with 4 cases of bleeding colonic diverticulosis in which EBL was effective for the control of bleeding.

Materials and Methods

EBL was performed in 4 (3 men and 1 woman) out of 55 patients who were diagnosed as having bleeding colonic diverticulosis at our hospital between April 2013 and October 2014. In all the 4 patients, the procedure was performed by one of 3 endoscopists with experience of performing 1000 or more colonoscopies. All patients visited our hospital with the chief complaint of bloody stool and underwent emergency colonoscopy equipped with a water-jet system (PCF-Q260AZI; Olympus, Tokyo, Japan). After active diverticular bleeding or an exposed blood vessel in a diverticulum was identified, a marking clip (HW-610-090L; Olympus, Tokyo, Japan) was placed near the site, and the endoscope was removed and replaced with an upper gastrointestinal endoscope (GIF-Q240; Olympus, Tokyo, Japan); this latter scope was inserted with an EVL device (MD-48170 EVL Device; Sumitomo Bakelite, Tokyo, Japan) attached to its tip. After the bleeding site was identified using the marking clip as the target, the diverticulum was inverted by means of vacuum, and an O-ring was placed at the neck of the inverted diverticulum. Hemostasis was confirmed, and the procedure was completed.

Table 1: Sample Text.

No	Age	Sex	Ht (%)	Colonic lavage	Bleeding Site	State of Bleeding	Hemostasis	Procedure Time (min)	Complication	Rebleeding	Hospitalization (Days)	Follow-up Period (mon)
1	76	M	42.3	-	Ascending	Non-active, visible vessel	Yes	33	-	-	0	4
2	81	F	26.8	+	Ascending	Non-active, visible vessel	Yes	68	-	-	6	16
3	49	M	43	-	Sigmoid	Active	Yes	62	-	-	3	5
4	92	M	42.2	-	Sigmoid	Active	Yes	13	-	-	5	18

Ht; Hematocrit

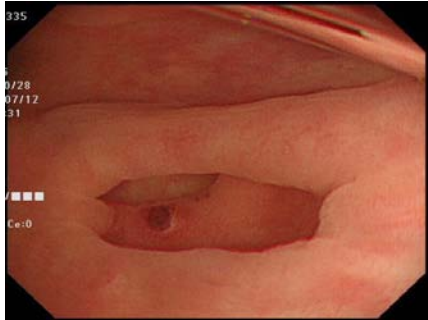


Figure 1A: An exposed blood vessel in an ascending colonic diverticulum.

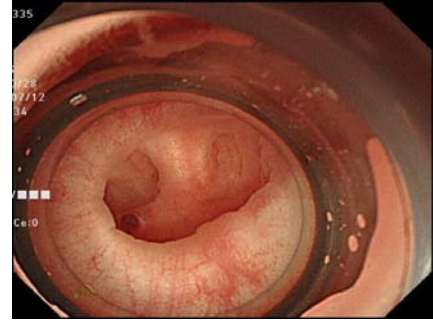


Figure 1C: The endoscope reinserted with an EVL device attached to its tip.

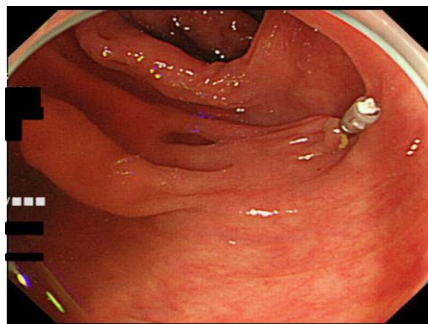


Figure 1B: A marking clip placed near the diverticulum with the exposed blood vessel.

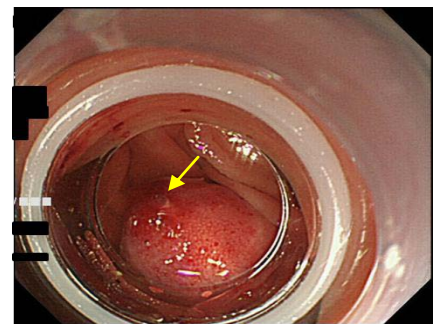


Figure 1D: After an O-ring has been placed, the exposed blood vessel is observed around the center of the inverted and ligated diverticulum (arrow).

Results

The mean age at the time of the diagnosis was 75 years (range: 49–92 years). The mean hematocrit value was 38.5% (range: 26.8–42.3%). Before emergency colonoscopy, colonic lavage was performed in only one patient, whereas the remaining 3 patients underwent colonoscopy without lavage due to poor general conditions. The bleeding sites were the sigmoid colon in 2 patients and the ascending colon in 2 patients. In regard to the current state of bleeding, active bleeding was observed in 2 patients, while an exposed blood vessel, but no active bleeding, was noted in the remaining 2 patients. Hemostasis was achieved by EBL in all the 4 patients. The mean procedure time was 44 minutes (range: 13–68 min), and no complication including abdominal pain or perforation was observed in any of the patients. The mean length of hospital stay after the EBL procedure was 3.5 days (range: 0–6 days). The mean follow-up period was 10.7 months (range: 4–18 months). None of the patients developed any rebleeding episodes (Table 1).

Case Presentation

A 76-year-old man visited the emergency outpatient unit of our hospital with the chief complaint of bloody stool. Rectal examination revealed dark red bloody stool. Because clinical signs of shock were detected, rapid fluid replacement was performed. After improvement of the hemodynamic conditions of the patient was confirmed, emergency colonoscopy was performed without colonic lavage. Multiple diverticula were observed in the ascending colon, and an exposed blood vessel was found in one of them (Figure 1A). EBL was performed as mentioned above (Figure 1B, 1C & 1D). Hemostasis was achieved in a single session, and the procedure was completed without any complications. Until date, 4 months since the procedure, no rebleeding episode has been observed.

Discussion

EBL was reported to be useful for the treatment of bleeding colonic diverticulosis by Witte et al. in 2000, and there have been sporadic reports of the usefulness of this procedure since then [9–13]. In EBL, the hemostatic procedure by ligation is relatively easy. Usually after a single session of O-ring placement, the success rate for hemostasis is high, ranging from 89–96%, and the rebleeding rate is low (0–11%). As seen in our experience, by placing an O-ring after inversion of the diverticulum using sufficient vacuum, reliable hemostasis was achieved in a single session in all patients. Moreover, there have been no reports of serious accidental events caused by EBL, including in our case series; thus, the procedure appears to be highly safe. Meanwhile, because the visual field becomes smaller after attachment of the EVL device, this procedure should be performed after identification of the bleeding site. Although these manners seem to be troublesome, the mean procedure time was 44 minutes, which was considered to be acceptable for emergency hemostasis for diverticular bleeding. Rapid bowel lavage is generally recommended for acute lower GI bleeding before emergency colonoscopy [14]. In this study, 3 of 4 patients underwent colonoscopy without lavage due to poor general conditions including higher age or instability of hemodynamics. In these situations, colonoscopy with water-jet system was useful for detection of bleeding site and following EBL. Our study has several limitations including the small number of patients, shorter follow up period. We hope that further clinical studies will help to verify these findings.

Conclusion

EBL appears to be useful for the treatment of bleeding colonic

diverticulosis, in terms of providing reliable hemostasis and a low rebleeding rate.

References

1. Delvaux M. Diverticular disease of the colon in Europe: epidemiology, impact on citizen health and prevention. *Aliment Pharmacol Ther.* 2003; 18: 71–74.
2. Nakada I, Ubukata H, Goto Y, Watanabe Y, Sato S, Tabuchi T, et al. Diverticular disease of the colon at a regional general hospital in Japan. *Dis Colon Rectum.* 1995; 38: 755–759.
3. Longstreth GF. Epidemiology and outcome of patients hospitalized with acute lower gastrointestinal hemorrhage: a populationbased study. *Am J Gastroenterol.* 1997; 92: 419–424.
4. Jensen DM, Machicado GA, Jutabha R, Kovacs TO. Urgent colonoscopy for the diagnosis and treatment of severe diverticular hemorrhage. *N Engl J Med.* 2000; 342: 78–82.
5. Simpson PW, Nguyen MH, Lim JK, Soetikno RM. Use of endoclips in the treatment of massive colonic diverticular bleeding. *Gastrointest Endosc.* 2004; 59: 433–437.
6. Yoshikane H, Sakakibara A, Ayakawa T, Watanabe M, Hashimoto S, Mori S, et al. Hemostasis by capping bleeding diverticulum of the colon with clips. *Endoscopy.* 1997; 29: S33-S34.
7. Kaltenbach T, Watson R, Shah J, Friedland S, Sato T, Shergill A, et al. Colonoscopy with clipping is useful in the diagnosis and treatment of diverticular bleeding. *Clin Gastroenterol Hepatol.* 2012; 10: 131-137.
8. Ishii N, Hirota N, Omata F, Itoh T, Uemura M, Matsuda M, et al. Location in the ascending colon is a predictor of refractory colonic diverticular hemorrhage after endoscopic clipping. *Gastrointest Endosc.* 2012; 76: 1175-1181.
9. Farrell JJ, Graeme-Cook F, Kelsey PB. Treatment of bleeding colonic diverticula by endoscopic band ligation: an *in-vivo* and *ex-vivo* pilot study. *Endoscopy.* 2003; 35: 823-829.
10. Lee Ij, Park CH, Kwon JW, Kim SJ, Park JW, Kim KO, et al. Complete closure of a colonic bleeding diverticulum using endoscopic hemoclip and band ligation. *Gastrointest Endosc.* 2012; 75: 425-426.
11. Witte JT, Bohlman T. Endoscopic band ligation of colonic bleeding. *Gastrointest Endosc.* 2000; 51: 117-119
12. Ishii N, Setoyama T, Deshpande GA, Omata F, Matsuda M, Suzuki S, et al. Endoscopic band ligation for colonic diverticular hemorrhage. *Gastrointest Endosc.* 2012; 75: 382-387.
13. Shibata S, Shigeno T, Fujimori K, Kanai K, Yoshizawa K. Colonic diverticular hemorrhage: the hood method for detecting responsible diverticula and endoscopic band ligation for hemostasis. *Endoscopy.* 2014; 46: 66-69.
14. Ghassemi KA, Jensen DM. Lower GI bleeding: epidemiology and management. *Curr Gastroenterol Rep.* 2013; 15: 333.