

Case Report

Generalised Abdominal Cellulitis: A Rare and Severe Complication following a Laparoscopic Procedure

Ayakannu T^{1,2*}, Papadopoulos A¹, Ash R¹, Houghton S³, Montalto SA¹, Khan M⁴ and Devaja O¹

¹Gynaecology Oncology Cancer Centre, Maidstone Hospital, England

²Department of Gynaecological Oncology, Royal Surrey County Hospital, England

³Department of Radiology, Maidstone Hospital, England

⁴Department of Microbiology, Maidstone Hospital, England

*Corresponding author: Thangesweran Ayakannu, Department of Gynaecological Oncology in Royal Surrey County Hospital and Gynaecology Oncology Cancer Centre, Maidstone Hospital, Hermitage Lane, Maidstone, Kent, ME16 9QQ, England

Received: January 06, 2017; Accepted: April 06, 2017;

Published: April 13, 2017

Introduction

Laparoscopic surgery was introduced approximately 30 years ago and represents a major advance in surgical technique. Its application to both benign and malignant gynaecology presentations has become a worldwide and standard procedure offered to patients. The numerous advantages of the laparoscopic surgical technique such as, decreased hospital stay, reduced blood loss and the resultant reduced need for blood transfusion; decreased risk of blood vessel injury; decreased incidence of post-operative adhesions; improved post-operative recovery times with associated healthcare financial gains have been well documented [1]. Despite these advantages, laparoscopic surgery has associated complications some of which are seldom reported. Abdominal cellulitis is one such complication which potentially can be fatal if it progresses to necrotising fasciitis [2]. Therefore it needs to be promptly and adequately treated to prevent major significant complications.

Case Presentation

The patient was a 37 year old, apparently healthy; woman with a BMI of 30.0 Kg/m² who had an ultrasound scan for lower abdominal pain. The scan revealed multi-cystic ovary measuring between 5-6 cm in diameter suggestive of endometriotic cysts confirmed on MRI scan, with associated mildly elevated serum tumour makers, CA19-9 of 39 Units (< 27), CEA of 7 Units (< 4) and a normal CA125 of 14 Units (< 35). Previous surgical history included a left salpingo-oophorectomy *via* the abdominal approach for a large dermoid cyst 10 years ago, subsequently, nine years ago; she was diagnosed with invasive adenocarcinoma of the cervix, and underwent a Wertheim's hysterectomy and bilateral pelvic lymph node dissection.

The Magnetic Resonance Imaging (MRI), Ultrasound Scan (USS) features and unremarkable tumour markers suggested benign looking endometriotic cysts and following counselling she opted for surgical

Abstract

The advantage of minimal access surgery for benign and malignant gynaecological conditions has already been established with decreased risk of blood vessel injury and reduction in blood transfusions being prevalent. Here we report a case of a 37 year old woman with BMI of 30 Kg/m² and a known cervical cancer patient presenting with postoperative abdominal cellulitis after a routine elective laparoscopic procedure. An uneventful laparoscopic right salpingo-oophorectomy was performed for endometriotic ovarian cysts. Generalised abdominal cellulitis developed on the third day after surgery and asepsis protocol with strict fluid resuscitation and antibiotic regimen started. Recognising this complication of laparoscopic surgery, its early diagnosis and prompt treatment are keystones for successful management of this potentially fatal condition.

Keywords: Abdominal cellulitis; Complication; Laparoscopy

management and underwent an uneventful elective laparoscopic right salpingo-oophorectomy. The patient was discharged the following day as she was well with no concerns. On the 3rd post-operative day, the patient developed generalised abdominal pain, redness and abdominal swelling, she complained of feeling hot, and returned to the hospital. She was re-admitted, with a temperature of 38.0°C, pulse 80 bpm, and BP 105/64 mmHg. On examination, the abdomen was very tender, with erythema and distension, suggestive of abdominal cellulitis. The patient underwent a full septic screen and started on IV Augmentin with fluid resuscitation management as per the local (Maidstone and Tunbridge NHS Trust) septic protocol. Her serum lactate level was normal, White Cell Count (WCC) 15.97×10⁹/ml (3.40-11.0), neutrophil 13.02 Units (1.7-11.0) and C-Reactive Protein (CRP) of 195 Units (< 5). An ultrasound scan of the abdomen and pelvis, revealed evidence of thickened subcutaneous tissues and oedema across the lower abdomen in keeping with a diagnosis of generalised cellulitis. No discrete subcutaneous or anterior abdominal wall collections were evident (Figure 1).

Twenty four hours after initiation of intravenous antibiotic treatment, the patient's clinical conditions improved, the abdominal cellulitis showed evidence of improvement (the redness had reduced, the abdominal swelling improved and clinically the abdominal discomfort had markedly improved) and WCC was 11×10⁹/ml, neutrophil 8 Units and CRP 104 Units. Blood cultures, urine culture and wound swabs which were sent for microbiology culture tests revealed no evidence of growth. On day 6, her abdominal cellulitis was markedly improved and the patient was discharged on oral antibiotics (Co-amoxiclav 625 mg per orally for three times a day) for ten days.

Discussion

The case is of educational value for the rarity of this complication following laparoscopic surgical procedure. It is well documented

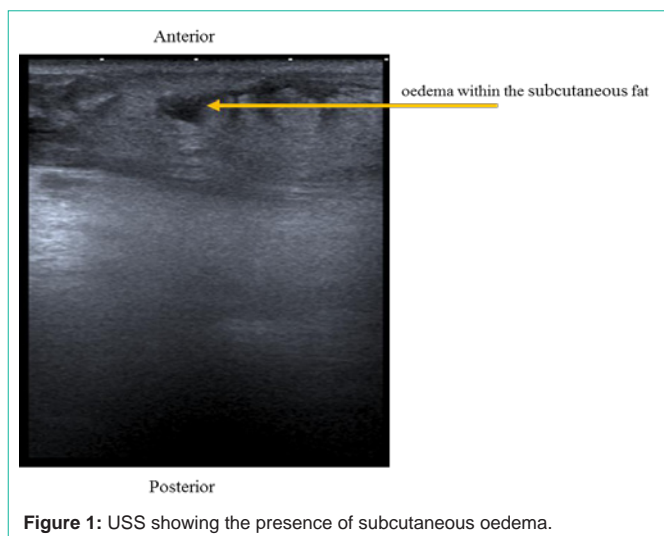


Figure 1: USS showing the presence of subcutaneous oedema.

Table 1: Literature search outcome of severe cellulitis complications following a laparoscopy.

Indications	Number of patients	References
Colonic surgery	Two	[5,6]
Appendectomy	Two	[7,8]
Cholecystectomy	Two	[9,10]
Total hysterectomy	Two	[11,12]
Radical prostatectomy	One	[13]
Repair of perforated duodenal ulcer	One	[9]

that laparoscopic surgery results in lower infection rates in surgical wounds, and that severe wound infections are rare [3]. Here, we present a case of severe abdominal cellulitis that rapidly progressed to the entire abdomen that was recognised and managed immediately with intravenous antibiotics. Despite negative culture results, we recognise that if diagnosis or treatment had been delayed, a more serious condition, such as necrotizing fasciitis, may have developed. Severe abdominal cellulitis is a rare but potentially fatal complication of laparoscopic surgery, with a reported mortality of 15%-52% [4]. To the best of our knowledge, this is the first reported case of severe abdominal cellulitis following a laparoscopic gynaecological surgical procedure (laparoscopic salpingo-oophorectomy) with a woman with previous history of cervical cancer. A literature search revealed a very limited number of reported cases of severe abdominal cellulitis or severe necrotizing fasciitis (Table 1). A literature review reported that despite intensive treatment, including debridement, three of the 10 patients died of secondary multiple organ failure (Table 1).

In this case, it was not possible to identify the cause of this severe abdominal cellulitis. Causes of severe cellulitis and necrotizing fasciitis have been identified in other studies, these includes: direct spreading of the abdominal abscess through the anterior abdominal wall, direct involvement of the incision as well as haematogenous bacterial infections. However, in this case, no abscesses were identified; no single port site was involved with negative wound swabs noted and finally all blood cultures were negative.

The cause of this severe generalised abdominal cellulitis in our patient remains unknown. The generalised severe abdominal

cellulitis was associated with the presence of significant subcutaneous oedema across the lower abdomen. In this case the risk of developing necrotising cellulitis is difficult to quantify, from the literature, there have been cases after laparoscopic surgery related to the port site of the trocars [7,9,11], which imply a direct or indirect causation link between development of severe subcutaneous oedema, severe cellulitis and necrotising fasciitis. Other causes associated with the development of severe abdominal cellulitis include poor surgical technique (improper surgical skin incision, *verses* needle placement and sites of abdominal entry). In addition, prolonged operative time, increased age, increased end-tidal carbon dioxide and increased number of ports and multiple entries are significantly associated with severe tissue oedema and progression to generalise severe abdominal cellulitis [2,7].

Conclusion

A case of severe generalised abdominal cellulitis after laparoscopic salpingo-oophorectomy is presented. It is important to recognise this complication and provides an early diagnosis with early involvement of the microbiology team for appropriate guidance in relation to antibiotic regimen and appropriate treatment including supportive treatment such as fluid resuscitation and analgesia in order to avoid more serious complications.

References

- Devaja O, Samara I, Papadopoulos AJ. Laparoscopically Assisted Vaginal Hysterectomy (LAVH) *versus* Total Abdominal Hysterectomy (TAH) in endometrial carcinoma: Prospective cohort study. *Int J Gynecol Cancer*. 2010; 20: 570-575.
- Vilos G, temamian A, Dempster J, Laberge P. Laparoscopic entry: A review of techniques, and complications. *J Obstet Gynaecol Can*. 2007; 29: 433-465.
- Tjandra JJ, Chan MK. Systematic review on the short-term outcome of laparoscopic resection for colon and rectosigmoid cancer. *Colorectal Dis*. 2006; 8: 375-388.
- Tillow A, St Hill CR, Brown C, Velmahos G. Necrotizing soft tissue infections: Improved outcomes with modern care. *Am Surg*. 2004; 70: 841-844.
- Brodik G, van Bilsen SJ, Becker T, Jasker P, Otte WD. Necrotizing fasciitis following laparoscopic left hemicolectomy for diverticulitis. *J Laparoendosc Adv Surg Tech A*. 2010; 20: 65-67.
- Tan LG, See JY, Wong KS. Necrotizing fasciitis after laparoscopic colonic surgery: Case report and review of the literature. *Surg Laparosc Percutan Tech*. 2007; 17: 551-553.
- Raghavendra GK, Mills S, Carr M. Port site necrotising fasciitis following laparoscopic appendectomy. *BMJ Case Rep*. 2010; 12: 2375.
- Ahmed AR, Sharma K, Wellwood J. Necrotising fasciitis following laparoscopic appendectomy. *Ann R Coll Surg Engl*. 2008; 90: 1-3.
- Hewitt PM, Kwong KH, Lau WY, Chung SCS, Li AKC. Necrotizing fasciitis after laparoscopic surgery. *Surg Endosc*. 1997; 11: 1032-1033.
- Mittermair RP, Schobersberger W, Hasibeder W, Allerberger F, Peer R, Bonatti H. Necrotizing fasciitis with *Clostridium perfringens* after laparoscopic cholecystectomy. *Surg Endosc*. 2002; 16: 716.
- Golshani S, Simons AJ, Der R, Ortega AE. Necrotizing fasciitis following laparoscopic surgery. Case report and review of the literature. *Surg Endosc*. 1996; 10: 751-754.
- Van Ooijen P, TerHaar JF, Pijnenborg JM. Extensive cellulitis as the first symptom of ureter lesion after laparoscopic hysterectomy. *J Laparoendosc Adv Surg Tech A*. 2011; 21: 249-250.
- EL Karoui K, Lantemier F, Taieb F, Poirée S, Zahar JR, Mechai F, et al. *Escherichia coli* extensive cellulitis after laparoscopic radical prostatectomy. *Urology*. 2008; 72: 778-779.