

Case Report

Ovarian Sertoli Cell Tumor and its Association with Infertility in a Patient with Peutz–Jeghers Syndrome

Antovska Vesna¹; Pavlovski Borivoje¹; Sozovska Eva^{1*};
Sejfullai Siandra¹; Jovanovich Rubens²

¹University Clinic of Gynecology and Obstetrics, Medical faculty, Skopje, R North Macedonia

²Institute of Pathology, Medical Faculty, Skopje, R North Macedonia

*Corresponding author: Sozovska Eva

University Clinic of Gynecology and Obstetrics, Medical faculty, Skopje, R North Macedonia.

Email: esozovska@yahoo.com

Received: September 05, 2023

Accepted: October 14, 2023

Published: October 21, 2023

Introduction

Sertoli Cell Tumor (SCT) is a rare sex cord-stromal tumor of the ovary, marked by a wide range of clinical, histological, and biochemical elements, and constitutes a complex diagnosis and treatment. Ovarian sex cord-stromal tumors account for only 2.1% of all primary ovarian cancers. Sertoli, Leydig, and Sertoli-Leydig cell tumors (SLCTs), also called androblastomas, are ovarian sex cord-stromal tumors that constitute less than 0.5% of all ovarian tumors [1]. These tumors most often occur in young women (20-30 years old), and they are commonly unilateral, confined to the ovary, and usually large in dimensions [2]. They are frequently characterized by the presence of androgen production, but only 30% of patients display signs of virilization or defeminization. Peutz–Jeghers Syndrome (PJSy) is a rare autosomal dominant genetic disorder characterized by mucocutaneous pigmentation, benign hamartomatous gastrointestinal polyposis, and predisposition to benign and malignant tumors of the gastrointestinal tract, breast, ovary, uterine cervix, and uterus³. Its incidence is estimated at approximately 1 in 25,000 to 300,000 births. It happens due to germline-inactivating mutations in one allele of the *STK11/LKB1* gene at chromosome 19p13.3 that are found in most PJSy. Genital tract neoplasms in female patients with PJSy include ovarian neoplasms from the epithelial and stromal cells, minimal deviation adenocarcinoma (adenoma malignum) of the cervix and adenocarcinoma of the endometrium. The most common ovarian neoplasm found in patients with PJSy are the Sex Cord Tumor with Annular Tubules (SCTAT) and Sertoli cell tumor of the ovary and, to a lesser extent, mucinous epithelial ovarian tumor, ovarian serous tumor, and ovarian mature teratoma [4].

Abstract

We present a case of a 39-year-old woman whose primary concern was infertility, for which she came to the University Clinic for Gynecology and Obstetrics, Medical Faculty, Skopje, seeking further evaluation. On routine ultrasound, a solid tumor of the right ovary was visualized. She had been previously diagnosed with Peutz–Jeghers syndrome. She underwent a right salpingo-oophorectomy, and the final histopathological diagnosis revealed a well-differentiated Sertoli cell tumor of the right ovary.

Keywords: Sertoli cell ovarian tumor; Peutz–Jeghers syndrome; Infertility

Case Presentation

A 39-year-old woman whose main complaint was infertility was referred to the Department of Infertility at The University Clinic for Gynecology and Obstetrics, Medical Faculty, Skopje. During the vaginal ultrasound investigation, a large solid tumor of the right ovary was visualized (Figure 1). She had been previously diagnosed with Peutz–Jeghers syndrome, for which she underwent regular medical check-ups. Baseline serum hormone levels on the third day of her menstrual cycle were as follows: FSH 5.89 mIU/ml; LH 3.1 mIU/mL; E2 28 pg/mL; Testosterone 2.77 nmol/, i.e., they were all in normal ranges for a reproductive age. Thus, an assumption that a Sertoli cell tumor might be involved was not immediately evident. Tumor markers were also within normal ranges (Ca125, CEA, Inhibin, AFP, beta-hCG). The ultrasound identified a solid ovarian tumor of the right ovary with dimensions of 65x60 mm. The scoring system ROMI [5] showed low risk for ovarian carcinoma, e.g., ROMI =1 point: generative age (0 points), tumor size ≥6cm (1 point), solid tumor (0 points), serum levels of CA-125 ≤35 U/ml (0 points), absence of the ascites (0 points). The Resistance Index (RI) on Doppler examination was 0,87, which did not indicate a malignant nature of the tumor. Consequently, a benign pathology was suspected, specifically an ovarian fibroma.

During laparoscopic exploration of the pelvis and abdomen, a solid, yellow-colored mass was detected in the right ovary, which was attached loosely to the bowel, colon, and pelvic cavity. The mass did not show infiltration to the adjoining structures. The uterus, the left adnexa, and the peritoneum macroscopically had no pathological deposits, and no pelvic and

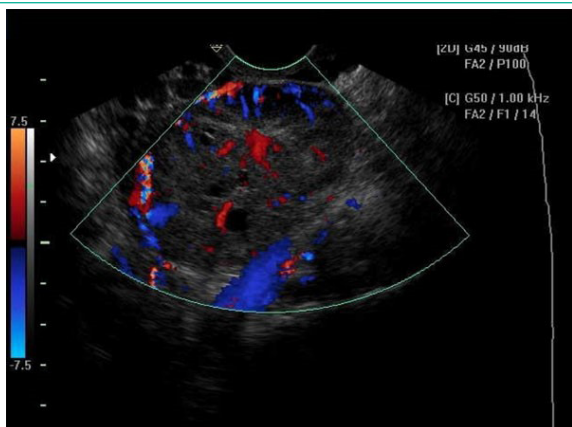


Figure 1: TVUS: solid tumor of the right ovary with high color content at color Doppler.

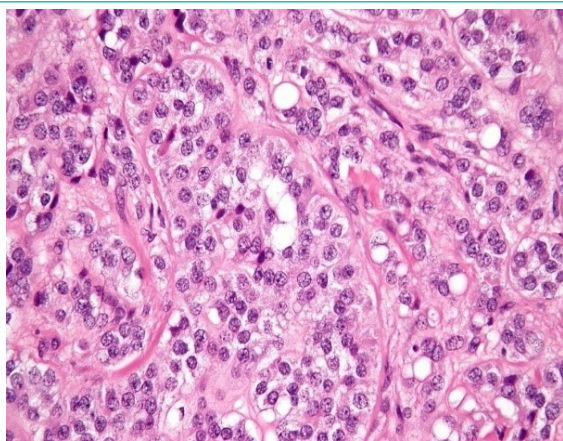


Figure 2: Sertoli cell tumor of ovarii.

para-aortic lymphadenopathy was detected. Considering the patient's fertility history, solely a right salpingo-oophorectomy was carried out. Histopathology confirmed the benign nature of the tumor, i.e., the final histopathological result revealed a well-differentiated Sertoli cell tumor of the right ovary. The immunohistochemical analysis identified cells that showed positive results for broad-spectrum cytokeratin, cytokeratin 18, inhibin, calretinin, CD56, and melanin A (Figure 2).

Discussion

Ovarian Sex Cord-Stromal Tumors (SCSTs) are a group of benign and malignant neoplasms that develop from the sex cord (e.g., Sertoli cell tumor, granulosa cell tumor), stromal cells (e.g., fibroma, thecoma, Leydig cell tumor), or both (e.g., Sertoli-Leydig cell tumor). The exact cause of these tumors is not known. Genetic mutations might play a role. Several subtypes are associated with genetic predisposition, including those observed in patients with Peutz-Jegher syndrome. SCSTs occur most often in young women (20 to 30 years old) however, the tumor can occur at any age⁶. They may be either benign or malignant. Unlike the more common epithelial ovarian cancer, malignant SCSTs are often diagnosed at an early stage; they are usually low-grade, lymph node metastases are rare, and the prognosis is good [6]. The Sertoli cells are normally located in the male reproductive glands (the testes), and they help support, protect, and nourish the spermatogenic cells. The Leydig cells, which are also located in the testes, are the primary source of androgens in males. These cells are also found in ovaries, leading to cancer in very rare cases. Ovarian SLCTs are usually unilateral, mostly confined to the ovary, and may also produce androgens. As a result, the patient may develop clinical signs of hyperan-

drogenism: a deep voice, enlarged clitoris, excessive facial hair, loss in breast size, irregular menses, or amenorrhea [6,8]. Their detection is usually incidental in women during a routine gynecological check-up or due to associated hormonal hyperactivity, which requires endocrine evaluation. Because of the complex spectrum of clinical symptoms, preoperative diagnosis of SLCTs is usually challenging and the final diagnosis is made by histopathological examination after surgery. Treatment is primarily surgical, and the choice of the method is dependent on the age and fertility history of the patient and the clinical stage and differentiation of the tumor. Fertility-sparing surgery (unilateral salpingo-oophorectomy) and standard staging procedures (with or without lymphadenectomy) are usually performed in young patients with stage I tumors. Patients unwilling to preserve fertility typically undergo bilateral salpingo-oophorectomy, total hysterectomy, and complete surgical staging. Platinum-based adjuvant chemotherapy has also been used in patients with moderately and poorly differentiated tumors, heterologous mesenchymal elements, and advanced stage [8]. We report this case because of the concurrent presence of a well-differentiated Sertoli ovarian tumor, infertility, and PJSy.

Conclusions

Findings of a solid ovarian mass in younger patients, especially those with infertility problems, should trigger suspicion for SCSTs, regardless of the symptoms of hyperandrogenism and virilization, as in the case of our patient. Because of their association with PJSy and the increased risk of gynecological and intestinal cancers, patients should be encouraged to attend routine gynecological and medical check-ups. Timely diagnosis of this syndrome and routine screening for malignancy among these patients can facilitate early-stage detection of such malignancies.

References

1. DiSaia PJ, Creasman WT. Germ cell, stromal and other ovarian tumors, *Clinical Gynecologic Oncology*. Mosby Year book. 1997; 351.
2. Young RH, Scully RE. Ovarian Sertoli-Leydig cell tumors. A clinicopathological analysis of 207 cases. *Am J Surg Pathol*. 1985; 9: 543-69.
3. Jeghers H, McKUSICK VA, Katz KH. Generalized intestine polypoidosis and melanin spots of the oral mucosa, lips and digits; a syndrome of diagnostic significance. *N Engl J Med*. 1949; 241: 1031-6.
4. Latchford AR, Phillips RK. Gastrointestinal polyps and cancer in Peutz-Jeghers syndrome: clinical aspects. *Fam Cancer*. 2011; 10: 455-61.
5. Antovska V, Trajanova M. An original risk of ovarian malignancy index and its predictive value in evaluating the nature of ovarian tumour. *SAJGO*. 2015; 7: 52-9.
6. Penick ER, Hamilton CA, Maxwell GL, Marcus CS. Germ cell, stromal, and other ovarian tumors. In: DiSaia PJ, Creasman WT, Mannel RS, McMeekin DS, Mutch DG, editors. *Clinical gynecologic oncology*. 9th ed. Philadelphia: Elsevier. 2018.
7. Gershenson DM. Management of early ovarian cancer: germ cell and sex cord-stromal tumors. *Gynecol Oncol*. 1994; 55: S62-72.
8. Smith RP: chap 158. Sertoli-Leydig cell tumor (arrhenoblastoma). In: Smith RP, editor. *Netter's obstetrics & gynecology*. 3rd ed. Philadelphia: Elsevier. 2018.