

## Clinical Image

## Idiopathic Pericardial Cyst

Calin S<sup>1</sup>, Sepesi B<sup>2</sup>, Swisher S<sup>3</sup>, Yusuf S.W<sup>4</sup> and Ferrajoli A<sup>5\*</sup>

<sup>1</sup>Department of Hematopathology, UT MD Anderson Cancer Center, Houston, TX, USA

<sup>2</sup>Department, Thoracic & Cardiovascular Surgery, UT MD Anderson Cancer Center, Houston, TX, USA

<sup>3</sup>Department, Thoracic & Cardiovascular Surgery, UT MD Anderson Cancer Center, Houston, TX, USA

<sup>4</sup>Department of Cardiology, UT MD Anderson Cancer Center, Houston, TX, USA

<sup>5</sup>Department of Leukemia, UT MD Anderson Cancer Center, Houston, TX, USA

\*Corresponding author: Ferrajoli A, Department of Leukemia, UT MD Anderson Cancer Center, Houston, TX, USA, Email: aferrajo@mdanderson.org

Received: December 08, 2014; Accepted: January 27, 2015; Published: January 29, 2015

## Clinical Image

Patient is a 52 years old man referred for treatment of chronic lymphocytic leukemia. At time of referral a routine chest radiograph showed a mass projected over the right lower chest. Computerized tomography images were obtained that demonstrated a pericardial cyst measuring 10.9 cm in the largest diameter with some compressive atelectasis of the right middle lobe (Figure A). The patient had no

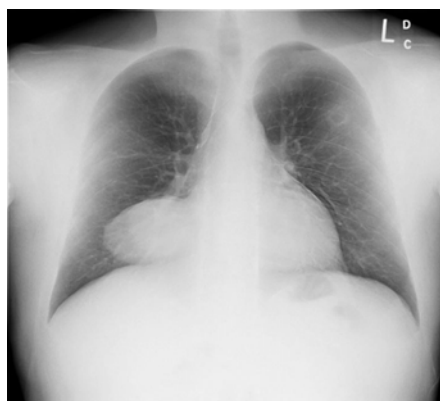

Figure A: Chest radiograph image showing a mass projected over the right lower chest.

complaints of chest pain, shortness of breath or cough. An ultrasound-guided needle aspiration yielded the diagnosis of idiopathic pericardial cyst based on fluid characteristics (transudate, with no evidence of malignant cells, acid fast bacilli, fungi or anaerobic organisms). Four years later, the patient developed recurrent episodes of retro-sternal discomfort. A surgical intervention was performed and a 13.5 cm pericardial cyst was removed by median sternotomy (Figure B, C) with resolution of the patient symptoms. Pericardial cysts are rare (1 per 100,000 individuals) congenital abnormalities.

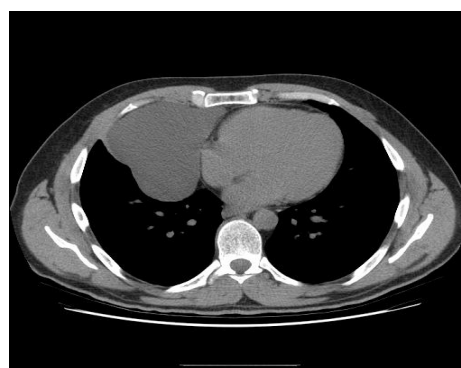


Figure B: Computerized tomography image of chest showing a large pericardial cyst and compressive atelectasis of the right middle lobe.

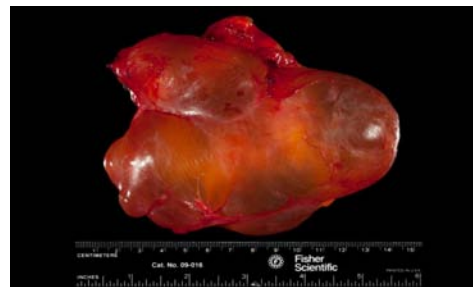

Figure C: Resected pericardial cyst (13.5 x 10.5 x 5.8 cm).