

## Case Report

# A Case of Tacrolimus-Induced Thrombotic Thrombocytopenic Purpura in a Heart-Liver En Bloc Transplant Patient

Lee R\*, Mukherji J, Maxfield B and Chow J  
Department of Anesthesiology, Loyola University Medical Center, USA

\*Corresponding author: Lee R, Department of Anesthesiology, Loyola University Medical Center, USA

Received: October 24, 2017; Accepted: November 30, 2017; Published: December 19, 2017

## Abstract

Thrombotic thrombocytopenic purpura (TTP) is a thrombotic microangiopathy (TMA) most often described as a classic pentad of microangiopathic hemolytic anemia, thrombocytopenia, neurologic involvement, renal abnormalities and fever.

**Keywords:** Thrombotic thrombocytopenic purpura; Heart-Liver En Bloc transplant; NASH cirrhosis

## Introduction

It can present primarily, due to a deficiency of a disintegrin and metalloproteinase with a thrombospondin type 1 motif, member 13 (ADAMTS13), or secondary to pregnancy, solid organ or bone marrow transplant, malignancy, autoimmune or medications [1]. Cases of TMA secondary to antirejection medications such as calcineurin inhibitors after solid organ transplantation has been reported [2] and here we describe a case of TTP secondary to tacrolimus.

## Case Presentation

A 56 year old female with history of NASH (nonalcoholic steatohepatitis) cirrhosis, ischemic cardiomyopathy and heart failure with reduced ejection fraction who had left ventricular assist device placed with a plan for bridge to transplant (BTT), presented for an orthotopic heart and liver transplant. Her intraoperative and immediate postoperative period was largely uneventful and she was started on tacrolimus for antirejection on POD#4. On POD#9, the patient was found to have an altered mental status, fever and leukocytosis. Pancultures and imaging revealed no signs of active infection. She was continued on tacrolimus and on POD#11, she was noted to have decreased UOP refractory to diuretics. Her creatinine was noted to be elevated as well as worsening thrombocytopenia. Peripheral blood smear revealed schistocytes (Figure 1). Lactate dehydrogenase (LDH) was noted to be elevated at 535 IU/L (normal 98-192) and haptoglobin decreased at <15 mg/dL (normal 36-195), consistent with hemolysis. There was a clinical suspicion of TTP on POD#16, her platelet count dropped even further to 25 k/UL (normal 150-400), for which she underwent plasmapheresis. On POD#17, she underwent a renal biopsy which revealed cortical necrosis as well as microthrombi, consistent with a diagnosis of TMA, likely TTP. On POD#18, tacrolimus was discontinued and she was started on cyclosporine. She underwent a renal ultrasound which revealed no flow to the left kidney. ADAMTS13 activity was found to be mildly below normal limits at 62% (normal 67%). A diagnosis of tacrolimus induced TTP was made given her lab findings, pathology, and improving clinical picture once tacrolimus was discontinued.

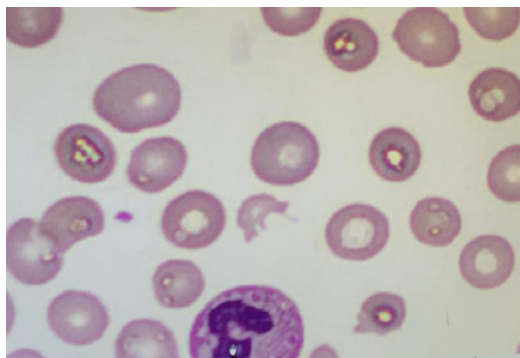
## Discussion

TMA has been seen in solid organ and bone marrow transplant patients with tacrolimus therapy. It is more commonly seen after renal transplant, although cases in lung, heart and liver transplants have been reported. It is more commonly seen in female recipients and its incidence appears independent of dose and duration of tacrolimus therapy. If left untreated, tacrolimus induced TMA can have significant mortality. In most cases, cessation of tacrolimus with substitution of cyclosporine and use of plasmapheresis is an effective treatment, often with complete recovery. Cases of TMA secondary to cyclosporine have also been reported in renal transplant patients, although the incidence is rare [3].

The mechanism of acquired TTP can be explained by deficiency of von-Willebrand factor-cleaving (VWFPC) also known by the acronym ADAMTS13. ADAMTS13 is a zinc-containing metalloprotease enzyme that cleaves ultra large von-Willebrand factor (vWF) multimers into monomers. A procoagulant state arises, leading to multi-organ ischemia from deficient ADAMTS13 activity and accumulation of ultra large vWF multimers in the circulation.

Not all the features of the classic pentad of TTP (microangiopathic hemolytic anemia, thrombocytopenia, fever, neurological manifestations, and renal involvement) may be present in patients with acquired TTP. A majority of patients, up to 60%, will only demonstrate partial features of TTP [4]. An earlier diagnosis can be made by measuring ADAMTS13 activity and anti-ADAMTS titers in patients when there is a strong clinical suspicion of TTP [5]. It is important that the diagnosis be made early so that prompt treatment of TTP can be initiated. The initial treatment of choice is therapeutic plasma exchange for acquired TTP with demonstrable autoantibodies. Immunomodulatory therapies, including corticosteroids, rituximab, vincristine, cyclosporine, cyclophosphamide, should be considered to eliminate autoantibodies for a sustained remission (Table 1) [6].

The clinical presentation in our patient was initially partial with evidence of persistent thrombocytopenia and encephalopathic changes. Our patient's altered mental status progressively resolved with cessation of tacrolimus and initiation of plasmapheresis. Renal



**Figure 1:** Schistocytes seen on patient's peripheral blood smear.

**Table 1:** ICU and Transplant Drugs with known association with TTP/TMA [4,7,8].

Calcineurin Inhibitors:	Tacrolimus, cyclosporine
Antimicrobials:	Penicillins, penicillimide, rifampin, metronidazole
Antiplatelet agents:	Clopidigrel, ticlopidine
Antipsychotics:	Quetiapine

involvement was demonstrated by her decreasing renal function and microthrombi on biopsy. Microvascular thrombosis can lead to platelet aggregation and hemolytic anemia, as demonstrated by her thrombocytopenia, schistocytes on blood smear, low haptoglobin and elevated LDH. ADAMTS13 activity was slightly below normal, which is suggestive of secondary TTP diagnosis rather than primary.

The clinical course and manifestations of acquired TTP are variable and it is important that the transplant surgeon and critical care physician caring for solid organ transplant patients are familiar with the diagnosis and management of this rare, but potentially life-threatening hematologic disorder.

**References**

1. Rogers HJ, Allen C, Lichtin AE. Thrombotic thrombocytopenic purpura: The role of ADAMTS13. *Cleve Clin J Med.* 2016; 83: 597-603.
2. Nwaba A, MacQuillan G, Adams LA, Garas G, Delriviere L, Augustson B, et al. Tacrolimus-induced thrombotic microangiopathy in orthotopic liver transplant patients: case series of four patients. *Intern Med J* 2013; 43: 328-333.
3. Boyer NL, Niven A, Edelman J. Tacrolimus-associated thrombotic microangiopathy in a lung transplant recipient. *BMJ Case Rep.* 2013; 2013: 007351.
4. Maramattom BV, Patil R, Thomas P, Upendran B. Tacrolimus associated thrombotic thrombocytopenic purpura (TTP) and stroke in the young. *Ann Indian Acad Neurol.* 2015; 18: 126-127.
5. Peyvandi F, Palla R, Lotta LA, Mackie I, Scully MA, Machin SJ. ADAMTS-13 assays in thrombotic thrombocytopenic purpura. *J Thromb Haemost.* 2010; 8: 631-640.
6. Saha M, McDaniel JK, Zheng XL. Thrombotic thrombocytopenic purpura: pathogenesis, diagnosis and potential novel therapeutics. *J Thromb Haemost.* 2017; 15: 1889-1900.
7. George JN, Nester CM. Syndromes of thrombotic microangiopathy. *N Engl J Med.* 2014; 371: 654-666.
8. Al-Nouri ZL, Reese JA, Terrell DR, Vesely SK, George JN. Drug-induced thrombotic microangiopathy: a systematic review of published reports. *Blood;* 125: 616-618.