

Case Report

Fenbendazole as a Treatment for Diffuse Large B-Cell Lymphoma

Abughanimeh O^{1*}, Evans T² and Kallam A¹

¹Department of Hematology/Oncology, University of Nebraska Medical Center/Fred & Pamela Buffett Cancer Center, USA

²Department of Internal Medicine, University of Nebraska Medical Center, USA

*Corresponding author: Abughanimeh O, Department of Hematology/Oncology, University of Nebraska Medical Center/Fred & Pamela Buffett Cancer Center, 986840 Nebraska Medical Center, Omaha, NE, 68498, USA

Received: December 24, 2019; Accepted: February 18, 2020; Published: February 25, 2020

Abstract

Diffuse Large B-Cell Lymphoma (DLBCL) is the most common type of Non-Hodgkin Lymphoma (NHL) [1]. It is an aggressive disease where patients present with constitutional symptoms and rapidly enlarging lymphadenopathy, requiring urgent treatment [1]. Fenbendazole is a broad-spectrum anthelmintic that is commonly used to treat animals' gastrointestinal parasitic infections [2,3]. Herein, we present a case of stage IVa DLBCL where patient declined chemotherapy, instead he took Fenbendazole which resulted in regression of his DLBCL.

Keywords: Diffuse large B-cell lymphoma; DLBCL; Fenbendazole

Abbreviations

DLBCL: Diffuse Large B-Cell Lymphoma; NHL: Non-Hodgkin Lymphoma; EGD: Esophagogastroduodenoscopy; FISH: Fluorescence in Situ Hybridization; PET/CT: Positron Emission Tomography/Computed Tomography

Case Presentation

An 83-year-old male, presented with heartburn, trouble swallowing, and fatigue. An Esophagogastroduodenoscopy (EGD) revealed superficial duodenal ulcer which was biopsied and revealed DLBCL, GCB subtype. Fluorescence in Situ Hybridization (FISH) was negative for c-MYC, BCL2 and BCL6. A Positron Emission Tomography/Computed Tomography (PET/CT) scan revealed hyper-metabolic activity in the distal gastric antrum, proximal duodenum, peri-aortic lymph node, and pulmonary nodules. Patient was staged as stage Iva, and was offered chemotherapy, but he declined treatment due to side effect profile.

He started to take fenbendazole 1g daily based on self-research (used to take between 1-6 tabs daily based on his symptoms). After 6 months, he cut down fenbendazole to 1-3 tabs daily due to peripheral neuropathy. He presented to his primary care physician who obtained a repeated CT scan which revealed smaller mediastinal lymph nodes. After 2 months, he decided to follow with oncology, so he had repeated PET/CT scan which revealed improved lymphadenopathy from prior scans (Figure 1).

In the next 3 months, he continued to taper down fenbendazole and reached 3 pills weekly. A repeated PET/CT scan revealed interval improvement in his disease with no new lesion seen (Figure 2).

Discussion

Fenbendazole is a broad-spectrum benzimidazole, it is an anthelmintic drug that is commonly used to treat animals' parasitic infections [2,3]. Fenbendazole acts on parasites by binding and disrupting tubulin microtubules [2]. Microtubules play a crucial role in cell division, intracellular trafficking, motility and modulating

cellular shape. As a result, drugs that target microtubules have been used widely as a cancer treatment such as Vinca alkaloids, paclitaxel, and others [2,3].

Several studies were done to evaluate the anti-neoplastic effect of fenbendazole. Dogra et al, [3] performed a study on mice which demonstrated anti-tumor effect of fenbendazole through disruption of microtubule dynamics, p53 activation and modulation of different cellular pathways' genes. Moreover, Bai et al, [4] reported that fenbendazole had also some anti-brain tumor activity in mice [4]. Gao et al, [5] performed a study on 20 SCID mice which were exposed to 4 different diets: standard diet, diet plus vitamins, diet plus fenbendazole, and diet plus both vitamins and fenbendazole. All mice had implantation of lymphoma cells 2 weeks after starting the diet, this study showed that only the group that had both vitamins and fenbendazole experienced a significant tumor growth inhibition.

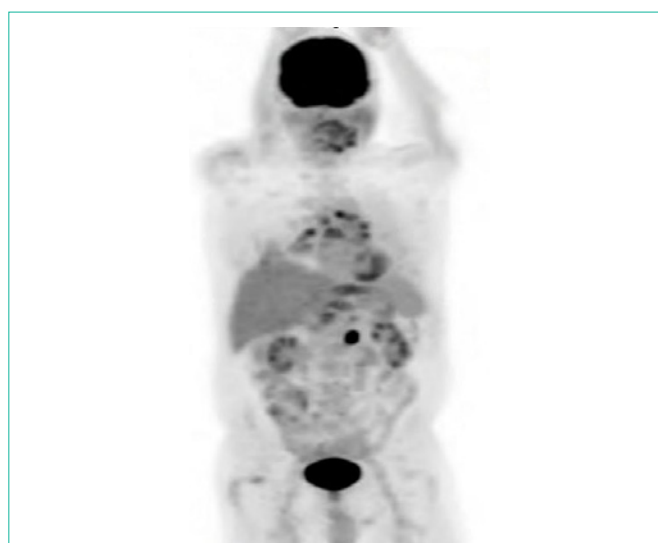


Figure 1: In the next 3 months, he continued to taper down fenbendazole and reached 3 pills weekly. A repeated PET/CT scan revealed interval improvement in his disease with no new lesion seen (Figure 2).

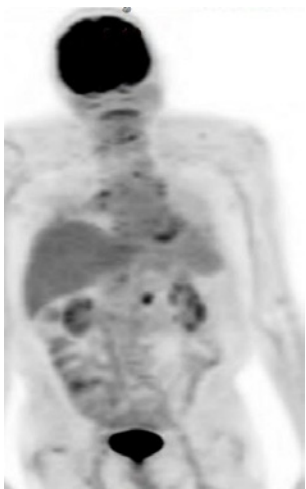


Figure 2:

On the other hand, Duan et al, [2] performed a study to evaluate fenbendazole effect on EMT6 mice mammary tumor cells *in vitro* and solid tumors in mice *in vivo*. Their study showed that fenbendazole were toxic to EMT6 cells *in vitro*, though it did not alter the growth of EMT6 tumors. As a result, the study did not provide any evidence that fenbendazole can be used as a cancer therapy [2].

In our case, it is clearly that the patient had a regression in his disease, which is thought to be due to fenbendazole. Whether it's related to Fenbendazole or other factors still unknown. Further studies are required to understand the anti-tumor effect of fenbendazole.

References

1. Liu Y, Barta SK. Diffuse large B-cell lymphoma: 2019 update on diagnosis, risk stratification, and treatment. *Am J Hematol*. 2019; 94: 604-616.
2. Duan Q, Liu Y, Rockwell S. Fenbendazole as a potential anticancer drug. *Anticancer Res*. 2013; 33: 355-362.
3. Dogra N, Kumar A, Mukhopadhyay T. Fenbendazole acts as a moderate microtubule destabilizing agent and causes cancer cell death by modulating multiple cellular pathways. *Sci Rep*. 2018; 8: 11926.
4. Bai RY, Staedtke V, Aprhys CM, Gallia GL, Riggins GJ. Antiparasitic mebendazole shows survival benefit in 2 preclinical models of glioblastoma multiforme. *Neuro Oncol*. 2011; 13: 974-982.
5. Gao P, Dang CV, Watson J. Unexpected antitumorigenic effect of fenbendazole when combined with supplementary vitamins. *J Am Assoc Lab Anim Sci*. 2008; 47: 37-40.