

## Short Communication

# Fulminant Community-Acquired Meningitis Caused by Streptococcus Pneumoniae

Rattotti S<sup>1\*</sup> and Merati G<sup>2</sup><sup>1</sup>Division of Hematology, Fondazione IRCCS Policlinico San Matteo, Italy<sup>2</sup>Department of Molecular Medicine, University of Pavia, Italy

\*Corresponding author: Sara Rattotti, Division of Hematology, Fondazione IRCCS Policlinico San Matteo, p.le Golgi 19, 27100 - Pavia, Italy

Received: May 03, 2020; Accepted: June 17, 2020;

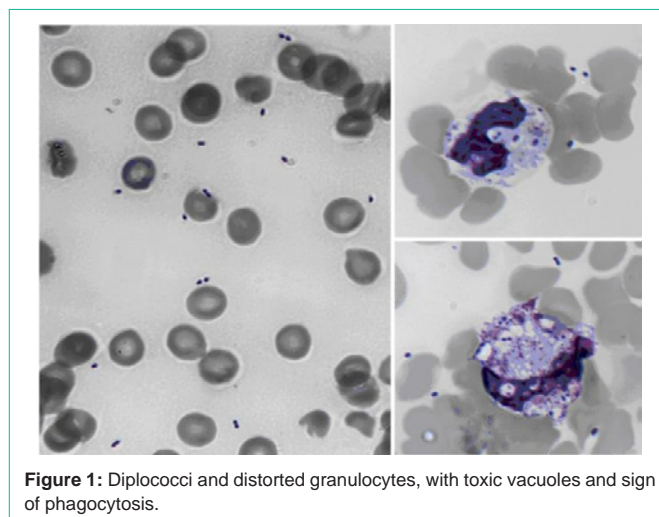
Published: June 24, 2020

## Short Communication

A 62-years-old woman presented to Emergency Department for fever, vomiting, dyspnea, lethargy. Physical examination revealed cyanosis and cutaneous purpura.

A blood count showed a severe pancytopenia (Hemoglobin, 3,7 g/dl; Leukocytes,  $0,8 \times 10^9/L$ ; Platelets,  $28 \times 10^9/L$ ). Peripheral blood smear demonstrated a large number of Diplococci; same distorted granulocytes, containing toxic vacuoles and intracellular structure, were suggestive for phagocytized cocci. Biochemistry revealed drastic hypoglycemia ( $< 4$  mg/dl) and acute renal failure (serum creatinine 9,1 mg/dl, creatinine-clearance 4 ml/min/1,73 m<sup>2</sup>). Procalcitonin was very high, 187 ng/ml (n.v.  $< 0,5$ ), as serum creatine-phosphokinase level, 1224 mU/ml (n. v. 34-145). Chest radiography was normal. She had no history of previous onco-hematological or immunosuppressive disease. Blood cultures confirmed a disseminated infection caused by Streptococcus Pneumoniae, with a dramatic meningitis associated to "purpura fulminans" and acute renal failure with rhabdomyolysis. Although intensive treatments, the patient died less than 3 hours after (Figure 1).

The finding of bacteria in peripheral blood smear is unusual, but it could be crucial to support an early diagnosis and treatment



**Figure 1:** Diplococci and distorted granulocytes, with toxic vacuoles and sign of phagocytosis.

of septicemia, also ahead of a lumbar puncture, in particular in the setting of "community-acquired meningitis" [1-2]. The severe prognosis of this condition confirmed the importance of extensive Pneumococcal vaccination [3]. Both authors approved the final version of the manuscript, declare no conflict of interest and no funding source.

## References

1. Van de Beek D, de Gans J, Tunkel AR. Community-acquired bacterial meningitis in adults. *N Engl J Med.* 2006; 354: 44-53.
2. Van de Beek D, Cabellos C, Dzupova O. ESCMID guideline: diagnosis and treatment of acute bacterial meningitis. *Clin Microbiol Infect.* 2016; 22: 37-62.
3. Costerus JM, Brouwer MC, Bijlsma MW, van de Beek D. Community-acquired bacterial meningitis. *Curr Opin Infect Dis.* 2017; 30: 135-141.