

Special Article - Nephrology & Dialysis

Purpuric Rash after Surgical Thrombectomy of Trombosed Graft

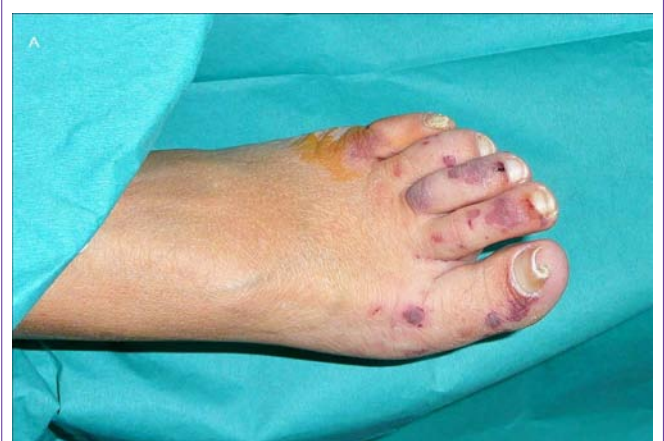Fragoso A*, Pimentel A, Jerónimo T, Morgado E, Silva AP and Neves P

Department of Nephrology, Centro Hospitalar do Algarve, Portugal

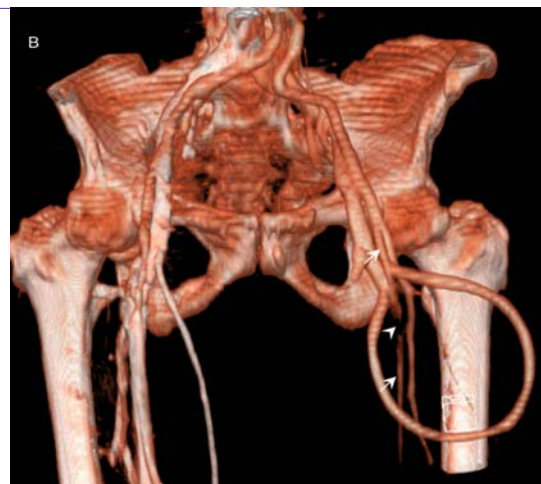
***Corresponding author:** Fragoso A, Department of Nephrology, Hospital de Faro, 8135-125 Faro, Portugal, Tel: 351-965156065; Email: andrefragoso@iol.pt

Received: September 18, 2014; **Accepted:** September 21, 2014; **Published:** September 24, 2014

A 42-years-old stage V CKD female patient presented with a sudden purpuric rash involving the left knee and the toes of her left foot (Panel A). She also reported mild paresthesias and mild pain in the anterior thigh. When compared with the other foot a slight reduction in temperature and mild peripheral cyanosis were evident. The patient had recently undergone surgical thrombectomy of a thrombosed graft previously placed on her left thigh. Acute ischemia of the territory supplied by the popliteal and posterior tibial arteries was ruled out by Doppler ultrasound. Aorto-iliac CT-angiography showed an embolus (Panel B, arrowhead) partially occluding the lumen of the left femoral artery (Panel B, arrow) just below the anastomosis to the vascular graft. All complaints and physical signs resolved spontaneously over the next 15 days with the skin lesions being replaced by a post-inflammatory hyperpigmentation.



Panel A: Purpuric rash involving the toes of the left foot with mild peripheral cyanosis.



Panel B: Aortic-iliac CT-angiography showing an embolus (arrowhead) partially occluding the lumen of the left femoral artery (white arrow) just below the anastomosis to the vascular graft.