

Research Article

Clinical Investigations of Percutaneous Vertebroplasty Combined with Intensity-modulated Radiotherapy for Patients with Spinal Metastases

Chen X^{1#}, Xie XQ^{2#}, Li WM³, Liao ZY^{1*}, Wu DB⁴
and Wang F^{1*}

¹Department of Medical Oncology, Sichuan University, China

²Department of Critical Care Medicine, Sichuan University, China

³Sichuan University, West China Hospital, PR China

⁴Cancer Hospital, Ansteel Group Hospital, PR China

[#]These authors contributed equally to this article

*Corresponding author: Feng Wang, Department of Medical Oncology, Cancer Center, West China Hospital, West China Medical School, Sichuan University, No. 37, Guo Xue Xiang, Chengdu 610041, Sichuan Province, China

Zheng Ying Liao, Department of Critical Care Medicine, West China Hospital, Sichuan University, Chengdu 610041, Sichuan Province, China

Received: March 15, 2021; Accepted: March 29, 2021;

Published: April 05, 2021

Introduction

Spinal metastasis is a common complication of cancer. It can cause severe spinal pain, pathological vertebral fractures, spinal cord compression, paraplegia and so on. They all lead a poor prognosis [1]. Now days Percutaneous Vertebroplasty (PVP) and radiotherapy are the most used in ensuring relief from discomfort at the end of life expectancy [2]. Radiotherapy (RT) can provide successful palliation of painful bone metastasis in 50-80 % of patients [3]. IMRT makes it possible to deliver optimal radiation doses safely [4]. PVP is a recently developed treatment for spinal metastases. It appeared to be an alternative method to treat painful spine metastases [5]. But few studies report on the clinical observation of PVP combined with IMRT in the treatment of metastatic lesions of the spine. In this article, feasibility and clinical effects were discussed in the patients with spinal metastases who were treated with percutaneous vertebroplasty combined with intensity-modulated radiotherapy.

Material and Method

Patients

It is a retrospective study. We collected 7 patients from West China Hospital (2010-2012), and record the medical characters of these patients. They were all diagnosed as malignant tumor with spinal metastases. The primary tumor sites are laryngeal, nasopharyngeal, liver, and lung. Two of the patients are unknown primary focal. The mean age of the study participants was 55.8 years (range: 32-68 years). PVP combined with IMRT are used in these spinal metastases sites. The most commonly involved spine levels are between C2 and L3. Clinical and pathological characteristics of the cases are showed in

Abstract

Percutaneous Vertebroplasty (PVP) or radiotherapy are used in tumor with bone metastasis. However, The treatment of vertebral metastasis tumor with PVP combined with Intensity-Modulated Radiotherapy (IMRT) are rarely reported. The effectiveness and feasibility of these treatment procedures are initially observed in the article. We retrospectively analyzed the clinical features of 7 patients with vertebral metastases. They all received PVP, and then IMRT (6 MV-X linear at a dose of 40-60Gy). Technical success of PVP was achieved in all patients, and all of them completed the radiotherapy plan successfully. There are no severe complications were observed. They all got pain relief and no pain or fracture were found after PVP combined with IMRT. PVP combined with IMRT seems to be an effective and feasible means to improve the quality of life of patients with tumor vertebral metastasis.

Keywords: Percutaneous vertebroplasty; Intensity-modulated radiotherapy; Spinal metastases

Table 1.

Treatment procedure

All patients underwent, computed tomograph, magnetic resonance imaging, or bone scanning for evaluation of metastasis lesions. The indication for PVP was an unstable or painful metastatic tumor. Specific methods for PVP: cervical puncture in the supine position, thoracolumbar prone position. Regular disinfection shop towels, local infiltration anesthesia. The anterior lateral approach is commonly used in cervical spine surgery, and the thoracic and lumbar spine can be operated by pedicle of vertebral arch or the posterior lateral approach under X-ray. 5-10cm bone cement were used in one vertebral body. Once the bone cement is found to be leaking into the spinal canal, intervertebral foramen, or venous plexus, the injection should be stopped immediately. The IMRT was performed in the vertebral metastasis area after patients undergoing PVP for approximately 30 days using an 6 MV-X linear at a dose of

Table 1: Patient characteristics, PVP and IMRT.

| Case No. | Age | Sex | Primary Cancer | PVP Levels | Follow-up (mos) | Comment |
|----------|-----|-----|------------------------------|------------|-----------------|---------|
| 1 | 66 | M | Laryngeal cancer | C2-3 | 40 | dead |
| 2 | 45 | M | Nasopharyngeal cancer | C5 | 73 | alive |
| 3 | 68 | F | Metastasis of unknown origin | L1 | 59 | alive |
| 4 | 65 | F | Liver Cancer | L1-3 | 3 | dead |
| 5 | 32 | M | Metastasis of unknown origin | C2-3 | 20 | dead |
| 6 | 50 | M | Lung Cancer | L1-2 | 46 | alive |
| 7 | 65 | F | Lung Cancer | T L | 24 | dead |

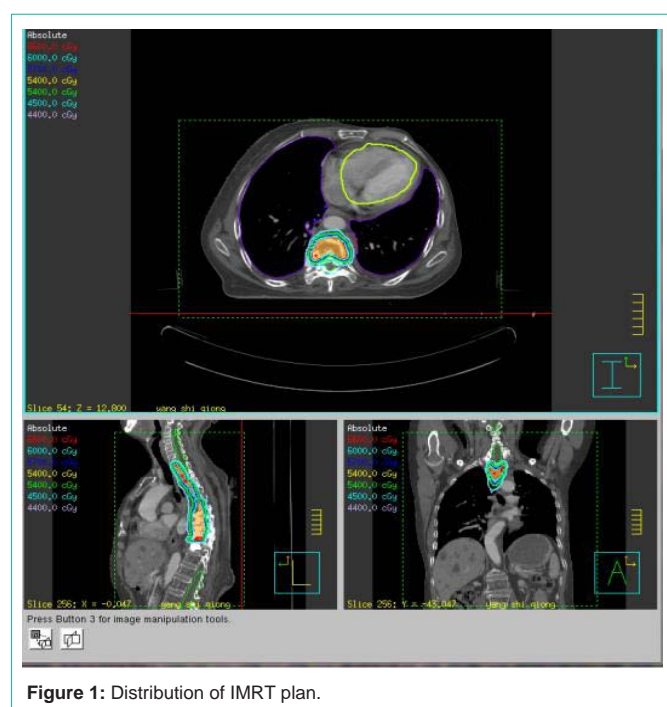


Figure 1: Distribution of IMRT plan.

40-60Gy. The Gross Tumor Volume (GTV) of a tumor was defined as the volume of gross visible tumor plus margins of approximately 2mm with a total dose 40-60Gy. The Clinical Tumor Volume (CTV) was defined as the GTV plus a margin (35-50Gy). The planning target volume was defined as the CTV plus 2 mm margins (30-50Gy) Distribution of intensity-modulated radiation therapy plan was showed in Figure 1.

Results

All the patients complete the treatment procedures. 13 vertebral bodies were punctured, and the success rate of PVP puncture is 100%. There are no severe complications were observed, such as bone marrow mud leakage, Spinal cord injury, local pain and so on. 7 patients all received IMRT (40-60Gy/20-30f). The process is successful, and the patients can endure the exposure during the position and limb braking requirements. Cancer pain were relieved in all the patients in 6-72h after PVP. The total effective rate is 100%. No pain or fracture were found after PVP combined with IMRT. Three patients are still alive until now.

Discussion

Spinal metastases are becoming increasingly common because of the rising incidence of cancer and the improved survival of cancer patients [6,7]. At least 40% of patients with advanced cancer will have spinal involvement during the course of their disease [16]. The treatment of painful vertebral metastases is a major target [10,11]. The maintenance of spinal stability, reduction of pain, and prevention of neurological deterioration can affect a patient's quality of life. The treatment methods of spinal metastatic tumors include: double phosphate drugs, analgesic drugs, chemotherapy (including hormone therapy), radiation therapy, percutaneous vertebral angioplasty, percutaneous radiofrequency ablation, decompression surgery therapy, radionuclide therapy, etc. Now days radiation therapy and

PVP are commonly used for spinal metastases. Under the treatment of PVP, 80% patients can achieve significant pain relief within 1 hours, and the analgesic effect is more than 75% [13]. Radiotherapy (RT) can provide successful palliation of painful bone metastasis in 50-80 % of patients [14]. While IMRT are particularly well suited for the treatment of spinal bone metastases when they are localized or require re-irradiation, and may provide superior tumor control [15].

There are article compared the efficacy of External Radiotherapy (ERT) and PVP for spinal metastasis, and showed that ERT combined with PVP achieved pain remission in 84.8% of the patients, which was higher than ERT (72.5%) or PVP (76.3%) alone [12]. Yi Li, et al has evaluate the safety and efficacy of PVP combined with IMRT for vertebrae metastatic lesions of patients with Non-Small-Cell Lung Cancer (NSCLC), They used the Visual Analog Scale (VAS) to assess the degree of pain, the mean VAS score and the activities of daily living, evaluation showed that the patients had a significantly high life quality after the combined approach ($P < 0.05$) [8]. JEE-SOO JANG et al indicated that the mean VAS pain score was reduced from 8.2 to 3 under the treatment of PVP combined with RT [9]. In our series, all the patients got pain relief and no pain or fracture were found after PVP combined with IMRT. PVP combined with IMRT seems to be an effective and feasible means to improve the quality of life of patients with tumor vertebral metastasis.

Conclusion

Percutaneous vertebroplasty combined with intensity-modulated radiotherapy can provide pain relief and stability for cancer patients with spinal metastases.

References

- Bartels RH, van der Linden YM, van der Graaf WT. Spinal extradural metastasis: review of current treatment options. *CA Cancer J Clin.* 2008; 58: 245-259.
- Huang M, Hong ZHU, Taiguo LIU, Dandan CUI, Huang Y. Comparison of external radiotherapy and percutaneous vertebroplasty for spinal metastasis. *Asia-Pacif C Journal of Clinical Oncology.* 2016; 12: e201-e208.
- Chow E, Harris K, Fan G, Tsao M, Sze WM. Palliative radiotherapy trials for bone metastases: a systematic review. *J Clin Oncol.* 2007; 25:1423-1436.
- Ejima Y, Matsuo Y, Sasaki R. The current status and future of radiotherapy for spinal bone metastases. *J Orthop Sci.* 2015; 20: 585-592.
- Xie P, Zhao Y, Li G. Efficacy of percutaneous vertebroplasty in patients with painful vertebral metastases: A retrospective study in 47 cases. *Clin Neurol Neurosurg.* 2015; 138: 157-161.
- Lo SS, Sahgal A, Wang JZ, Mayr NA, Sloan A, Mendel E, et al. Stereotactic body radiation therapy for spinal metastases. *Discov Med* 2010; 9: 289-296.
- Sheehan JP, Jagannathan J. Review of spinal radiosurgery: a minimally invasive approach for the treatment of spinal and paraspinal metastases. *Neurosurg Focus.* 2008; 25: E18.
- Li Y, Qing Y, Zhang Z, Li M, Xie J, Wang G, et al. Clinical efficacy of percutaneous vertebroplasty combined with intensity-modulated radiotherapy for spinal metastases in patients with NSCLC. *Onco Targets Ther.* 2015; 8: 2139-2145.
- Jang JS, Lee SH. Efficacy of percutaneous vertebroplasty combined with radiotherapy in osteolytic metastatic spinal tumors. *J Neurosurg Spine.* 2005; 2: 243-248.
- Lo SS, Sahgal A, Wang JZ, Mayr NA, Sloan A, Mendel E, et al. Stereotactic body radiation therapy for spinal metastases. *Discov Med.* 2010; 9: 289-296.
- Sheehan JP, Jagannathan J. Review of spinal radiosurgery: a minimally

- invasive approach for the treatment of spinal and paraspinal metastases. *Neurosurg Focus* 2008; 25: E18.
12. Huang M, Hong ZHU, Taiguo LIU, Dandan CUI, Huang Y. Comparison of external radiotherapy and percutaneous vertebroplasty for spinal metastasis. *Asia-Pacific Journal of Clinical Oncology*. 2016; 12: e201-e208.
 13. Barr JD, Barr MS, Lerricy TJ, McCann RM. Percutaneous vertebroplasty for pain relief and spinal stabilization. *Spine*. 2000; 25: 923-928.
 14. Chow E, Harris K, Fan G, Tsao M, Sze WM. Palliative radiotherapy trials for bone metastases: a systematic review. *J Clin Oncol*. 2007; 25:1423-1436.
 15. Ejima Y, Matsuo Y, Sasaki R. The current status and future of radiotherapy for spinal bone metastases. *J Orthop Sci*. 2015; 20: 585-592.
 16. Bohm P, Huber J. The surgical treatment of bony metastases of the spine and limbs. *J Bone Joint Surg Br*. 2002; 84: 521-529.