

Case Report

Ab Interno Trabeculostomy – A Case Study on Advanced Open-Angle Glaucoma

Strzalkowska A*, Strzalkowski P, Gärtner P, Spaniol K and Geerling G

Department of Ophthalmology, Medical Faculty and University Hospital Düsseldorf, Heinrich-Heine-University, Düsseldorf, Germany

*Corresponding author: Alicja Strzalkowska, Department of Ophthalmology, Medical Faculty and University Hospital Düsseldorf, Heinrich-Heine-University, Düsseldorf, Moorenstrasse 5, 20225 Duesseldorf, Germany

Email: Alicja.Strzalkowska@med.uni-duesseldorf.de

Received: January 25, 2025; Accepted: February 13, 2025; Published: February 17, 2025

Abstract

Introduction: Minimally invasive glaucoma surgeries (MIGS) have become essential in treating glaucoma, particularly in mild to moderate cases, due to their proven effectiveness and safety in clinical trials. A recent advancement in this field is excimer laser trabeculostomy (ELIOS Vision), a procedure that does not require stents in the anterior chamber angle. The purpose of the study was to evaluate the efficacy and safety of ab interno trabeculostomy using the excimer laser (ELIOS) in patients with advanced open-angle glaucoma (OAG).

Case Presentations: This is a retrospective case study of the first five OAG patients and six eye, who underwent ELIOS surgery at the Department of Ophthalmology, University Eye Hospital, Germany. Demographic data, including age, sex, number of glaucoma medications, intraocular pressure (IOP) before and after the operation, complications, and reoperations were analyzed.

A total of six eyes from five subjects - 4 men and one woman, with an average age of 79.2 ± 9 years - were included in this study. All patients had OAG, five eyes were pseudophakic. ELIOS was performed as a stand-alone procedure. Preoperatively, the average visual acuity was 0.6 ± 0.4 (logMAR), the IOP was 20.7 ± 5.1 mmHg, the number of glaucoma medication was 3.3 ± 1.2 and mean deviation (MD) value in the visual field was 23.6 ± 1.6 dB for the entire group. Postoperatively, IOP measured 14.0 ± 5.1 mmHg at 1 week, 17.3 ± 4.9 mmHg at 1 month, 14.2 ± 3.6 mmHg at 3 months and 13.2 ± 3.5 mmHg at 6 months. The number of glaucoma medications was reduced to 1.2 ± 1.8 at 1 week, 1.2 ± 1.8 at 1 month, 2.2 ± 1.8 at 3 months and 2.8 ± 1.2 mmHg at 6 months. One patient experienced a hyphema postoperatively.

Conclusion: According to this study, ELIOS was effective in reducing intraocular pressure and the number of glaucoma medications in patients with advanced open-angle glaucoma. However, larger real-world and long-term data are still needed to confirm these findings.

Keywords: Glaucoma; Surgery; MIGS; Trabeculostomy; Ab interno procedure

Introduction

Minimally invasive glaucoma surgeries, often known as micro-incisional glaucoma surgery (MIGS), have become a crucial part of glaucoma treatment due to their proven effectiveness and safety in randomized clinical trials. However, the patients involved in these studies do not always reflect those typically seen in routine clinical practice [1, which e.g. include patients with more advanced glaucoma. In real life patients are often older and have previously undergone multiple surgeries, suffer from severe glaucoma damage, and have intraocular pressure (IOP) significantly higher than 21 mmHg. Nevertheless, their central visual acuity is often still satisfactory.

This raises several questions: What type of glaucoma treatment would be most beneficial for these patients? Should an intervention only be used following failure of medical treatment? Although glaucoma surgery is generally a safe and successful intervention, it carries a small risk of severe visual loss, which is considered by many clinicians [2]. A recent survey of consultants' opinions in the UK has suggested that the main reason for not advocating primary surgery is

the concern regarding surgical complications. Interestingly, however, a large proportion indicated that they would be willing to change their practice should evidence support primary surgery.

Should we opt in advanced glaucoma cases directly for a trabeculectomy or drainage-implant, as suggested by National Institute for Clinical Excellence in its clinical guidelines [3], which could lead to wipe-out [4], potentially worsening the patient's quality of life and requiring frequent postoperative follow-ups? Alternatively, should one consider cyclophotocoagulation with the understanding that it may need to be repeated if the initial effect diminishes? Also, MIGS, though unconventional, might be a rational approach as these techniques offer reasonable reduction of IOP and glaucoma medication, reducing the need for constant ophthalmologist visits.

In recent years, laser technology, including excimer laser, has gained increasing importance in the treatment of glaucoma. This method has already demonstrated positive effects in real-world studies

[5]. Currently, it is being represented by ELIOS Vision (Germering, Germany). Unlike other MIGS, this technique does not require the placement of a stent in the anterior chamber angle. To the best of our knowledge, this is the first real-world case series examining early postoperative outcomes in advanced open-angle glaucoma, treated with ELIOS.

Case Presentation

A retrospective analysis of the first 6 OAG cases who underwent an ELIOS surgery at the Department of Ophthalmology, University Eye Hospital, Germany. Demographic data, including age, sex, number of glaucoma medications, intraocular pressure (IOP) before and up to six months after surgery, complications, and reoperations were analyzed. All eyes were analyzed by optical coherence tomography (OCT) and retinal nerve fiber layer thickness was measured. This study followed the ethical standards of the Declaration of Helsinki. The study was approved by the Ethics Committee of the Faculty of Medicine of HHU Düsseldorf, No. 2024-3075.

Excimer Laser Trabeculostomy

For this procedure a 308-nm xenon chloride excimer laser is used to deliver energy via a fiber optic probe (shown in Figure 1) to ablate sections of the trabecular meshwork (TM) and create macrochannels to Schlemm's canal via an intracameral approach. Unlike selective laser trabeculoplasty, ELT utilizes a "cold" laser, which theoretically reduces the risk of thermal damage [6]. This laser treatment can be performed with phacoemulsification or as a stand-alone procedure.

Our ELT was performed in all cases as a stand-alone procedure as follows:

A temporal paracentesis was done. Viscoelastic was injected into the anterior chamber. The microscope was repositioned (30°). The head was tilted. The Elios probe was introduced in the anterior chamber. 10 spots were performed in the nasal quadrant within the trabecular meshwork. A slight reflux bleeding served as a sign of success. The viscoelastic was removed.

Statistics

Statistical analysis was performed using GraphPad Prism10 (Version 10.3.1 (464), GraphPad Software, San Diego, USA) for Mac. For statistical analysis, BCVA was converted in logarithm of the minimum angle of resolution (logMAR) scale. Categorical variables were presented as absolute and relative frequencies, whereas mean and standard deviation were computed for approximately normal-distributed continuous variables.

Characteristics

A total of six eyes of five subjects, four men and one women, with an average age of 79.2 ± 9 years were included. All patients had primary open-angle glaucoma (POAG), and five eyes were pseudophakic. Three eyes had previously undergone trabeculectomy, with one requiring needling almost 30 years later. One patient received ELIOS in both eyes simultaneously, while another underwent trabeculectomy on the fellow eye at the same time. A third patient had simultaneous cyclophotocoagulation on the fellow eye. ELIOS was performed as a stand-alone procedure in all patients.

Before ELIOS, mean preoperative visual acuity was 0.6 ± 0.4 (logMAR), mean IOP was 20.7 ± 5.1 mmHg, the number of glaucoma medication was 3.3 ± 1.2 and mean deviation (MD) value in the visual field was 23.6 ± 1.6 . In the SD-OCT RNFL measurement, in all cases

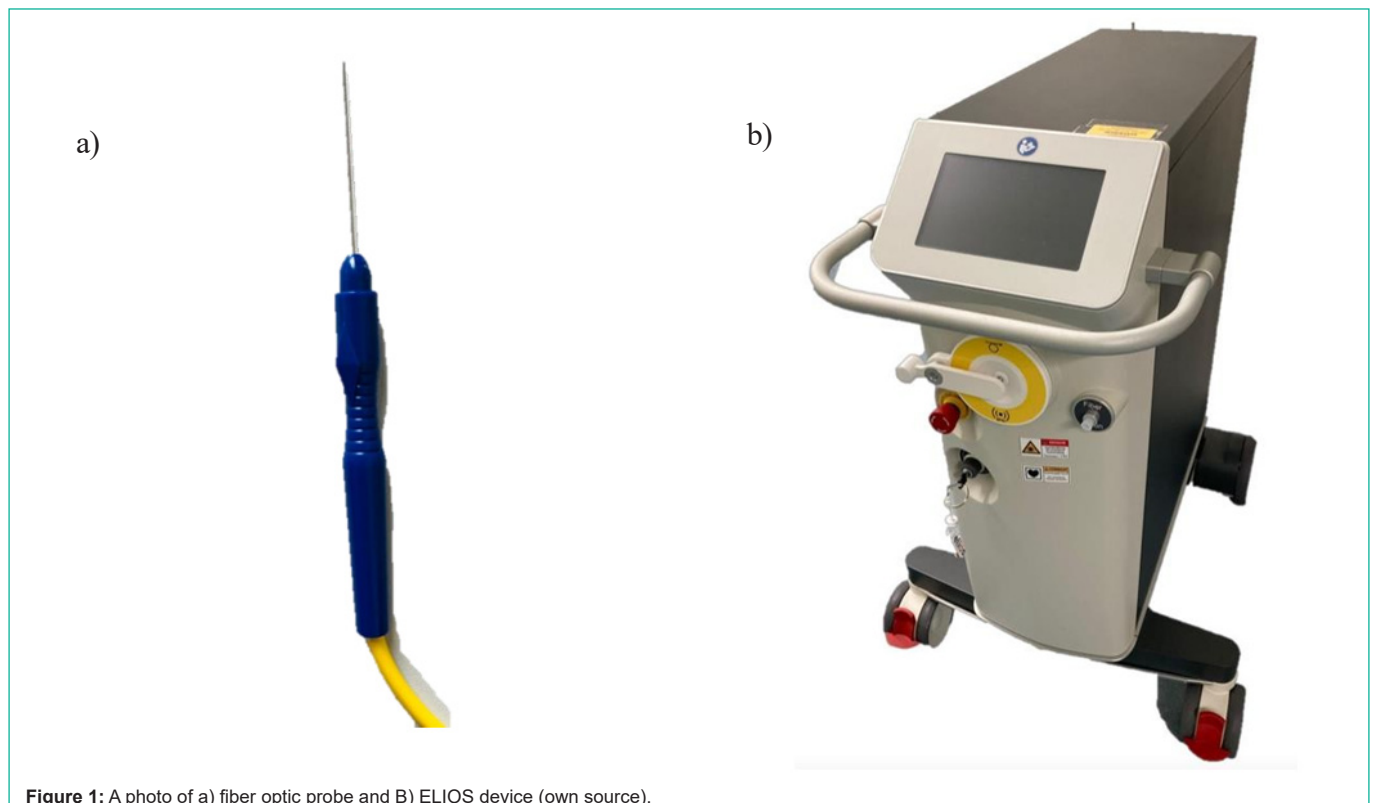


Figure 1: A photo of a) fiber optic probe and B) ELIOS device (own source).

Table 1: Patient’s characteristics; Abbreviation: F: female; M: male; R: right, L: left; TE: trabeculectomy.

No.	Age (years)	Gender	Type of glaucoma	Eye	Visual acuity (logMAR)	Visual field (MD)	Pachymetry (µm)	IOP at baseline (mmHg)	Number of Antiglaucoma medications at baseline	Previous operations	Additional informations
No.1	79	M	POAG	R	1.0	22.7	471	29	1	TE, needling	
No. 2	89	M	POAG	R	1.0	23.0	508	18	4	0	
No. 3	89	M	POAG	L	0.5	22.5	503	15	4	0	
No. 4	71	F	POAG	L	1.0	26.3	556	24	4	TE	Other eye TE at the same time
No. 5	67	M	POAG	L	0.4	23.3	561	17	4	0	Myopia: -19 diopter
No. 6	80	M	POAG	R	0.16	Goldmann perimetry only	506	21	3	TE	Another eye light perception

a floor effect was seen. Table 1 gives an overview over the patient’s characteristics.

IOP and Glaucoma Medication

Postoperatively, IOP measured 14.0 ± 5.1 mmHg at 1 week, 17.3 ± 4.9 mmHg at 1 month, 14.2 ± 3.6 mmHg at 3 months and 13.2 ± 3.5 mmHg at 6 months. The IOP values preoperatively, as well

as at 1 week, 1 month, 3 months, and 6 months postoperatively for individual patients, are presented in Figure 2.

The number of glaucoma medications was reduced to 1.2 ± 1.8 at 1 week, 1.2 ± 1.8 at 1 month, 2.2 ± 1.8 at 3 months and 2.8 ± 1.2 mmHg at 6 months. The number of glaucoma medication preoperatively, as well as at 1 week, 1 month, 3 months, and 6 months postoperatively for individual patients, are presented in Figure 3.

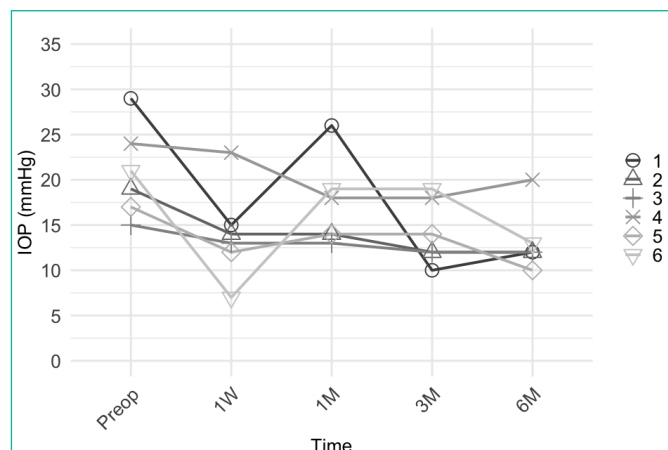


Figure 2: Intraocular pressure at baseline and at each follow-up visit for each eye separately. Abbreviation: Preop: Preoperatively; W: Week, M: Month; IOP: Intraocular Pressure.

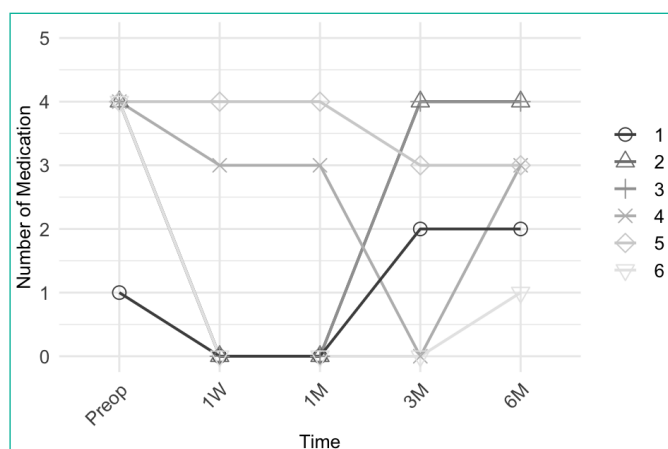


Figure 3: Glaucoma medication at baseline and at each follow-up visit for each eye separately. Abbreviation: Preop: Preoperatively; W: Week, M: Month; IOP: Intraocular Pressure.

Complications and Revisions

One eye had a hyphema on the first postoperative day, which resolved spontaneously. None of the patients needed additional glaucoma surgery within 6 months.

Discussion

Minimally invasive glaucoma surgeries (MIGS) have become important in treating glaucoma due to their proven safety and effectiveness in clinical trials. This case study is the first to demonstrate the effectiveness of minimal invasive excimer laser treatment (ELIOS) for advanced open-angle glaucoma.

Patients with advanced glaucoma often require more frequent visits than those with early-stage disease, making a safe, effective procedure that reduces follow-up needs highly desirable [7]. While standard treatments typically begin with medication [2] or SLT, there is no consensus on the best approach for advanced glaucoma due to limited comparative trials [8]. Recent guidelines recommend surgery for patients with advanced visual field loss [3], though evidence on the superiority of surgery over medication [9] remains insufficient.

In our study, all patients had advanced glaucoma, with three having undergone prior trabeculectomy. One patient had high myopia (myopia magna) and another one had only light perception in the fellow eye. Despite these challenges, we achieved a significant reduction in IOP from 20.7 ± 5.1 mmHg to 13.2 ± 3.5 mmHg at 6 months, along with a decrease in glaucoma medications from 3.3 ± 1.2 to 2.8 ± 1.2 mmHg. Importantly, this was accomplished without complications or the need for additional glaucoma procedures. According to a retrospective study, factors such as higher baseline IOP, worse visual field, and older age were important risk factors for blindness in advanced glaucoma [10]. Notably, despite all patients having end-stage visual field changes, none experienced a vision loss due to wipe-out during or after the ELIOS procedure.

To prevent progression in advanced glaucoma, maintaining a mean IOP of around 12 mmHg [11] or at the very least below 18

mmHg, is crucial during all follow-up visits [12]. In our study, IOP at 6 months was 13.2 ± 3.8 mmHg representing a 36% IOP reduction from baseline. These results align with previous studies, which have demonstrated a 20% to 40% reduction in IOP and a decrease in glaucoma medication following ELT [13].

These findings are consistent with studies on other MIGS procedures. For instance, in patients with advanced glaucoma treated with gonioscopy-assisted transluminal trabeculotomy (GATT), IOP dropped from 25.0 ± 7.3 mmHg with 3.4 ± 0.6 glaucoma medication at baseline to 15.9 ± 4.3 mmHg with 1.2 ± 0.5 glaucoma medication after 18 months of follow-up [14]. Similarly, the Hydrus-Implant tested in advanced glaucoma patients (31% of the cohort) showed an IOP reduction from 18.9 ± 4.8 to 13.9 ± 2.3 mmHg and a decrease in medication from 3.0 ± 1.2 to 2.0 ± 1.2 after 36 months [15]. These consistent results suggest that ELIOS, like other MIGS procedures, may offer a viable treatment option for advanced glaucoma.

Our study had certain limitations, including small group of patients and a relatively short follow-up period.

According to this study, ELIOS was effective in reducing intraocular pressure and the number of glaucoma medications in patients with advanced open-angle glaucoma. However, larger real-world and long-term data are still needed to confirm these findings.

References

1. Strzalkowska A, Hoffmann EM, Strzalkowski P, Stingl JV, Pfeiffer N, Schuster AK. Real-world-Ergebnisse von glaukomchirurgischen Verfahren beim Offenwinkelglaukom. *Die Ophthalmologie*. 2023; 120: 1107-1116.
2. Anthony J King, Richard E Stead, Alan P Rotchford. Treating patients presenting with advanced glaucoma—should we reconsider current practice? *British Journal of Ophthalmology*. 2011; 95: 1185-1192.
3. National Institute for Health and Clinical Excellence. *Glaucoma: Diagnosis and Management of Chronic Open Angle Glaucoma and Ocular Hypertension*. NICE; 2009.
4. Edmunds B, Thompson JR, Salmon JF, Wormald RP. The National Survey of Trabeculectomy. III. Early and late complications. *Eye*. 2002; 16: 297-303.
5. Berlin MS, Töteberg-Harms M, Kim E, Vuong I, Giers U. Excimer Laser Trabeculostomy (ELT): An Effective MIGS Procedure for Open-Angle Glaucoma. In: *Surgical Innovations in Glaucoma*. Springer New York; 2014: 85-95.
6. Chan L, Moster MR, Bicket AK, et al. New Devices in Glaucoma. *Ophthalmol Ther*. 2023; 12: 2381-2395.
7. Walt JG, Doyle JJ, Kotak SV, Evans SJ. A multicenter, retrospective pilot study of resource use and costs associated with severity of disease in glaucoma. *Archives of*. Published online 2006.
8. Naik M, Kapur M, Gupta V, Sethi H, Srivastava K. Ripasudil Endgame: Role of Rho-Kinase Inhibitor as a Last-Ditch-Stand Towards Maximally Tolerated Medical Therapy to a Patient of Advanced Glaucoma. *Clin Ophthalmol*. 2021; 15: 2683-2692.
9. Burr J, Azuara-Blanco A, Avenell A, Tuulonen A. Medical versus surgical interventions for open angle glaucoma. *Cochrane Database Syst Rev*. 2012; 2012: CD004399.
10. Peters D, Bengtsson B, Heijl A. Factors associated with lifetime risk of open-angle glaucoma blindness. *Acta Ophthalmol*. 2014; 92: 421-425.
11. Sato S, Hirooka K, Nitta E, Ukegawa K, Tsujikawa A. Additive Intraocular Pressure Lowering Effects of the Rho Kinase Inhibitor, Ripasudil in Glaucoma Patients Not Able to Obtain Adequate Control After Other Maximal Tolerated Medical Therapy. *Adv Ther*. 2016; 33: 1628-1634.
12. The Advanced Glaucoma Intervention Study (AGIS): 7. The relationship between control of intraocular pressure and visual field deterioration. The AGIS Investigators. *Am J Ophthalmol*. 2000; 130: 429-440.
13. Durr GM, Töteberg-Harms M, Lewis R, Fea A, Marolo P, Ahmed IIK. Current review of Excimer laser Trabeculostomy. *Eye Vis (Lond)*. 2020; 7: 24.
14. Aktas Z, Ucgul AY, Bektas C, Karamert S. Surgical outcomes prolene gonioscopy assisted transluminal trabeculotomy patients moderate advanced open-angle glaucoma. *J Glaucoma*. 2019; 28: 884-888.
15. Salimi A, Kassem R, Santhakumaran S, Harasymowycz P. Three-Year Outcomes of a Schlemm Canal Microstent (Hydrus Microstent) with Concomitant Phacoemulsification in Open-Angle Glaucoma. *Ophthalmol Glaucoma*. 2023; 6: 137-146.