

## Clinical Image

## Special Herpetic Keratitis

Bouslamti A; Majdoubi K; Hasnaoui I; Bardi C; Anas B; Serghini L; Elhassan A; Berraho A  
Department of Ophthalmology B, Ibn-Sina University Hospital, Rabat, Morocco

**\*Corresponding author: Ahmed Bouslamti**

Department of Ophthalmology B, Ibn-Sina University Hospital, Rabat, Morocco.  
Email: ahmedbouslamti@gmail.com

**Received:** March 09, 2023

**Accepted:** April 20, 2023

**Published:** April 27, 2023

**Abstract**

Herpetic keratitis a common form of eye infection. Its manifestations can often impede the quality of life and vision. We report the case of a 32 year old female with a unilateral typical herpetic keratitis. A treatment with topical antivirals gave great results. The surveillance of recurrences is primordial in these cases.

**Introduction**

Herpes Simplex Virus (HSV) is a very common, lifelong infection that often is asymptomatic. The ocular manifestations of a herpes infection can be very serious, when the repetition of infectious episodes can lead to an alteration of the corneal transparency.

**Clinical Case**

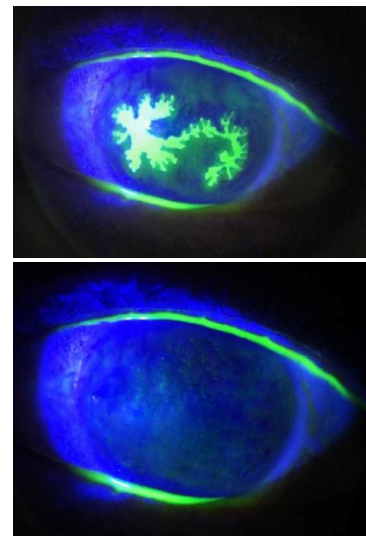
A 32 year old female visited us for a unilateral red eye with blurred vision (right eye). Her best corrected visual acuity was 20/40 on the right eye and 20/20 on the left eye. The slit lamp exam showed a typical dendritic keratitis suggesting an hsv infection.

**Discussion**

Herpetic keratitis can be unilateral or, more rarely, bilateral. The latter being more common in patients with atopy due to proposed immune dysregulation increasing susceptibility to viral infections. Age, geographic location, and socioeconomic status appear to affect the prevalence of disease. It can affect all the layers of the cornea and is sometimes misdiagnosed.

The typical epithelial manifestations include punctate keratitis, dendritic keratitis, and geographic keratitis.

The acute infections are usually treated with topical and/or oral antivirals while prophylactic doses can also be prescribed for the recurring forms.



**Figure 1:** The patient was treated with topical ganciclovir five times per day and oral valacyclovir 500mg three times per day for 15 days. The slit lamp examination showed a recovery of the cornea with a corrected visual acuity on the right eye of 20/25.

**References**

1. Sibley D, Larkin DFP. Update on Herpes simplex keratitis management. *Eye*. 2020; 34: 2219–2226.