

Case Report

A Rare Complication of Nasal Retaining Loop Insertion

Saunders TFC* and Osborne MS

Department of Otolaryngology, Royal Stoke University Hospital, UK

*Corresponding author: Tom Saunders, Department of Otolaryngology, Royal Stoke University Hospital, UK

Received: February 12, 2015; Accepted: March 25, 2015; Published: March 27, 2015

Abstract

An 80 year old man was referred by his GP with a 6 week history of foreign body sensation in his left nasal cavity caused by an unidentified metallic wire seen on anterior rhinoscopy. With a combination of radiology and flexible nasendoscopy the cause was found to be a flexible guidewire that had been used to insert a nasal retaining loop (nasal bridle) 12 months earlier. This required removal under general anaesthetic. Fortunately this retained foreign body resulted in no long term sequela to the nasal cavity. To the authors knowledge there are no documented cases reported in the literature, and this case highlights the importance of developing guidelines of correct insertion and removal of these popular devices.

Introduction and Case Presentation

An 83 year old man was referred by his GP with a six week history of a foreign body sensation in the left nasal cavity, causing irritation and skin rash of the philtrum. There was no epistaxis, discharge or obstruction of airflow through the affected side of the nose. The patient reported no history of any foreign body insertion into the nose since his coronary artery bypass graft 12 months previously when he had been admitted to ITU post surgery and required a Bridle fixed nasogastric tube for feeding during. This was as a result of an episode of post-operative confusion.

On examination a metallic flexible wire was seen to be coming from the left nasal cavity. On gentle manipulation under local anaesthetic it was not freely mobile and seemed to be heading to the post nasal space. A flexible nasendoscopy was performed – the wire was imbedded in nasal floor, covered with granulation tissue, and we were unable to remove at this time due to resistance in the PNS where the orange cap of the wire that was stuck to the floor of the nose.

After examining the manufacturer's brochure for the Bridle NG tube we concluded that the wire corresponded to the flexible guide wire that is used during the insertion, but should be removed prior to fixation of the bridle. This guide wire had incorrectly been pulled through the right nasal cavity, passing around posterior to the Vomer

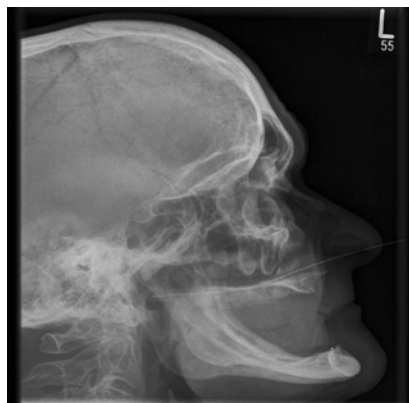

Figure 1: A lateral plain film radiograph was taken.

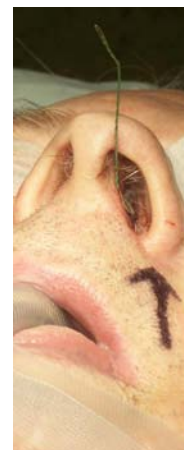

Figure 2: The patient was taken the theatre for removal under general anaesthetic.




Figure 3: The 14cm wire was removed from the oral cavity.

and into the left nasal cavity. It was not noticed during removal of the bridle or the NG tube and had been left in situ for 12 months.

Fortunately for this patient, there was no obvious long-term damage to the nasal cavity mucosa or the septum.

Discussion

We carried out a literature search on the topic, but no cases have been reported of this particular complication, which is purely iatrogenic. NHS trusts across the country provide clear guidelines [1], adapted from the manufacturer's instructions, on the correct insertion of bridle nasal loops. The known complications include trauma to the nasal septum, epistaxis and mucosal irritation. Bridle loops (also known as 'nasal retaining loops') are used to maintain an

enteral feeding option in a variety of conditions and reduce the risk of decannulation of NG tubes and can reduce the need for percutaneous endogastric (PEG) tube insertions.

This report however highlights that care needs to be taken when inserting the bridle loop and also when removing the NG tube. Medical staff using these devices should be aware of manufacture

insertion guidelines, and these should be used to develop local guidelines to ensure that guidewires are removed correctly and not left in situ in the nasal cavity.

References

1. Pratt J. Guideline for Insertion of a Nasal Bridle retaining loop. Portsmouth Hospitals NHS trust. 2013.