

## Research Article

# Utility of Long-Term Surveillance Neuroimaging Five Years Post-Diagnosis in the Management of Pediatric Brain Tumours

Hirpara DH<sup>1</sup>, Bhatt MD<sup>2</sup> and Katrin S<sup>2\*</sup><sup>1</sup>Department of Medicine, University of Toronto, Canada<sup>2</sup>Department of Pediatrics, McMaster Children's Hospital and McMaster University, Canada

**\*Corresponding author:** Scheinemann Katrin, Division of Pediatric Hematology/Oncology, Department of Pediatrics, McMaster Children's Hospital and McMaster University, Canada

**Received:** February 20, 2016; **Accepted:** March 10, 2016; **Published:** March 19, 2016

## Abstract

There is significant variability in surveillance imaging of Central Nervous System (CNS) tumours. We aimed to assess the utility of surveillance neuroimaging after five years from diagnosis in children with Low-Grade Glioma (LGG), Medulloblastoma (MB), Primitive Neuroectodermal Tumour (PNET) and Ependymoma (EP). A retrospective chart review was conducted of all eligible patients (0-18 years) between January 1, 1990 - December 31, 2006 followed at a major pediatric teaching hospital for at least five years. 94 patients were eligible for analysis. 13 relapses were detected over a span of 17 years (1993-2010). The median time to relapse post treatment was  $3.2 \pm 1.7$  years (range: 0.5-13 years) and all relapses were among LGG patients. Two (15.4% of relapses) patients progressed after a period of five years from diagnosis; both were detected clinically. Of the 11 patients diagnosed with vascular abnormalities, nine (82%) had radiation-induced Cavemous Malformations (CM). The latency interval between radiation treatment and the detection of CM was  $13.4 \pm 4.2$  years (range: 2-22 years). 67% of patients with CM had an underlying diagnosis of MB/PNET. Although there is a need for a larger prospective study, these findings serve as preliminary evidence to question the utility of routine surveillance neuroimaging in LGG patients beyond five years from diagnosis.

**Keywords:** Surveillance neuroimaging; Relapse; Low-grade glioma; Medulloblastoma; Ependymoma

## Abbreviations

CNS: Central Nervous System; LGG: Low-Grade Glioma; MB: Medulloblastoma; PNET: Primitive Neuroectodermal Tumour; EP: Ependymoma; CM: Cavemous Malformations; MRI: Magnetic Resonance Imaging; CT: Computed Tomography

## Introduction

The incidence of Central Nervous System (CNS) tumours is second only to leukemia in children. CNS tumours currently account for 19% of childhood cancer cases in Canada [1]. According to a Central Brain Tumour Registry of United States report, approximately 4150 people under the age of 20 were expected to develop a CNS tumor in the USA in 2012. The prevalence of primary CNS tumors in children (0-19 years) is estimated to be 35.4 per 100,000; meaning over 28,000 children are living with this diagnosis in the USA [2].

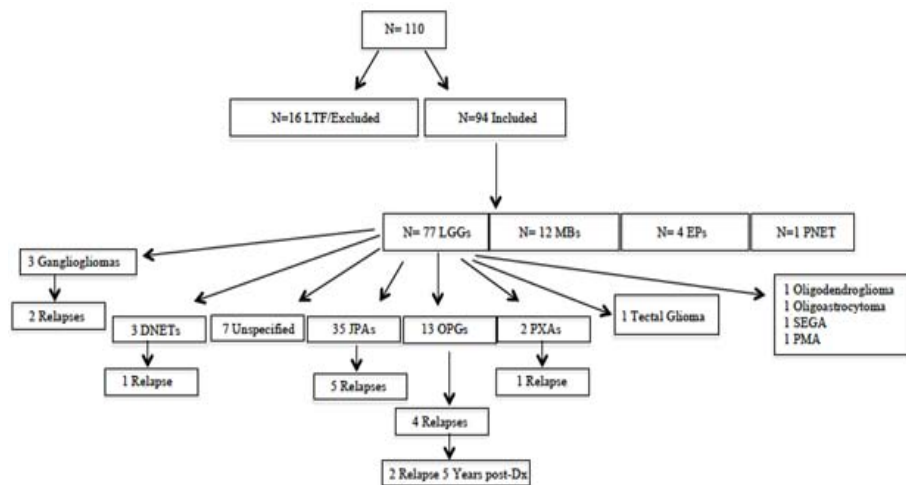
Recent advances in the management of childhood CNS tumours have led to improved survival rates. The increase in life expectancy among survivors poses additional challenges such as optimal monitoring for relapses and long-term effects of treatment. Relapse is a major cause of death in children with certain types of CNS tumors [3-4]. As a result, monitoring for clinical symptoms and asymptomatic radiologic changes comprise essential elements of follow-up. Most treatment protocols and guidelines, however, discuss recommendations for clinical and radiologic follow-up only up to five years from diagnosis. There is significant variability

in follow-up practices after five years, especially with surveillance neuroimaging. It is center dependent and ranges from yearly neuroimaging to quinquennial neuroimaging (once every five years). In our center, for instance, patients within five years of diagnosis undergo surveillance neuroimaging as per protocol. If there are no further recommendations, they are imaged biennially up to 10 years from diagnosis and quinquennially thereafter. However, there is no evidence to suggest an optimal approach.

The purpose of this study was to assess the utility of surveillance neuroimaging after five years from diagnosis in children diagnosed with Low-Grade Glioma (LGG), Medulloblastoma (MB), Primitive Neuroectodermal Tumour (PNET) and Ependymoma (EP). We reviewed children with these CNS tumours who were diagnosed, treated and followed at our institution to delineate the timing and identification of relapses and vascular abnormalities after a period of five years from diagnosis.

## Materials and Methods

The study was approved by the local institutional review board. A retrospective chart review was conducted of all eligible patients: pediatric patients (0-18 years) diagnosed with LGG, MB, PNET and EP and followed at McMaster Children's Hospital, Hamilton, Ontario, Canada. Our cohort consisted of patients diagnosed between January 1, 1990 and December 31, 2006. All patients were identified via clinic charts and hospital records. Patient's clinical information, including their age at diagnosis, treatment regimen, age at relapse and incidence



**Figure 1:** Overview of Patient Cohort (N=94). 13 recurrences are detected among LGG patients. Of these, only 2 recurrences (clinically diagnosed) take place after a period of 5 years post diagnosis (post-Dx).

JPA: Juvenile Pilocytic Astrocytoma (WHO Grade I); OPG: Optic Pathway Glioma (WHO Grade I-II, biopsy dependent); Tectal Glioma (WHO Grade I-II, biopsy dependent); DNET: Dysembryoplastic Neuroepithelial Tumour (WHO Grade I); Ganglioglioma (WHO Grade I); PXA: Pleomorphic Xanthoastrocytoma (WHO Grade II); Oligodendroglioma (WHO Grade II); Oligoastrocytoma (WHO Grade II); SEGA: Subependymal Giant Cell Astrocytoma (WHO Grade I); PMA: Pilomyxoid Astrocytoma (WHO Grade II)

of secondary malignancies as well as surveillance neuroimaging data were collected to identify the frequency and detection of recurrences and vascular abnormalities.

Recurrence was defined as development of a new lesion at local or distant sites. Progression for LGGs was defined as 25% increase in size over two follow-up scans. For other tumors, it was defined as enlargement of the residual lesion in all three dimensions according to the Response Assessment in Neuro-Oncology (RANO) criteria [5]. This information was obtained retrospectively via reports written by a staff radiologist. Recurrences, progressions and vascular abnormalities were also classified by mode of detection: radiographic (i.e. asymptomatic) or clinical (i.e. symptomatic). A diagnosis of relapse or vascular abnormality was deemed clinical if symptoms (eg, change in ophthalmologic, endocrinologic, or neurologic status) preceded or prompted a neuroimaging study (MRI or CT). A diagnosis was deemed radiologic if detected in an asymptomatic patient undergoing a routine follow-up study.

## Results

During the study period, a total of 110 pediatric patients were diagnosed with LGG, MB, PNET and EP. Of these, 16 patients were excluded for loss to follow-up before reaching five years post-diagnosis or for missing records. Data on 94 patients was obtained and analyzed. LGG patients accounted for 82% of the cohort (N=77) (Figure 1).

A total of 13 recurrences and progressions, all amongst LGG patients, were detected over a span of 17 years (1993-2010) (Table 1). The median time to relapse was  $3.2 \pm 1.7$  years (range: 0.5-13 years). Of the patients who relapsed, the location of LGG was posterior fossa in 38.5%, cerebral in 30.8%, midline in 15.4%, and optic pathway in 15.4%. Surgical resection was the most common primary treatment in relapsed patients, with 53.8% of patients having gross total resection and 38.5% having subtotal resection (>75% resection). There were no

relapses among MB, PNET or EP patients.

Two patients (15.4% of relapses), one with suprasellar LGG and another with right Optic Pathway Glioma (OPG) progressed after a period of five years from diagnosis. They were both detected clinically. Patient one, initially treated with subtotal surgical resection, presented at 12 years from initial diagnosis, with a two-week history of severe headaches four months prior to their yearly surveillance MRI. An MRI done at the time and six months later confirmed progression of LGG. The patient was treated with vinblastine monotherapy for 70 weeks and since has stable disease with no recurrence of symptoms four years later. Patient two, who was initially treated with vincristine and carboplatin, was also being followed with yearly surveillance MRIs. This patient presented at five-and-a-half years from initial diagnosis with deterioration in vision along with diplopia and nystagmus. These symptoms were noted one month prior to the next scheduled neuroimaging. An urgent MRI confirmed progression of LGG. The patient was also treated with vinblastine monotherapy for 70 weeks following which she has stable disease and stable vision two years later.

11 patients were diagnosed with vascular abnormalities during follow-up. Nine patients had radiation-induced Cavernous Malformations (CM), while two patients were diagnosed with developmental venous anomaly. CM was diagnosed incidentally in all patients during routine surveillance neuroimaging. The latency interval between radiation treatment and the detection of CM was  $13.4 \pm 4.2$  years (range: 2-22 years). Six patients had multiple lesions. Majority of patients (67%) with CM had an underlying diagnosis of MB/PNET, while the remaining 33% had LGGs (who were treated with radiation).

## Discussion

In this study, we investigated patients diagnosed with LGG, MB, PNET or EP to assess the incidence of recurrences, progressions and

**Table 1:** Patient characteristics.

	LGG (N=77)	MB (N=12)	EP (N=4)	PNET (N=1)	Total (N=94)
<b>Age at diagnosis (years; mean <math>\pm</math> 95% CI)</b>	8.1 $\pm$ 1.1	11.5 $\pm$ 3.3	12.5 $\pm$ 10.0	10	8.4 $\pm$ 1.0
<b>Sex</b>					
<b>Male</b>	33 (43%)	9 (75%)	3 (75%)	1 (100%)	46
<b>Female</b>	44 (57%)	3 (25%)	1 (25%)	0	48
<b>Extent of Surgical Resection*</b>					
<b>Gross total resection</b>	35 (45%)	7 (58%)	2 (50%)	1 (100%)	45 (48%)
<b>Subtotal resection (&gt;75%)</b>	8 (10%)	2 (17%)	1 (25%)	0	11 (12%)
<b>Partial resection</b>	12 (16%)	2 (17%)	1 (25%)	0	15 (16%)
<b>Biopsy*</b>	3 (4%)	0	0	0	3 (3%)
<b>No surgical intervention</b>	19 (25%)	1 (8%)	0	0	20 (21%)
<b>Relapse</b>	(N=13)	(N=0)	(N=0)	(N=0)	(N=13)
<b>Time to relapse (years; mean <math>\pm</math> 95% CI)</b>	3.2 $\pm$ 1.7	N/A	N/A	N/A	3.2 $\pm$ 1.7
<b>No. relapse 5 years post Dx</b>	2	N/A	N/A	N/A	2
<b>Vascular abnormalities (Cavernomas)</b>	(N=3)	(N=5)	(N=0)	(N=1)	(N=9)
<b>Time to diagnosis (years; mean <math>\pm</math> 95% CI)</b>	12.3 $\pm$ 6.9	16.4 $\pm$ 3.5	N/A	2	13.4 $\pm$ 4.2

LGG: Low Grade Glioma; MB: Medulloblastoma; EP: Ependymoma; PNET: Primitive Neuroectodermal Tumour; SD: Standard Deviation; No: Number; Dx: Diagnosis  
\*Resection denotes surgical removal of the tumour whereas a biopsy involves sampling of tumour cells to establish a histopathological diagnosis.

**N.B.** A) Some tumours may have been surgically resected as well as biopsied. Several tumours were managed conservatively without any surgical intervention. B) The division of Hematology/Oncology at McMaster Children's Hospital follows patients throughout their course of treatment. Consequently, some patients may not fall within the pediatric age range of 0-18 years.

vascular abnormalities five years from diagnosis and their primary mode of detection, whether clinical or radiologic. The observed rate of recurrences and progressions among LGG patients of 17% was comparable to published literature [6-10]. Furthermore, the incidence of recurrences and progressions five years from diagnosis of 2.6% observed in this study was in accordance previous reports. In a study describing relapses amongst children with low-grade astrocytoma, 2.1% of patients (one cerebellar and two midline in location) relapsed after five years from diagnosis. Their mode of detection, however, clinical or radiologic, was not described [8]. Another study investigating recurrence in low-grade pediatric brain tumours reported diagnosing one asymptomatic patient (1.5%) on routine surveillance neuroimaging 10 years from diagnosis [9]. However, it is difficult to ascertain whether the patient's outcome would be different if they were diagnosed with clinical symptoms. In our study, despite routine surveillance neuroimaging, both patients presented with clinical symptoms between their scheduled MRI scans. Also, their outcomes were not compromised due to diagnosis by clinical symptoms. Our data, thus, questions the utility of routine surveillance neuroimaging after five years from diagnosis in LGG patients if regular clinical follow-up and contact is maintained.

We did not observe a single case of relapse for other CNS tumours (MB, PNET and EP), within or after five years from diagnosis. Analysis of relapse rates, however, was limited due to a small sample size. Nonetheless, the literature suggests that MB patients very rarely experience recurrence after five years from diagnosis. In a recent study of recurrence patterns in MB with 203 patients from 15 centers worldwide, the maximum duration from diagnosis to recurrence was less than four years (44.8 months) [11]. On the other hand, late recurrences (after five years from diagnosis) are common in patients with EP. In one study, 43% of recurrences were detected via neuroimaging in asymptomatic patients. The patients who were

diagnosed with clinical symptoms had a 12-times greater risk of death in that particular cohort [12]. In another series of 159 children with CNS tumours, ependymoma patients (19 children) were the only group that showed improved outcome when recurrences were identified by surveillance rather than symptoms [13]. Hence, there is adequate evidence in literature to support routine surveillance neuroimaging of EP patients even after five years from diagnosis.

In this study, the observed rate of radiation-associated CM was 9.6%, of which the majority was found in MB/PNET patients, likely a function of prior irradiation and not tumour type. In a recent study investigating the natural history of radiation-associated vascular abnormalities, 34% of patients were diagnosed with CMs. Notably, a majority of their cohort (54.6%) was comprised of MB patients and did not include any LGG patients. While none of the patients experienced symptoms from CM or had hemorrhage in this study, one of 34 patients had extra-lesional hemorrhage, diagnosed clinically due to new-onset headaches [14]. In another study examining cavernous malformations in children and young adults, the hemorrhage rate for incidentally discovered asymptomatic CM was very low at 0.2% per patient-year [15]. Given such low likelihood of secondary complications (i.e. hemorrhage), asymptomatic discovery of CMs does not seem to warrant routine surveillance neuroimaging.

Surveillance neuroimaging poses extensive costs and undue burden on the individual and the health care system. First, the institutional cost of neuroimaging per recurrence at five years is estimated to be \$104,094 [9]. Second, the patients and families experience significant anxiety around the timing of neuroimaging. Third, there are added risks of general anesthetic for the younger patients who require sedation.

The limitations of our study include its retrospective design and

prolonged time period over which patients were treated. This may have introduced treatment bias from evolving adjuvant chemotherapy and radiotherapy. Furthermore, our study lacks a central imaging review as well as a central pathological review to confirm the exact histopathological diagnoses. Therefore, our conclusions require validation in larger scale studies with even longer follow-up as the nature of some of these pathologies may make early conclusions about disease recurrence or progression spurious.

## Conclusion

This study provides precursory evidence for further investigation into the utility of routine surveillance neuroimaging in LGG patients after five years from diagnosis. There is clearly a need for a larger prospective study in patients with LGG and other CNS tumours to decisively determine the value, timing and frequency of long-term surveillance neuroimaging.

## References

- Canadian Cancer Society's Advisory Committee on Cancer Statistics. Canadian Cancer Statistics. Toronto, ON: Canadian Cancer Society. 2014.
- Therese A. Dolecek, Jennifer M. Propp, Nancy E. Stroup, and Carol Kruchko. CBTRUS Statistical Report: Primary Brain and Central Nervous System Tumors Diagnosed in the United States in 2004-2007. Central Brain Tumor Registry of the United States.
- Fleming AJ, Chi SN. Brain tumors in children. *Curr Probl Pediatr Adolesc Health Care*. 2012; 42: 80-103.
- La Marca F, Tomita T. Importance of patient evaluation for long-term survival in medulloblastoma recurrence. *Child's Nervous System*. 1997; 13: 30-34.
- Quant EC, Wen PY. Response assessment in neuro-oncology. *Curr Oncol Rep*. 2011; 13: 50-56.
- Dorward IG, Luo J, Perry A, Gutmann DH, Mansur DB, Rubin JB, et al. Postoperative imaging surveillance in pediatric pilocytic astrocytomas. *J Neurosurg Pediatr*. 2010; 6: 346-352.
- Due-Tonnessen BJ, Helseth E, Scheie D, Skullerud K, Aamodt G, Lundar T. Long-term outcome after resection of benign cerebellar astrocytomas in children and young adults (0-19 years): report of 110 consecutive cases. *Pediatr Neurosurg*. 2002; 37: 71-80.
- Gajjar A, Sanford RA, Heideman R, Jenkins JJ, Walter A, Li Y, et al. Low-grade astrocytoma: a decade of experience at St. Jude Children's Research Hospital. *J Clin Oncol*. 1997; 15: 2792-2799.
- Kim AH, Thompson EA, Governale LS, Santa C, Cahll K, Kieran MW, et al. Recurrence after gross-total resection of low-grade pediatric brain tumors: the frequency and timing of postoperative imaging. *J Neurosurg Pediatr*. 2014; 14: 356-364.
- Krieger MD, Gonzalez-Gomez I, Levy ML, McComb JG. Recurrence patterns and anaplastic change in a long-term study of pilocytic astrocytomas. *Pediatr Neurosurg*. 1997; 27: 1-11.
- Ramaswamy V, Remke M, Bouffet E, Faria CC, Perreault S, Cho YJ, et al. Recurrence patterns across medulloblastoma subgroups: an integrated clinical and molecular analysis. *Lancet oncology*. 2013; 14: 1200-1207.
- Good CD, Wade AM, Hayward RD, Phipps KP, Michalski AJ, Harkness WF, et al. Surveillance neuroimaging in childhood intracranial ependymoma: how effective, how often, and for how long? *J Neurosurg*. 2001; 94: 27-32.
- Minn A, Pollock B, Garzarella L, Dahl GV, Kun LE, Ducore JM, et al. Surveillance neuroimaging to detect relapse in childhood brain tumors: A pediatric oncology group study. *J Clin Oncol*. 2001; 19: 4135-4140.
- Giannatale AD, Morana G, Rossi A, Cama A, Bertoluzzo L, Barra S, et al. Natural history of cavernous malformations in children with brain tumors treated with radiotherapy and chemotherapy. *J Neurooncol*. 2014; 117: 311-320.
- Al-Holou WN, O'Lynnner TM, Pandey AS, Gemmete JJ, Thompson BG, Muraszko KM, et al. Natural history and imaging prevalence of cavernous malformations in children and young adults. *J Neurosurg Pediatr*. 2012; 9: 198-205.