

## Case Report

# Coffin-Siris Syndrome Presents with Novel ARID-2 Gene Mutation

Kaivan Patel<sup>1,3\*</sup>; Shital Patel<sup>2</sup>; Abhijit Pandya<sup>3</sup>; Patricia Rowe-King<sup>5</sup>

<sup>1</sup>Department of Academic Research, Advanced Research LLC, Florida, USA

<sup>2</sup>Department of Medicine, Physical Research Laboratory, Ahmedabad, India

<sup>3</sup>Department of Electrical and computer engineering, Florida Atlantic University, Florida USA

<sup>4</sup>Department of Graduate Medical Education, Broward Health, Florida, USA

\*Corresponding author: Kaivan Patel

Department of Academic Research, ADVANCED RESEARCH LLC, Florida, USA.

Email: Patelkaivan99@gmail.com

Received: July 03, 2023

Accepted: July 28, 2023

Published: August 04, 2023

## Introduction

Coffin-Siris Syndrome (CSS) is a rare genetic condition that affects neuromuscular development of newborns on an annual basis world worldwide. It is most commonly caused by mutations in the ARID1A, ARID1B, ARID 2, SMARCA4, SMARCB1, DPF2 and SMARCE1 genes which are subunits of BAF complex.

The BRG1/BRM-Associated Factor (BAF) complex, a subunit of mammalian SWI/SNF complex, is crucial for regulating gene expression and differentiation of neuronal cell lineage. SWI/SNF complex was first identified in yeast [1]. The BAF complex has three sub-units, Polybromo-Associated BAF complex (PBAF), Canonical BAF complex (cBAF), and non-canonical BAF complex (ncBAF) (Figure 1). The BAF complex affects different stages of development. The mutation causes significant damage to the development of different organ systems. Mutations primarily cause abnormal embryonic development, neural development, and abnormal tumor suppression, which causes cancer [2].

Neural Stem Cells (NSCs) create neural progenitor BAF (npBAF) complex. Then, the neuronal BAF (nBAF) complex is derived from the npBAF complex. Brg1 and Baf155 are derived from nBAF complex. The complex heterozygous loss of *Brg1* and *Baf155* leads to defects in neural tube closure [3]. Furthermore, *Brg1* depletion in Nestin+—NSCs results in severe

## Abstract

Coffin-Siris Syndrome (CSS) is a rare genetic condition most commonly associated with ARID1A, ARID1B, ARID 2, SMARCA4, SMARCB1, DPF2, and SMARCE1 genetic mutations. The most common features of CSS are intellectual disabilities and facial abnormalities. We report a case of a 10-month-old infant who presented with craniosynostosis and developmental delays. Clinical improvement was observed after conservative therapy. This paper discusses the BAF gene family and how mutations in this gene family influence the development of children. The prognosis of CSS has also been discussed.

**Keywords:** Coffin siris syndrome; ARID-2 gene mutation; De novo mutation; Craniosynostosis; Intellectual disability

defects of proliferation and formation of the neural progenitor pool, causing thinning of the cortex, midbrain and deficiency in cerebellar development, leading to perinatal death [4].

The sub-units of the BAF complex and SWI/SNF complex can develop mutations through numerous mechanisms resulting in a wide variety of clinical syndromes and diseases including CSS, nicolaides–baraitser syndrome, autism spectrum disorder kleeftstra's syndrome, amyotrophic lateral sclerosis, and schizophrenia. Moreover, CSS has 12 types. Types are differentiated based on mutations of 12 different genes/loci (Table 1).

**Table 1:**

Coffin siris syndrome	Gene or locus
1	ARID1B
2	ARID1A
3	SMARCB1
4	SMARCA4
5	SMARCE1
6	ARID 2
7	DPF 2
8	SMARCC2
9	SOX11
10	SOX 4
11	SMARCD1
12	BICRA

CSS follows an autosomal dominant inheritance pattern; however, it usually occurs for the first time in a family. These mutations occurring for the first time in a family is commonly known as sporadic or de novo mutations. Mutations present with developmental abnormalities or malignancies. Most patients present with facial abnormalities, intellectual disabilities, and neuromuscular developmental delays. Occupational, physical, and speech therapy can help affected individuals attain their full potential [5].

The incidence of CSS is extremely low since the published data on incidence and prevalence is scarce. In our presented case also has craniosynostosis. Approximately 1 in every 2,500 babies is born with craniosynostosis in the United States [6].

Our case describes a unique presentation of ARID-2 gene mutation associated with dysmorphic facial features and intellectual disability. There is developmental delay seen in the infant due to the presence of gene mutation.

### Case Description

Consent for the publication of the case and images was obtained from the patient's legal guardian. A mother presented with a 10-month female infant weighing 7.8 kg (<5<sup>th</sup> percentile) with the chief complaint of the child's inability to sit in an upright position without support. History was obtained regarding the developmental milestones of the infant (hearing, sight, reaching out for objects and ability to eat pureed type of foods). Normal milestones at 10 month of age are ability to sit without support, roll both ways (front to back and back to front), transfers object from one hand to another hand, have full color vision, distance vision maturation, respond to own name, having stranger anxiety, babbling, exploring with hands and trying to find partially hidden objects. Based on this history, physician noted that developmental milestones were partially attained. The mother's obstetric history was taken. She had a lower segment cesarean section with this baby. This infant was her second child. The first child is currently five years old and healthy with all developmental milestones reached. The first child was delivered through a normal spontaneous vaginal delivery. The second child at birth weighed 3 kg, and the child was not required to be admitted in NICU (Neonatal Intensive Care Unit). Neonatal jaundice was absent.

After obtaining the history, upon examination, the patient's head circumference was found to be 44 cm (10<sup>th</sup> percentile). The anterior fontanelle and the posterior fontanelle were closed. The prominence of frontal eminence made the clinician suspicious and considered craniosynostosis as the provisional diagnosis. The patient had mild micrognathia, low-set ears, and thick eyebrows.

A detailed examination was performed of which the components and findings were: -

#### 1- Developmental milestones -

- A. Head control – Partially achieved
- B. Rolling (Front and back) – Present
- C. Rolling (Back to Front)- Present
- D. Prone on elbow – Present
- E. Supported sitting – Present for 15-20 minutes
- F. Independent sitting – Not present

G. Supported standing – Poor weight bearing on both sides

H. Crawling- Present

#### 2- Fine motor examination -

A. Hand preference – Right = Left

B. Reaching out – Present

C. Grasping – Radial Palmar

D. Midline orientation – Present

#### 3- Oromotor examination -

A. Eating habits – Tolerates liquids and pure based foods

B. Mouthing of objects – Present

C. Sucking – Present

D. Swallowing – Present

E. Synchronization of tongue cheek – Intermittently present

F. Mode of Communication – Babbles

#### 4- Musculoskeletal examination -

A. Tone – Hypotonia

B. Stiffness– Not present

C. Proprioception – Affected

D. Strength – Poor control -> Trunk extension with no abdominal contractions

#### 5- Sensory -

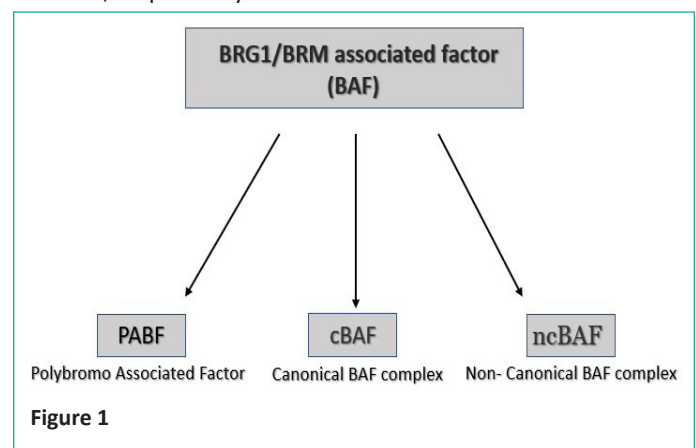
A. Visual Function – Abnormal

B. Auditory Function -Abnormal

#### 6- Cognition –

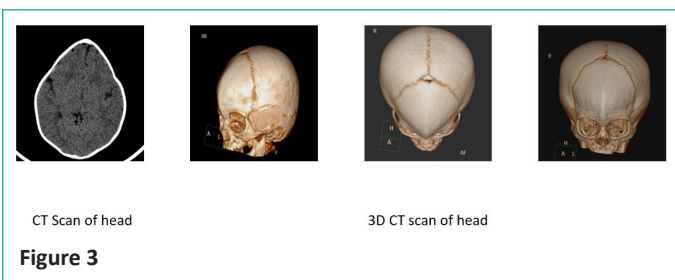
Delayed according to BSID-4 (Bayley scales of infant development)

The physician diagnosed the patient as having craniosynostosis and recommended that the infant receive imaging studies with Computed Tomography (CT) with 3D reconstruction (3D-CT) which confirmed the diagnosis of metopic craniosynostosis. The imaging study revealed premature fusion of metopic suture - trigonocephaly which appeared consistent with metopic craniosynostosis (Figure 3) and Ophthalmology and Otology were consulted to examine bilateral ocular and otologic structure and function, respectively.



Gene (Transcript) #	Location	Variant	Zygoty	Disease (OMIM)	Inheritance	Classification
<b>ARID2 (+)</b> (ENST00000334344.11)	Exon 10	c.1246A>G (p.Ile416Val)	Heterozygous	Coffin-Siris syndrome-6	Autosomal dominant	Uncertain Significance

Figure 2



CT Scan of head

3D CT scan of head

Figure 3

**Ophthalmology:** (1) visual field analysis revealed: 30% vision loss

**Otology:** (1) audiometric testing revealed: 40% bilateral sensory neural hearing loss.

At this time, genetic analysis was performed and revealed the presence of ARID-2 gene mutation, which is diagnostic of diagnosed CSS-6 (Figure 2).

The patient was then recommended for monthly follow-ups with specific physiotherapy exercises for strength and stability. Multivitamin supplements were prescribed to support growth and development. When the patient came for follow-up after 2 months, patient was examined to assess improvements. Her weight was now 8.3kg (<5<sup>th</sup> percentile) and head circumference is 45.8cm (25<sup>th</sup> percentile). On examination, improvement was noted in the following areas: head control, proprioception, muscle tone, ability to sit, core strength, weight bearing and cognition as tested on BSID-4 scales.

Overall improvement regarding her growth was seen. The mother was recommended to continue home exercises on the infant regularly. The supplements were continued as before.

### Case Discussion

CSSs are a group of rare congenital neurodevelopmental disorders caused by various genetic mutations that affect the nBAF complex. Here, we present a case of TYPICAL/ATYPICAL in a patient with CSS-6, who was diagnosed with an unexpected ARID-2 mutation. The estimated prevalence of the CSS-6 variant is a few hundred cases, as determined by experts. Family history can be negative such as in this case [2].

In the presented case, negative family history is suggestive of a de novo mutation. The mechanism by which de novo mutations occur is fundamentally related to epigenetics, genetic mutations secondary to environmental hazards, toxins, and specific electromagnetic frequencies [7-9]. The epidemiological and clinical consequences of these mutations are CSSs, which severely damage the normal and healthy development of affected infants. As previously stated, this may include developmental abnormalities and developmental delays [10]. There are several common clinical features of de novo mutations, the most significant feature of which is Intellectual Disability (ID). Coffin siris syndrome can be suspected when a patient presents with distinctive facial features such as a wide mouth, thick lips, thick eyelashes and brows, broad nose, flat nasal bridge, extra hair growth on the face and body, sparse scalp hair, small head size, intellectual disability, craniosynostosis, speech delay,

delay in motor skills such as sitting and walking, underdeveloped fingertips or toes, missing "pinkie" fingernails or toenails, frequent respiratory infections in infancy, feeding difficulty in infancy, failure to thrive, short stature, low muscle tone, loose joints, eye abnormalities, heart abnormalities, brain abnormalities and kidney abnormalities [5,11]. These features present variably, and a high index of clinical suspicion, in addition to the exclusion of common clinical conditions, is required to make the diagnosis.

The final diagnosis requires Magnetic Resonance Imaging (MRI) or Computed Tomography (CT) and confirmatory gene analysis. In this patient, a Computed Tomography (CT) scan showed craniosynostosis. Computed Tomography (CT) is an excellent diagnostic test for bone-related conditions [12]. The most mutated genes in craniosynostosis were FGFR2, FGFR3, TWIST1, and EFN1. Craniosynostosis with ARID-2 mutations is rare [13]. Before gene analysis, only clinical suspicion was provided for diagnosis and treatment. Gene analysis is highly specific for diagnosing rare syndromes [14] and has enhanced the capacity to provide care for specific syndromes.

Treatment of coffin siris syndrome is nonspecific. Currently, only available treatment options are supportive. Conservative management and emotional support are the mainstays of current management. Current treatment aims to help the patient achieve an average growth rate, physical health, and mental health. Thus, tailored physiotherapy may be a helpful adjunct [15]. Simple passive movement exercises to improve muscle tone, and emotional support are crucial home care elements. Regular structured exercises are important for improvement in motor activities [16]. Caregivers can have a significant impact on improving the well-being of a child [17]. Regular follow-up and assessment of exercise efficiency is essential. Craniosynostosis can be corrected using surgery or special molding helmets. Indications for surgery include cosmetic improvement and, in some cases, to relieve the intracranial stress due to small cavity. Except for cosmetic improvement, however, no significant gains in cognitive outcomes were noted [18].

Supplemental nutrition may be appropriate for stimulating neurological growth and brain function [19]. Monthly follow-ups are required to assess improvement in growth rate. The presented case reported improved cognition and neuromuscular growth with supplemental nutrition and regular exercise. Despite the notable improvement, the prognosis for this patient remains uncertain. In the absence of long-term studies, information on the life span of Coffin-Siris syndrome is not available. Uncommonly, aspiration pneumonia and seizures have proved fatal for children with CSS [20]. Efforts are underway by the Coffin-Siris Syndrome International Consortium to obtain more data and find other treatment options.

Average life expectancy is unlikely. An underdeveloped cerebral cortex leads to growth abnormalities, feeding problems [21], poor nutrition, hearing abnormalities, ocular abnormalities, and frequent infections. While not noted here, some patients have cardiac defects such as ventricular septal defects, atrial septal defects, and patent ductus arteriosus. Renal and

genitourinary abnormalities such as horseshoe kidney and hypospadias might be present [5]. The treatment is problem specific. Periodic surveillance for eye disorders, scoliosis, hearing loss, behavior abnormalities, and hormonal imbalance/bone age is appropriate to prevent complications during childhood and adolescence [22].

### Conclusion

ARID-2 gene mutation in patients of CSS is uncommon. This study gives information regarding CSS, the genes involved, and the management of such rare conditions. This study can serve as a background for the diagnosis and management of Coffin-Siris syndrome.

### References

- Jensen R, Ira Herskowitz J. Five SW genes are required for expression of the HO gene in yeast. *lhi*. 1984; 178: 853-68.
- Alfert A, Moreno N, Kerl K. The BAF complex in development and disease. *Epigenetics Chromatin*. 2019; 12: 19.
- Bultman S, Gebuhr T, Yee D, la Mantia C, Nicholson J, et al. A Brg1 null mutation in the mouse reveals functional differences among mammalian SWI/SNF complexes. *Mol Cell*. 2000; 6: 1287-95.
- Matsumoto S, Banine F, Struve J, Xing R, Adams C, et al. Brg1 is required for murine neural stem cell maintenance and gliogenesis. *Dev Biol*. 2006; 289: 372-83.
- Schrier Vergano S, Santen G, Wiczorek D. Coffin-Siris syndrome. 2013.
- Boulet SL, Rasmussen SA, Honein MA. A population-based study of craniosynostosis in metropolitan Atlanta, 1989-2003. *Am J Med Genet A*. 2008; 146A: 984-91.
- Antwih DA, Gabbara KM, Lancaster WD, Ruden DM, Zielske SP. Radiation-induced epigenetic DNA methylation modification of radiation-response pathways. *Epigenetics*. 2013; 8: 839-48.
- Baccarelli A, Bollati V. Epigenetics and environmental chemicals. *Current Opinion in Pediatrics*. 2009; 21: 243-51.
- Cavalli G, Heard E. Advances in epigenetics link genetics to the environment and disease. *Nature*. 2019; 571: 489-99.
- Moore-Morris T, van Vliet PP, Andelfinger G, Puceat M. Role of Epigenetics in Cardiac development and congenital diseases. *Physiol Rev*. 2018; 98: 2453-75.
- Bramswig NC, Caluseriu O, Lüdecke HJ, v. Bolduc FV, Noel NCL, Wieland T, et al. Heterozygosity for ARID2 loss-of-function mutations in individuals with a Coffin-Siris syndrome-like phenotype. *Hum Genet*. 2017; 136: 297-305.
- Mehany SN, Patsch JM. Imaging of pediatric bone and growth disorders: of diagnostic workhorses and new horizons. *Wien Med Wochenschr*. 2021; 171: 102-10.
- Johnson D, Wilkie AOM. Craniosynostosis. *Eur J Hum Genet*. 2011; 19: 369-76.
- Marwaha S, Knowles JW, Ashley EA. A guide for the diagnosis of rare and undiagnosed disease: beyond the exome. *Genome Med*. 2022; 14: 23.
- Girolami GLPM, Campbell SKPPF. Efficacy\_of\_a\_Neuro\_Developmental\_Treatment.2. *Pediatr Phys Ther*. 1994: 175-84.
- Forsberg HA. A Neural control model for human locomotion development: implications for therapy. *Med Sport Sci*. 1992; 36: 174-81.
- Phommachanh S, Essink DR, Wright PE, Broerse JEW, Mayxay M. Maternal health literacy on mother and child health care: A community cluster survey in two southern provinces in Laos. *PLOS ONE*. 2021; 16: e0244181.
- Kyutoku S, Inagaki T. Review of past reports and current concepts of surgical management for craniosynostosis. *Neurol Med Chir (Tokyo)*. 2017; 57: 217-24.
- Kennedy DO. B vitamins and the brain: mechanisms, dose and efficacy—a review. *Nutrients*. 2016; 8: 68.
- Schrier SA, Bodurtha JN, Burton B, Chudley AE, Chiong MAD, et al. The Coffin-Siris syndrome: A proposed diagnostic approach and assessment of 15 overlapping cases. *Am J Med Genet A*. 2012; 158A: 1865-76.
- Rezaei M, Rashedi V, Gharib M, Lotfi G. Prevalence of feeding problems in children with intellectual disability. *Iran Rehabil J*. 2011; 9.
- Vergano SA, van der Sluijs PJ, Santen, ARID G. 1B-related disorder. 1993. Available from: <https://www.ncbi.nlm.nih.gov/books/>.