

Case Report

Topical Corticosteroid Use in Children Can Cause Blindness

Henriques S^{1*}, Xavier C², Vaz FT¹ and Brito C²

¹Department of Ophthalmology, Hospital Prof. Doutor Fernando Fonseca, Portugal

²Departamento de Ophthalmology, Centro Hospitalar Universitário de Lisboa Central, Portugal

*Corresponding author: Susana Pinto Henriques, Ophthalmology Department, Hospital Prof. Doutor Fernando Fonseca, E.P.E .IC 19, 2720-276 Amadora, Portugal

Received: April 01, 2020; Accepted: April 14, 2020;

Published: April 21, 2020

Abstract

Introduction: Glaucoma is a degenerative optic neuropathy, usually associated with elevated Intraocular Pressure (IOP), which causes progressive damage of neuronal cells that ultimately causes irreversible blindness. The use of corticosteroids may lead to glaucoma. In young children glaucoma may cause irreversible enlargement of the eye.

Case Report: A case is presented of an 8-month-old male medicated with topical corticosteroids for symptoms related to nasolacrimal obstruction of the left eye. He had an increase in the corneal diameter, axial length and a greater cup-disk ratio of the left eye. Although an elevated IOP was never observed after stopping corticosteroid, these signs might indicate there has been ocular hypertension in the past, much likely associated with corticosteroids.

Discussion: Whenever possible corticosteroids should be avoided, especially in children, where their effect on IOP may be greater. If not possible, regular ophthalmologic evaluation and IOP monitoring is crucial, since devastating ocular changes and blindness can occur.

Keywords: Corticosteroids; Glaucoma; Glaucoma risk; Steroid-induced glaucoma; Pediatric glaucoma

Case Presentation

An 8-month-old male was medicated since newborn with a combination of prednisolone, neomycin and polymyxin B (Conjunctilone-S[®], Allergan) eye drops, twice a day, for presumed epiphora and recurrent conjunctivitis related to obstruction of the nasolacrimal canal of the Left Eye (LE).

The patient was referred to an ophthalmologist because recurrent bilateral conjunctivitis and a suspicion of progressive enlargement of the LE (Figure 1). Topical medication was withdrawn and lacrimal pathway was probed with resolution of signs of obstruction. The observation under general anesthesia was performed, which showed transparent corneas, IOP of 8mmHg on the Right Eye (RE) and 10mmHg on the LE, a corneal diameter of 12mm (RE) and 13mm (LE) and axial length of 21.15mm (RE) and 22.50mm (LE). Fundoscopy showed no excavation on RE and a greater cup-disk ratio on the LE of 0.4 (Figure 2). Gonioscopy showed an open angle 360° on both eyes. The objective refraction under cycloplegia was +3.00 (RE) and +1.00-0.50x180° (LE). Although the IOP was within normal values, there was an asymmetry of the eyeballs, with buphthalmos and a greater cup-disk ratio of the LE, suggestive of glaucoma.

Subsequent observations were similar, with no significant changes occurring. At 14 months, Visual Acuity (VA) was evaluated using preferential looking tests. The result was 20/94 (normal) for the RE and 20/190 (low) for the LE. He started part-time occlusions of the RE and at 4 years-old his VA was 20/20 in both eyes.

Genetic tests were performed and the following changes were found: c.187A>Gly in the OPTC gene in heterozygosity and c.514G>A in the RRM2B gene in heterozygosity.

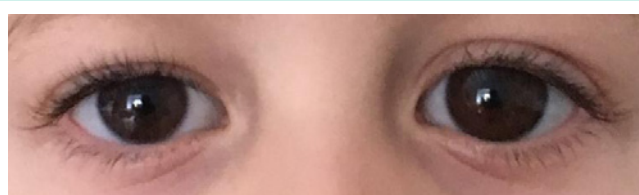


Figure 1: Photography of both eyes, showing an enlargement of the LE.

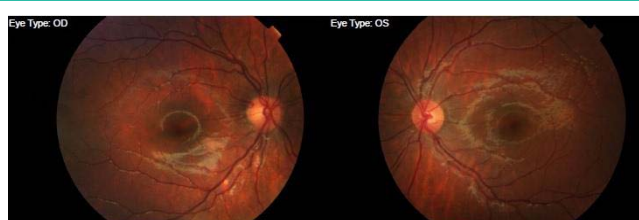

Figure 2: Fundoscopy of both eyes, showing a greater cup-disk ratio on the LE.

Discussion/Conclusion

Glaucoma is a degenerative optic neuropathy, in which there is loss of nerve cells, leading to progressive and irreversible visual field loss and potentially blindness. Usually, it is associated with elevated Intraocular Pressure (IOP). Aqueous humor is a clear liquid that fills the entire anterior segment of the eye and is drained outward through a porous site at the level of the iridocorneal angle - trabecular meshwork. If there is obstruction to this drainage, IOP can rise, inducing compression of optic nerve.

Glaucoma in the pediatric age differs from adult glaucoma. Until 3 years old connective tissue constituents of the eye are immature so the eye can become enlarged with an increase in IOP [1]. This enlargement of the cornea and anteroposterior diameter of the eye causes buphthalmos and ultimately optic nerve damage. Also, amblyopia can be a problem due to the axial myopia, even if increased IOP can be addressed.

Although glaucoma is rare in children, it could have several causes. The most common entity is primary congenital glaucoma, that results from an abnormal development of the iridocorneal angle with a decrease in outflow [2]. Whatever the cause is, the manifestations of glaucoma can be similar - enlargement of the eye (megalocornea, buphthalmos), edema of the cornea (reduced transparency, tearing, photophobia) and signs of poor vision (nystagmus, strabismus). Steroid-induced glaucoma is due to an increase in resistance in the aqueous humor drainage pathways secondary to deposition of glycosaminoglycans in the extracellular matrix and inhibition of phagocytic and protease activity [3,4].

The onset, duration and magnitude of steroids responsiveness in terms of IOP increase, depend on the type and anti-inflammatory potency of the corticosteroid, the frequency and mode of administration, and the individual's susceptibility [3-5]. Although all people have the potential to develop corticosteroid-induced glaucoma, some have particular susceptibility: existence of Primary Open-Angle Glaucoma (POAG), first-degree relative with POAG, glaucoma suspect, previous steroid response, age, connective tissue disease, high myopia, type 1 diabetes, ocular inflammation or drainage injury [3,4].

It has been shown that children are more susceptible than adults [4,6,7], with the increase of IOP and consequent glaucomatous damage being more frequent, more severe, rapidly progressive and earlier in onset [4,5]. Some corticosteroids such as prednisolone and dexamethasone are more prone to cause an increase in IOP, and others such as fluorometalone, rimexolone, medrisone, loteprednol and hydrocortisone are safer, although the risk is not negligible [3,4]. Of the various routes of administration, topical administration on eye most commonly causes an increase in IOP [5], but application on skin can also affect IOP depending on duration of use and body surface area to which the ointment is applied [5]. Although less common with systemic, inhaled and intranasal administration, increase in IOP can occur [4].

The IOP elevation can occur in a few hours or months to years after the administration of corticosteroids. If administered topically, it usually occurs in 1-4 weeks, and after discontinuation, the resolution typically "mirrors" the onset. Rarely, IOP remains persistently elevated for months or years after discontinuation, perhaps as a result of some damage to the drainage pathway [5].

Although an elevated IOP or glaucoma progression signs were never observed in our patient, the presence of buphthalmos and a raise in the cup-disc ratio on the LE are indirect signs which make us presume there was ocular hypertension much likely related with topical steroids use.

Our patient has a heterozygous mutation on the *OPTC* gene, that has been associated to POAG. The finding of this mutation may suggest that this is a risk factor for high steroids responsiveness.

Steroid-induced glaucoma in the paediatric population is devastating and can cause childhood blindness and other lifelong consequences. Whenever possible, the use of corticosteroids must be avoided but, if needed, it's imperative to be prescribed and monitored by an ophthalmologist, for regular measurement of IOP whenever possible and observation of the optic nerve and other ocular manifestations of an IOP increase.

IOP elevation in children requires timely management [4]. The treatment of this condition consists on discontinuation of corticosteroids, or if it's not possible, a dose reduction or replacement by less potent steroids. Antiglaucomatous medications or eventually surgery, may be required [8].

Steroid-induced glaucoma can develop rapidly and asymptotically without frank signs such as buphthalmos, photophobia, and epiphora. Therefore, corticosteroids should be used with caution and regular ophthalmologic evaluation is crucial to detect potentially damaging IOP elevation.

Learning Points

- The use of corticosteroids may lead to glaucoma and steroid-induced glaucoma in the paediatric population is devastating and can cause childhood blindness.
- Children are more susceptible than adults, with the increase of intraocular pressure and consequent glaucomatous damage being more severe.
- All types of corticosteroids and all routes of administration, including application on skin, can affect intraocular pressure.
- Whenever possible corticosteroids should be avoided, especially in children, where their effect on intraocular pressure may be greater.
- Corticosteroids should be used with caution and regular ophthalmologic evaluation is crucial to detect potentially damaging intraocular pressure elevation.

References

1. Al-Shahwan S, Khan AO. Buphthalmos following systemic steroid treatment. *J Pediatr Ophthalmol Strabismus*. 2006; 43: 311-312.
2. Lewis CJ, Hedberg-Buenz A, DeLuca AP, Stone EM, Alward WLM, Fingert JH. Primary congenital and developmental glaucomas. *Hum Mol Genet*. 2017; 26: R28-R36.
3. Piltz-Seymour J, Tania Tai TY. *Other Secondary Glaucomas*. Second Edition. Elsevier Ltd. 2014; 1:
4. Nuyen B, Weinreb RN, Robbins SL. Steroid-induced glaucoma in the pediatric population. *J AAPOS*. 2017; 21: 1-6.
5. Shaarawy T, Sherwood M, Hitchings RCJ. Corticosteroid-Induced Glaucoma. In: *Glaucoma Medical Diagnosis and Therapy*. 2009; 1: 2651-2657.
6. Hutcheson KA. Steroid-induced glaucoma in an infant. *J AAPOS*. 2007; 11: 522-523.
7. Kaur S, Dhiman I, Kaushik S, Raj S, Pandav SS. Outcome of Ocular Steroid Hypertensive Response in Children. *J Glaucoma*. 2016; 25: 343-347.
8. Feroze KB, Khazaeni L. *Steroid Induced Glaucoma*. StatPearls Publishing. 2020.