

## Special Article - Adverse Reaction

## Foreign Body Granuloma after Filler with Polymethyl Methacrylate (PMMA)

Bravo BF<sup>1\*</sup> and Rocha CRM<sup>2</sup>

<sup>1</sup>Instituto de Dermatologia Professor Rubem David Azulay, Santa Casa da Misericórdia do Rio de Janeiro and Hospital Federal da Lagoa – Rio de Janeiro, Brazil  
<sup>2</sup>Dermatologist, Hospital Federal da Lagoa, Rio De Janeiro, RJ, Brazil

\*Corresponding author: Bravo BF, Instituto de Dermatologia Professor Rubem David Azulay, Santa Casa da Misericórdia do Rio de Janeiro and Hospital Federal da Lagoa – Rio de Janeiro, Brazil

Received: April 04, 2017; Accepted: May 17, 2017;

Published: May 24, 2017

## Case Presentation

A 58-year-old female patient, with a complaint of “inflammatory nodules on the face” that began about a month ago. She complained of painful nodules in the malar region and bilateral nasogenic sulcus. Denied fever or other systemic symptoms. She had been submitted to filling with Polymethyl methacrylate (PMMA) 15 years ago in the nasolabial sulcus region. Eighteen months before was submitted to malar and zygomatic filler with hyaluronic acid of high density (20 mg/mL). When she arrived at the clinic, she had been using Clindamycin for 14 days and oral corticosteroid for 30 days, already weaned. She used eye drops for ocular hypertension and had hormone replacement. On clinical examination she presented painful nodules in the malar region and bilateral nasogenic sulcus, measuring between one and 2 centimeters (Figures 1,2,3). Imaging examinations of the nodular lesions were requested. The patient underwent ultrasonography, which was: hyperechoic, oval, expansive, restricted to the subcutaneous tissue, angular artery permeating the lesions, with bilaterally preserved flow, caliber and pathway. Doppler ultrasound showed an accentuation of diffuse vascularization of the lesions. Computed tomography of the region showed high density images, partially defined limits, located in the subcutaneous regions of the malar regions and nasogenic sulcus, without signs of an acute inflammatory process. Infection sites were investigated with general laboratory tests, chest x-ray, EAS, and infection was excluded. The main diag-nostic hypothesis was an inflammatory reaction after filling with hyaluronic acid, both in the region of the AH injection and in which PMMA was in-jected. Thus, systemic antibiotic therapy (ciprofloxacin 500 mg 12/12 hours) and application of 300 UI of hyaluronidase in the area that had been filled with hyaluronic acid were chosen. Hyaluronidase was applied 15 days after initiation of ciprofloxacin. After the application, oral antibiotic therapy was continued for another 15 days. Thus, the hyaluronic acid dilution of the malar and zygomatic region was performed, reducing the inflammatory reaction in this place and also in the one in which the PMMA was applied. After dilution, the patient remained on allopurinol 200 mg / day for anti-inflammatory purposes. However, the patient remained with the noninflammatory nodules in the

## Abstract

Soft tissue fillers are a safe option for treatment and rejuvenation, but complications can occur. The formation of nodules or granulomas is one of the most commonly long-term complications. We report a case of a patient that was submitted to a nasogenic sulcus filling with PMMA 15 years ago that developed a possible foreign body granuloma after a new procedure where she was submitted so alar and zygomatic filling with hyaluronic acid years after the first procedure.

**Keywords:** Granuloma; Filling; PMMA

nasolabial sulcus region after the treatment, leaving as a possible foreign body granuloma diagnosis (Figures 4).

## Discussion/Conclusion

Soft tissue fillers are a safe option for soft tissue augmentation when performed by experienced physicians, in the appropriate patients, with the correct agents and proper techniques. While complications can occur, it's necessary to develop the ability to recognize and manage them.

The formation of nodules or granulomas is one of the most commonly long-term complications associated with filler implants, the overall incidence is variable and depends on the location and agent used [1,2,3]. These nodules can be painful, debilitating, and both psychologically scarring and should be treated swiftly. Several options are currently available for treatment; however, these largely depend on the agents used and extent of the disease.

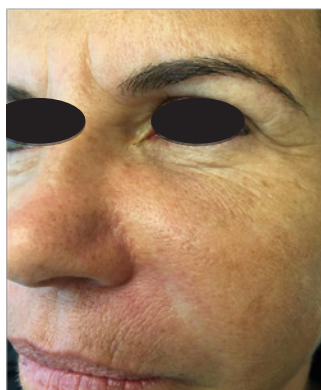
Both nodules and foreign body granulomas are terms that have been used for palpable lesions noted after filler injections. These terms were once used interchangeably, but they are now used with distinct meanings [4]. Unfortunately, delay in diagnosing adverse events such

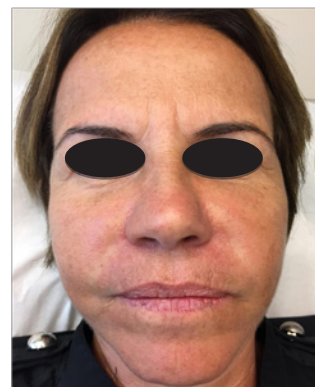
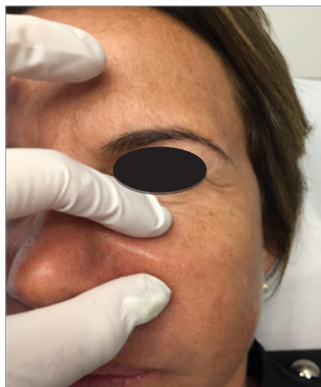
Figure 1: Patient on first visit, showing inflammatory nodules in the malar region and nasogenic sulcus.



**Figure 2:** Palpation of the inflammatory nodules in the malar region.



**Figure 3:** Inflammatory nodules in the malar region.

as nodule, granuloma, or sterile abscess formation may be a result of many factors, including patients' neglect to inform their physicians of past soft-tissue augmentation, leading to misdiagnoses. Therefore, timely recognition, diagnosis, and appropriate management are of the utmost importance [5,6].

It is of utmost importance to know the clinical and histological difference between nodules and granulomas, because corticosteroids are effective in cellular proliferations but not in nodules of clumped particles or microspheres [7].

Nodules appear solely and early, most often within the first four weeks after injection when the swelling is gone. They are hard, not growing, noninflammatory, occur solitary, well confined, do not grow and do not disappear on their own. Their histology shows foreign body reaction and particles or microspheres packed. Nodules are caused often by technical errors or intramuscular injection. They react seldomly to cortisone injections and should eventually be surgically removed.

A foreign body granuloma is a non-allergic chronic inflammatory reaction that is mainly composed of multinucleated giant cells. Foreign body granulomas may occur after the administration of any dermal filler and the volume of the injection, impurities present in the fillers, physical properties of fillers can affect granuloma formation. The clinical and pathologic features of granulomas vary depending on the type of filler that causes them.

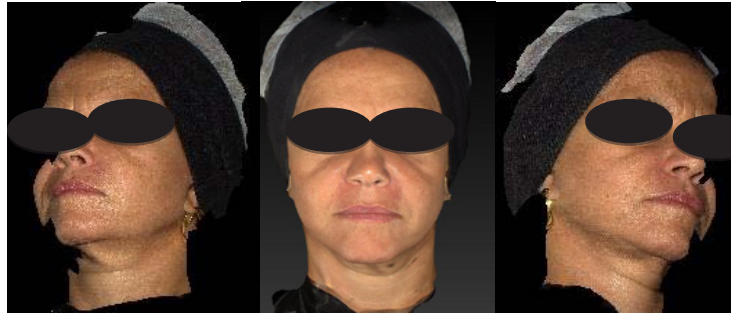Granulomas occur late, after 6 months to 6 years at all injected sites simultaneously and are often inflammatory. They grow rather fast and react well to intralesional steroid injections and mainly consist of macrophage invasion and fibroblast multiplication with little effect on the filler substance. Although cosmetic procedures performed by non-physicians and/or inexperienced physicians have been implicated in the majority of soft tissue complications, granulomatous reactions can occur even when appropriate techniques and medical approved, certified formulations are injected [8]. The reason for the sudden onset of granulomas even after a long time may be the memory activation of macrophages, which are suddenly stimulated by a trigger [9]. The cause for their development is still unclear, but systemic infections, trauma, or surgery approximately 3 months before their onset have been suggested to stimulate the memory of macrophages, which suddenly attack the so far tolerated foreign, injected material [10].

In some patients carrying permanent filler that has remained asymptomatic for many years, the local injection of a second material triggers an inflammatory reaction against both of them that can be identified in the same microscopic field. An acute inflammatory process involving a quiescent granuloma years after the injection can also be envisaged. This reaction might be related to the development of bacterial biofilms, or structured colonies of microorganisms encapsulated in an extracellular matrix that can surround a foreign body and can lead to a low-grade chronic infection with eventual spontaneous or injury-mediated reactivation after repeated injections [11].

The goal in the treatment of granulomas must be to stop the invasion and proliferation of cells and the increased secretion of interstitial substances without leaving a scar. Triamcinolone and other steroids decrease both cellular proliferation and collagen production by dermal fibroblasts. Surgical excisions of granulomas tend to be incomplete because granulomas have ill-defined borders and moreover, surgical excisions may leave scars and deformities.

While it has been reported that PMMA granulomas may spontaneously resolve after 2–3 years, corticosteroids, surgical excision, or superficial dermabrasion can augment reduction of these lesions if they are bothersome to the patient [12,13,14]. Less invasive techniques such as oral antibiotics or intralesional corticosteroids are recommended prior to surgical excision, with oral antibiotics considered first-line treatment [15]. The excision of foreign body granulomas is not a therapy of first choice because the complete removal of a granuloma is impossible in many cases. PMMA nodules have been shown to respond to intralesional corticosteroids; systemic corticosteroids may also lead to some improvement, but lesions may recur with cessation of treatment [16,17,18]. Allopurinol has also been reported to be effective for symptomatic treatment of PMMA nodules that developed on the face following scar revision in some cases; however, lesions may remain palpable [18,19].

In the case described, the patient developed inflammatory nodules after filling with hyaluronic acid. She developed the lesions not only at the site of the last procedure, but also in the one that had previously been filled with PMMA. With the development of inflammatory nodules of late origin the biofilm hypothesis was raised. This delayed reaction could be triggered by a systemic infection or even the new



**Figure 4:** The patient before treatment, in the photos above, The patient after the treatment, in the photos below. In the first photos, showing inflammatory nodules in the malar region and nasogenian sulcus. In the latest photos, there's an improvement of the lesions, but the non inflammatory nodules in the nasolabial sulcus are still present.

procedure with hyaluronic acid. In this case, the hypothesis of systemic infection was excluded after the clinical history and the laboratory research. The new procedure with the use of hyaluronic acid may have served as a trigger for the development of this systemic reaction, as already mentioned in the literature.

Thus, it was decided to use oral antibiotics for 15 days to treat a possible bio-film. After the initial 15 days, dilution of the hyaluronic acid injected into the malar and zygomatic region was performed with local application of 300 IU of hyaluronidase throughout the filled area in order to eliminate this other sub-stance, thus reducing the inflammatory reaction in the other sites. The use of oral allopurinol 200 mg/day, with an anti-inflammatory aim, was also mentioned in the literature as treatment of inflammatory reactions related to permanent fillers. Soon after, the antibiotic therapy was maintained for another 15 days. The patient showed significant improvement, with complete improvement of the inflammatory reaction. Despite this, she remained with noninflammatory nodular lesions in the nasolabial sulcus region bilaterally. Therefore, the hypothesis of foreign body granuloma in this region was suggested. From this, a treatment with local corticosteroid infiltration could be proposed.

This case illustrates the care we should take when performing procedures in patients who have previously performed some other procedure. Although there are several complications that we can predict and avoid taking certain care, some others, such as granulomatous reactions, are unpredictable and we must be aware and clearly inform the patient that they can happen.

## References

- Braun M, Braun S. Nodule formation following lip augmentation using porcine collagen-derived filler. *J Drugs Dermatol.* 2008; 7: 579-581.
- Bello G, Jackson IT, Keskin M, Kelly C, Dajani K, Studinger R, et al. The use of polyacrylamide gel in soft-tissue augmentation: an experimental assessment. *Plast Reconstr Surg.* 2007; 119: 1326-1336.
- Pallua N, Wolter TP. A 5-year assessment of safety and aesthetic results after facial soft-tissue augmentation with polyacrylamide hydrogel (Aquamid): a prospective multicenter study of 251 patients. *Plast Reconstr Surg.* 2010; 125: 1797-1804.
- Lee JM, Kim YJ. Foreign body granulomas after the use of dermal fillers: pathophysiology, clinical appearance, histologic features, and treatment. *Arch Plast Surg.* 2015; 42: 232-239.
- Ledon JA, Savas JA, Yang S, Franca K, Camacho I, Nouri K. Inflammatory nodules following soft tissue filler use: a review of causative agents, pathology and treatment options. *Am J Clin Dermatol.* 2013; 14: 401-411.
- Vent J, Lemperle G. Prevention and treatment of complications after Polymethyl methacrylate-microspheres injections. *Facial Plast Surg.* 2014; 30: 628-634.
- Lemperle G, Nicolau P, Scheiermann N. Is there any evidence for biofilms in dermal fillers?. *Plast Reconstr Surg.* 2011; 128: 84-85.
- Ellis LZ, Cohen JL, High W. Granulomatous reaction to silicone injection. *J Clin Aesthet Dermat.* 2012; 5: 44-47.
- Lemperle G, Gauthier-Hazan N, Wolters M, Eisemann-Klein M, Zimmermann U, Duffy DM. Foreign body granulomas after all injectable dermal fillers: part 1. Possible causes. *Last Reconstr Surg.* 2009; 123: 1842-1863.
- Vent J, Lefarth F, Massing T, Angerstein W. Do you know where your fillers go? An ultrastructural investigation of the lips. *Clin Cosmet Investig Dermatol.* 2014; 7: 191-199.
- Christensen L, Breiting V, Janssen M, Vuust J, Hogdall E. Adverse reactions to injectable soft tissue permanent fillers. *Aesthetic Plast Surg.* 2005; 29: 34-48.
- Broder KW, Cohen SR. ArteFill: a permanent skin filler. *Expert Rev Med Devices.* 2006; 3: 281-289.
- Hoffmann C, Schuller-Petrovic S, Soyer HP, Kerl H. Adverse reactions after cosmetic lip augmentation with permanent biologically inert implant materials. *J Am Acad Dermatol.* 1999; 40: 100-102.
- Lemperle G, Romano JJ, Busso M. Soft tissue augmentation with artecoll: 10-year history, indications, techniques, and complications. *Dermatol Surg.* 2003; 29: 573-587.
- Park TH, Seo SW, Kim JK, Chang CH. Clinical experience with Polymethyl methacrylate microspheres filler complications. *Aesthetic Plast Surg.* 2012; 36: 421-426.
- Cohen SR, Berner CF, Busso M, et al. ArteFill: a long-lasting injectable wrinkle filler material-summary of the U.S. Food and Drug Administration trials and a progress report on 4- to 5-year outcomes. *Plast Reconstr Surg.* 2006; 118: 64-76.
- Pearl RM, Laub DR, Kaplan EN. Complications following silicone injections for augmentation of the contours of the face. *Plast Reconstr Surg.* 1978; 61: 888-891.
- Reisberger EM, Landthaler M, Wiest L, Schroder J, Stolz W. Foreign body granulomas caused by polymethylmethacrylate microspheres: successful treatment with allopurinol. *Arch Dermatol.* 2003; 139: 17-20.
- de Barros Silveira LK, de Oliveira FL, Alves Tde B, Rambaldi ML, de Andrade FC, Kelmer Sde C, et al. The therapeutic benefit of allopurinol in the treatment of foreign body granulomas caused by Polymethyl methacrylate microspheres. *Case Rep Dermatol Med.* 2012; 2012: 945205.