

Clinical Image

A Queer Foreign Body

Elena Coccolini¹, Luca Ansaloni², Roberto Manfredi², Giulia Montori², Marco Ceresoli² and Federico Coccolini^{2*}

¹Department of Pediatric, Modena University Hospital, Italy

²Unit of General and Emergency Surgery, Papa Giovanni XXIII Hospital, Italy

*Corresponding author: Federico Coccolini, Unit of General and Emergency Surgery, Papa Giovanni XXIII Hospital, P.zza OMS 1, 24128 Bergamo, Italy

Received: March 23, 2015; Accepted: March 24, 2015;

Published: March 26, 2015

Keywords

Foreign body; Child; Treatment

Clinical Image

A 9 years old boy came to the Emergency Department for referred ingestion of a metal crucifix. The first X-ray of the abdomen (Figure 1) documented the foreign body (maximal longitudinal Ø 3 cm x 1,5 cm) into the gastric antrum, at the level of left transverse apophysis of L3. After 12 hours fasting, the removal through endoscopy failed because of the presence of a big amount of food into the stomach. The second abdomen X-ray after 16 hours demonstrated the presence of the metal crucifix into the right iliac fossa (Figure 2). The crucifix was expelled 3 days later without damage. Peculiar in this case is the autonomus expulsion of the foreign body. In fact in case like this usually the endoscopic removal enters in the emergency maneuvers. The children digestive tract in fact has a diameter that doesn't allow to such big foreign body to pass through.

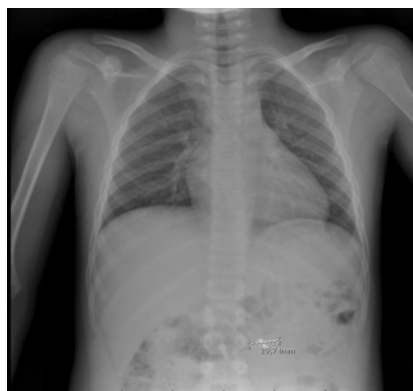

Figure 1: The foreign body in the stomach.

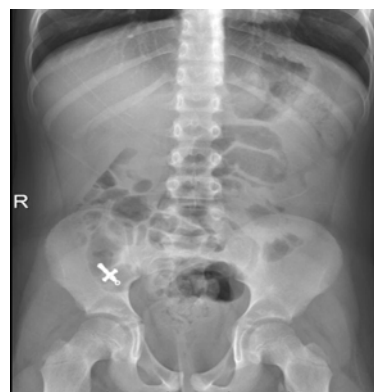


Figure 2: The foreign body in the right iliac fossa.