

Clinical Image

Unexpected Esophageal Impaction of a Chicken Bone

Chee Hwee Lee and Wing P Chan*

Department of Radiology, Wan Fang Hospital, Taipei Medical University, Taiwan

*Corresponding author: Wing P Chan, Department of Radiology, Wan Fang Hospital, Taipei Medical University, 111 Hsing-Long Road, Sec 3, Taipei 116, Taiwan

Received: September 08, 2015; Accepted: September 18, 2015; Published: September 24, 2015

Keywords

Esophagus; Foreign body; Chicken bone

Clinical Image

An old-age healthy woman visited the emergency department with a complaint of dysphasia and a sensation of “food sticking” in her throat for hours after dinner. On presentation, the patient appeared afebrile and normotensive. The neck was soft, without tenderness or erythematous change in the skin. A soft-tissue lateral neck radiograph showed a linear radiopaque density (Figure 1A), anterior to the C7 vertebra, and mild prevertebral soft-tissue swelling. Under the impression of foreign body impaction, a gastroenterologist was consulted for endoscopic retrieval of the foreign body, which was found in the upper cervical esophagus near the cricopharyngeus muscle (Figure 1B). The retrieved foreign body was a fragment of chicken bone (Figure 1C), ingested by the patient during a meal. The patient’s symptoms were relieved immediately by the procedure and she was followed up in the clinic.

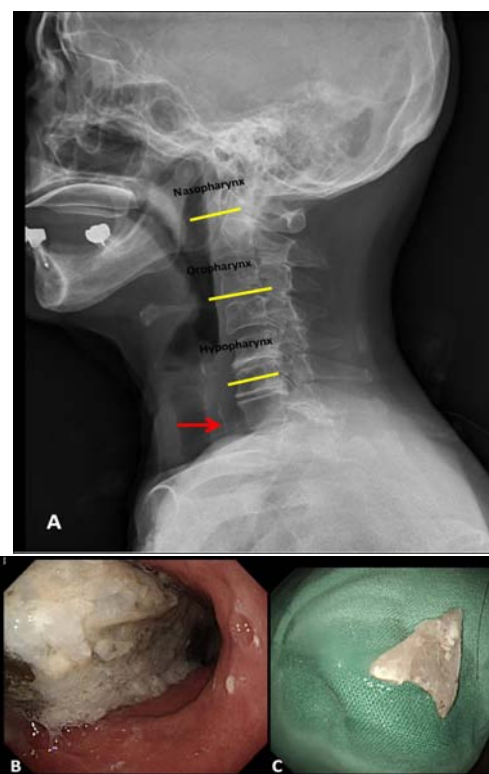


Figure 1: (A) Lateral soft-tissue projection of the neck radiograph shows a linear foreign body impaction (arrow) in the upper cervical esophagus. (B) Endoscopic retrieval of the foreign body near the cricopharyngeus muscle of the esophagus was noted. (C) The foreign body was found to be a fragment of chicken bone.