

Case Report

Melanoma Arising from “Ambiguous” Areas with Clinically Evident Unilateral Node Metastases Role of Lymphoscintigraphy and Sentinel Node Biopsy in Detection of Contralateral Occult Metastases Report of Two Cases

Dario Piazzalunga^{1*}, Barbara Merelli², Eugenio Maria Poletti De Chaurand¹ and Luca Ansaloni¹

¹General Surgery Unit, Papa Giovanni XXIII Hospital, Italy

²Oncology Unit, Papa Giovanni XXIII Hospital, Italy

*Corresponding author: Dario Piazzalunga, General Surgery Unit, Papa Giovanni XXIII Hospital, Bergamo, Italy

Received: July 12, 2016; Accepted: August 05, 2016;

Published: August 08, 2016

Abstract

Melanoma arising from areas with ambiguous lymphatic drainage can metastasize to multiple lymph node basins. When unilateral node metastases are clinically evident, one could underestimate the possibility of contralateral occult node localizations, leading to under treatment and future node relapse in the untreated basin.

Preoperative lymphoscintigraphy and Sentinel Node Biopsy (SNB) can help to identify that localization, addressing the correct therapy.

We describe two cases in which melanoma arising from the midline with evident unilateral node metastasis had also contralateral occult node localization. In these cases lymphoscintigraphy could detect the lymphatic pathway and SNB could identify the subclinical localizations, leading to a correct staging and to the correct radical therapy.

Keywords: Melanoma; Sentinel node; Lymphoscintigraphy

Introduction

The knowledge of the functional anatomy of the lymphatic drainage of the skin is crucial for the comprehension of the metastatic pathways of cutaneous melanoma and for the addressing of the optimal staging and therapy.

In 1874 Sappey [1] investigated lymphatic drainage in cadavers and published his results in an extensive Lymphatic Atlas. He claimed that lymphatic drainage of the skin was symmetric, never crossing the vertical midline or a horizontal line drawn across the waist (so-called Sappey's lines).

With these assumptions it would be possible to predict lymphatic drainage of any trunk area towards axilla or groin nodes.

These concepts were questioned in the latest years of the last century. In 1976 Sugarbaker and McBride [2] showed that lymphatic drainage was unpredictable from a strip of skin 2,5 cm wide on either side of Sappey's lines. Additional investigation demonstrated further variability of skin lymphatic drainage [3-5]. In 1991 Norman [6] expanded the area of ambiguous drainage on the trunk, up to 11 cm on either side of Sappey's lines.

The introduction of lymphoscintigraphy and SNB in the 1990s led to the observation that lymphatic drainage is highly variable between patients, especially in head&neck and trunk melanomas. The Sidney Melanoma Unit studies [7,8] and those in other Centers [9-11] showed that Sappey's guidelines would predict the drainage to the wrong field in 30% of cases. Particularly, Stadius Muller et al. [12]

showed that trunk drainage predictability depends to the location of the primary tumor, ranging from 0% in the midline to 92% in the upper quadrants.

SNB is now considered the standard procedure in the detection of lymph node involvement in melanoma. Other procedures such as preoperative high-resolution Ultrasound (US) examination and fine needle biopsy did not show the same accuracy.

Starritt [13] found that US results were suggestive of metastatic disease only in 7/33 positive node fields identified by lymphoscintigraphy and SNB. The threshold size of metastatic deposit in sentinel nodes able to be detected by US was 4,5 mm. Similarly, Sanki [14] found that the sensitivity of targeted US in the detection of positive sentinel nodes was 24.3% and the specificity was 96.8%. Both these studies conclude that US is not an appropriate substitute for SNB.

Materials and Methods

Case 1

M.M., male, 56 y.o., who presented with a midline ipogastric cutaneous lesion that was biopsied with evidence of malignant melanoma. There was a clinically palpable right inguinal adenopathy, while nothing was evident in the left side.

A preoperative CT scan confirmed the evidence of an enlarged right inguinal node; no pathologic findings were described in the left side.

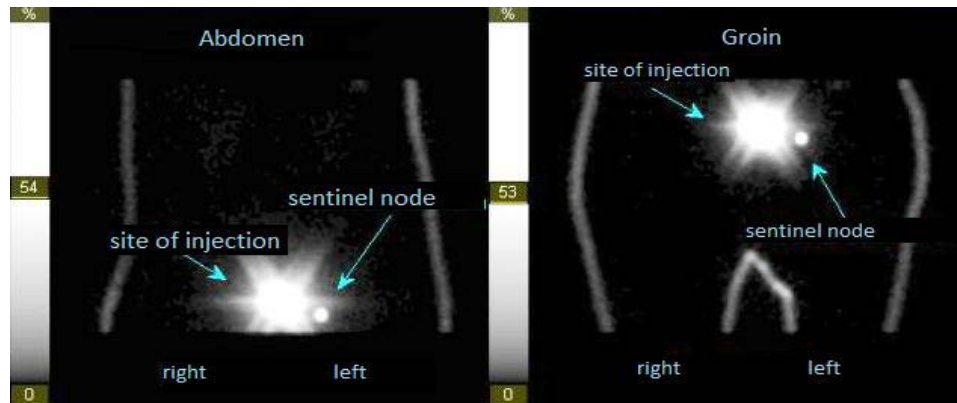


Figure 1: Lymphoscintigraphy of a cutaneous midline lesion showing drainage to the left groin.

Preoperative lymphoscintigraphy (Figure 1) showed drainage of the radiotracer only to the left groin; we then performed the radical excision of the primary melanoma, the biopsy of the enlarged right inguinal node and the SNB on the contralateral side. The pathologic report showed an ulcerated melanoma with Breslow thickness of 4,35 mm; both the right and the left inguinal node biopsies were positive for melanoma metastasis. The patient was subsequently submitted to radical bilateral inguinal and pelvic dissection, with the finding of 4/33 metastatic nodes on the right and 16 free nodes on the left.

The postoperative course was uncomplicated.

Case 2

N.F., male, 59 y.o., who presented after the removal of a 3 cm polypoid anal tumor who was found to be a malignant polypoid melanoma with mitotic index of 10/mm² and Ki67 of 70%, with focal involvement of the margins of resection. Right inguinal enlarged nodes were clinically evident, while nothing was evident on the left side.

We performed a fine needle biopsy of one enlarged right inguinal node that was positive for metastasis. The preoperative CT scan confirmed the pathologic right inguinal nodes, with no pathologic findings on the left side.

A preoperative lymphoscintigraphy (Figure 2) show drainage of the tracer both to right and left groin; a left groin SNB was then performed, leading to the finding of micro metastases (0,4 and 0,6 mm) to both of the biopsied nodes. We performed an abdominoperineal rectal resection with terminal iliac colostomy and bilateral radical inguinal and pelvic dissection, with the finding of 4/11 positive nodes in the mesorectum, 6/15 positive right inguinoiliac nodes and 3/12 positive left inguinoiliac nodes.

The postoperative course was complicated by the perineal wound dehiscence that was treated with VAC therapy leading to complete healing in 4 weeks.

Discussion

The role of lymphoscintigraphy in the knowledge of the functional anatomy of the lymphatic vessels draining the skin has been widely highlighted in the Literature. His importance lies in the ability to identify the correct nodal basin draining the site of the primary

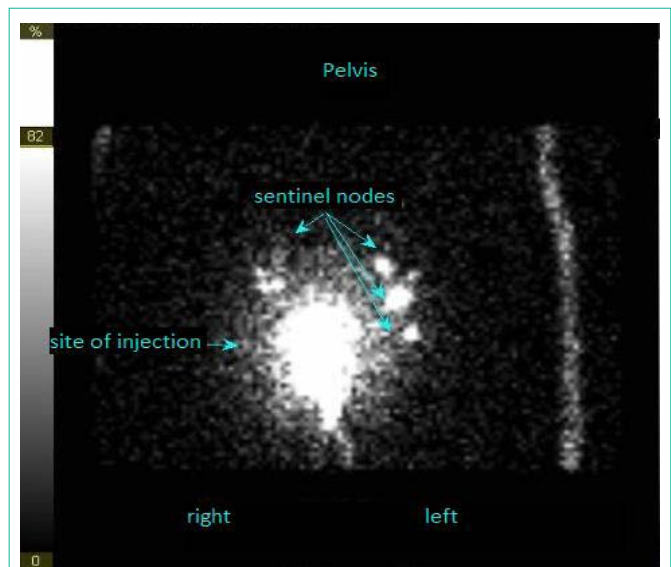


Figure 2: Lymphoscintigraphy of an anal lesion showing drainage mainly to the left groin and lesser to the right one.

tumor, especially in “ambiguous” areas like head and neck and trunk.

In the two cases described above, there was clinical evidence of unilateral nodal metastasis. Avoiding using lymphoscintigraphy in these cases could have lead to the underestimation of the involvement of the contralateral nodes and to an incorrect treatment.

Similarly, we do not agree with those [14] who claim that US of the regional lymph nodes with US-guided biopsy could address the safe selection of patients who should proceed directly to a complete regional lymphadenectomy.

We also observed that lymphoscintigraphy alone could have missed the clinically palpable metastases at least in one of the two cases. The drainage of the radiotracer was exclusively contralateral to the palpable nodes in one case and mainly contralateral in the other one.

This observation supports the hypothesis for which false negative sentinel node biopsies could be due to the changes of the lymphatic flow in the presence of massive lymphatic metastases.

Lymphoscintigraphy taught us that a melanoma arising near the midline can drain to both the left and the right side. A fortiori, we must not forget to use it even in cases when unilateral metastases appear to be obvious.

References

1. Sappey MPC, Anatomie, physiologie, pathologie des vaisseaux lymphatiques considérés chez l'homme et les vertébrés, Ed. Delahaye. Paris. 1874.
2. Sugarbaker EV, McBride CM, Melanoma of the trunk: the results of surgical excision and anatomic guidelines for predicting nodal metastasis, *Surgery*. 1976; 80: 22-30.
3. Fee HJ, Robinson DS, Sample WF, Graham LS, Holmes EC, Morton DL. The determination of lymph shed by colloidal gold scanning in patients with malignant melanoma: a preliminary study. *Surgery*. 1978; 84: 626-632.
4. Meyer CM, Lecklitner ML, Logic JR, Balch CE, Bessey PQ, Tauxe WN. Technetium-99m sulfur-colloid cutaneous lymphoscintigraphy in the management of truncal melanoma. *Radiology*. 1979; 131: 205-209.
5. Eberbach MA, Wahl RL. Lymphatic anatomy: functional nodal basins. *Ann Plast Surg*. 1989; 22: 25-31.
6. Norman J, Cruse W, Espinosa C, Cox C, Berman C, Clark R, et al. Redefinition of cutaneous lymphatic drainage with the use of lymphoscintigraphy for malignant melanoma. *Am J Surg*. 1991; 162: 432-437.
7. Thompson JF, Uren RF. Lymphatic mapping in management of patients with primary cutaneous melanoma. *Lancet Oncol*. 2005; 6: 877-885.
8. Reynolds HM, Walker CG, Dunbar PR, Michael J O'Sullivan, Roger F Uren, John F Thompson, et al. Functional anatomy of the lymphatics draining the skin: a detailed statistical analysis. *J Anat*. 2016; 216: 344-355.
9. Leon SP, Acthem TA, Habib FA, Steinmetz I, Morita E, Allen RE, et al. Discordancy between clinical predictions vs lymphoscintigraphic and intraoperative mapping of sentinel lymph node drainage of primary melanoma. *Arch Dermatol*. 1999; 135: 1472-1476.
10. O'Toole GA, Hettiaratchy S, Allan R, Powell BW. Aberrant sentinel nodes in malignant melanoma. *Br J Plast Surg*. 2000; 53: 415-417.
11. Statius Muller MG, Hennipman FA, van Leeuwen PA, Pijpers R, Vuylsteke RJ, Meijer S. Unpredictability of lymphatic drainage patterns in melanoma patients. *Eur J Nucl Med Mol Imaging*. 2002; 29: 255-261.
12. Sanki A, Uren RF, Moncrieff M, Tran KL, Scolyer RA, Lin HY, et al. Targeted high-resolution ultrasound is not an effective substitute for sentinel lymph node biopsy in patients with primary cutaneous melanoma. *J Clin Oncol*. 2009; 27: 5614-5619.
13. Starritt EC, Uren RF, Scolyer RA, Thompson JF. Ultrasound examination of sentinel nodes in the initial assessment of patients with primary cutaneous melanoma. *Ann Surg Oncol*. 2005; 12: 18-23.
14. Hocevar M, Bracko M, Pogacnik A, Videgar-Kralj B, Besic N, Zgajnar J, et al. The role of preoperative ultrasonography in reducing the number of sentinel lymph node procedures in melanoma. *Melanoma Res*. 2004; 14: 533-536.