

Research Article

MRI of Incidental Osteochondral Lesions of the Anterior Femoral Condyle: Are they caused by Repetitive Patellar Impaction?

Nasim Hemmati, Ravi Shergill and Hema N Choudur*

Department of Radiology, McMaster University, Canada

*Corresponding author: Hema Nalini Choudur, McMaster University, 1280 Main Street West, L8S4L8, Ontario, Canada

Received: August 22, 2016; Accepted: September 28, 2016; Published: October 03, 2016

Abstract

Objective: Osteochondral lesions of the anterior femoral condyle are frequent incidental findings. However, little is known about these lesions.

The purpose of this investigation was to determine the location, prevalence and pattern of these lesions.

Materials and Methods: 322 consecutive knee MRI's were retrospectively reviewed on PACS by a fellowship trained musculoskeletal radiologist for presence, location, and grade of the osteochondral lesions in anterior femoral condyle. Other data included suprapatellar or infrapatellar fat pad edema, patellar or patellar tendon lateralization.

Results: 13% of cases demonstrated osteochondral lesions in the anterior femoral condyle. All 44 positive cases demonstrated lesions at the level of inferior margin of the patella (57%) or within 1 cm below the level of the patella (43%). In 29% of cases, the lesions were located in the trochlear groove, 38% in medial aspect of the lateral femoral condyle and 32% in the lateral aspect of the medial femoral condyle. 40% of cases showed suprapatellar fat pad edema, 11% infrapatellar fat pad edema, 22% lateralization of patella or patellar tendon.

Conclusion: Incidental finding of osteochondral lesions in the anterior femoral condyle had a prevalence of 13% in our study. All of the lesions were located at or within 1 cm below the level of the inferior margin of the patella. Based on the location of the lesions, we propose that the mechanism of injury is from repetitive chronic impaction of the inferior margin of patella against the femur during hyperextension or hyperflexion of the knee.

Keywords: Osteochondral lesions; Anterior femoral condyle; Knee MRI; Anterior knee; Patellofemoral joint

Introduction

Osteochondral lesions of the anterior femoral condyle are frequently observed incidental findings on MRI of knees referred for various clinical scenarios. However, there are no specific descriptions of such lesions in the English literature, to the best of our knowledge. The purpose of this investigation was to determine the patterns of the osteochondral lesions in the anterior femoral condyle, including their location, grade and percentage occurrence in our sample. Based on this information, the probable mechanism causing these lesions was proposed.

Materials and Methods

Institutional review board approval was obtained before the initiation of this investigation. Consecutive patients who had undergone MR Imaging of the knees in 2008 and 2009 were identified and their images were reviewed on the PACS. The study group included 322 knee MRI images from 311 patients aged 16 or above. The patients were imaged on a Siemens 1.5 Tesla magnet. The sagittal PD Fat Saturated (FS) and T2 fat sat and axial PD FS sequences were reviewed (Sagittal PD FS: TR: 2710- 3110, TE: 13-14 ST: 3-4/ Sagittal

T2: TR: 2900- 3000 TE: 74-78 ST: 3-4/Axial PD FS: TR: 1,800, TE: 29-31 ST: 4). The sagittal PD and T2 fat saturated images were used to grade the lesions and determine the level of the lesion with respect to inferior margin of the patella. The axial PD FS images were reviewed to localize the lesion in the anterior femoral condyles and the trochlea.

The images were reviewed on the PACS system by a fellowship trained musculoskeletal radiologist with more than 10 years of experience. The presence, location, and grade of the osteochondral lesions in anterior femoral condyle were categorized. Those cases that were found positive for anterior osteochondral lesions were also evaluated for other MR features that reflect patellar impingement against the anterior femoral condyle. These features included suprapatellar or infrapatellar fat pad edema, patellar or patellar tendon lateralization. This methodology was used to propose the mechanism causing the anterior osteochondral lesions.

The location of a lesion was categorized into [1] medial femoral condyle [2] lateral femoral condyle, or [3] within the trochlear groove. The lesions in the medial or lateral femoral condyle were further subcategorized into the medial or lateral aspect of either medial or lateral aspects of the anterior femoral condyle.

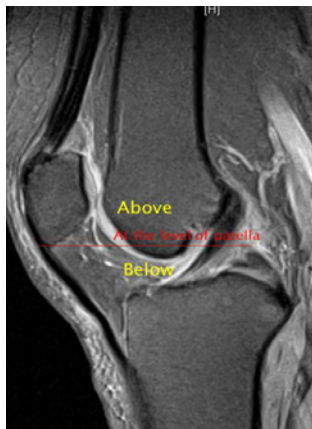

Figure 1: Sagittal T2 fat sat image: A horizontal red line drawn at the level of the inferior margin of the patella was used to define the level of the anterior osteochondral lesions. Lesions were tabulated as at, inferior and superior to this line.

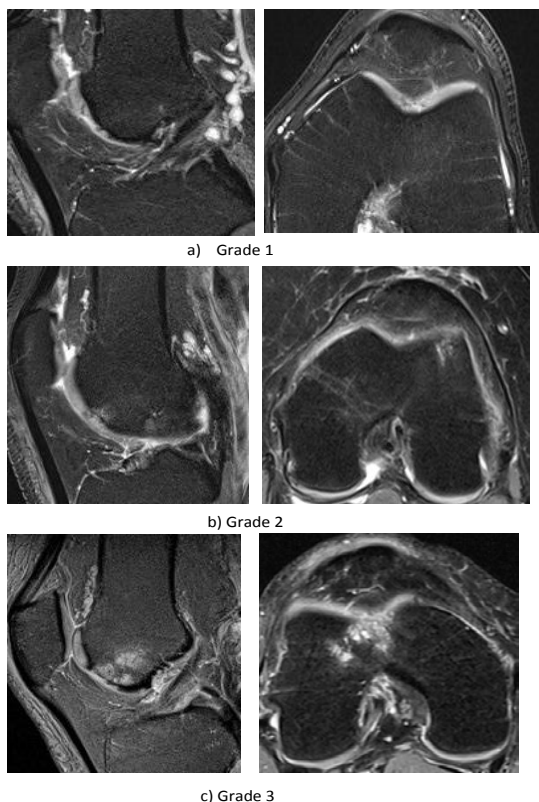


Figure 2: a) Grade 1 lesion: focal chondral defect without underlying bony defect or bone marrow edema. b) Combined osseous and chondral defect without underlying bone marrow edema. c) Combination of osseous and chondral defect with associated bone marrow edema.

The level of a lesion was categorized as: at the level of the inferior margin of the patella, below the inferior margin of the patella, or above the inferior margin of the patella as shown in Figure 1.

We also, graded the severity of the osteochondral lesions as shown in Figure 2. We considered a lesion grade 1 lesion if there was only a focal chondral defect without underlying bony defect or bone marrow edema. A combined osseous and chondral defect without underlying

marrow edema was considered as grade 2 and a combination of osseous and chondral defect with associated bone marrow edema was considered grade 3. When measuring the osteochondral lesions we chose the largest diameter of the lesion.

Results

In our study 44 out of 322 (13%) of the cases demonstrated osteochondral lesions in anterior femoral condyle. Among the positive cases, 26 were female and 18 were male with an average age of 55 (Range 17- 84 years).With regards to the level of the osteochondral lesions with respect to the inferior margin of the patella, 25 cases (57%) demonstrated injury at the level of inferior margin of the patella, 19 cases (43%) within 1 cm below the inferior margin of the patella and none above the level of the inferior patellar margin. Regarding the location of the osteochondral lesions, 13 cases (29%) demonstrated the osteochondral lesion in the trochlear groove, 17 (38%) along the medial aspect of the lateral femoral condyle, and 14 cases (32%) along the lateral aspect of the medial femoral condyle.

Based on the grading of the osteochondral lesions, 6 cases (13.6%) demonstrated Grade 1 lesions, 32 cases (72%) demonstrated Grade 2 lesions and 6 cases (13.6%) demonstrated Grade 3 lesions. The average calculated size of the lesion was 8.3 mm (Range: 2- 25 mm).

Other findings that were included in this study were the suprapatellar fat pad edema that was seen in 40% of cases (18/ 44), infrapatellar fat pad edema in 11% (5/ 44), and lateralization of patella and/or the patellar tendon in 22% of cases (10/44).

Discussion

In our study, osteochondral lesions in the anterior femoral condyle were incidentally prevalent in 13% of the study sample. All of these lesions were located at or within 1 cm below the level of the inferior margin of the patella. All lesions were in the trochlear groove, medial aspect of the lateral condyle or lateral aspect of the medial condyle.

Based on the location of the osteochondral lesions in our study, we propose an impaction injury of the inferior margin of the patella against the anterior femoral condyle as the probable cause of these lesions.

The occurrence of concomitant suprapatellar fat pad edema [1] or infrapatellar fat pad edema [2] and patellar lateralization [3] seem to favor such a mechanism.

Referring to biomechanics of the knee, patellofemoral joint reaction forces occur from combination of: articulation and contact area, patellar compression force, and muscle contraction. The patella does not articulate with the trochlea when the knee is in normal extension. The articulation between patella and the trochlea begins at 10-20 degree of flexion [4] and at end flexion the facets of patella makes direct contact with the femur.

On the other hand, the quadriceps tendon is designed to pull the patella towards the trochlear groove and causes compression of the patellofemoral joint. The maximum force of the quadriceps tendon is at terminal knee extension when the contact area of the patellofemoral joint is the smallest [5]. Therefore, a high force on a small surface results in significant patellofemoral joint reaction

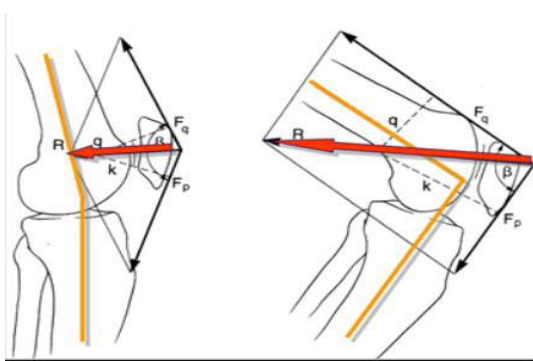


Figure 3: Patellar compression force is resultant force vector between the quadriceps and patellar tendon. The resultant force vector (red arrow) increases as the knee and causes a more compressive force [5].

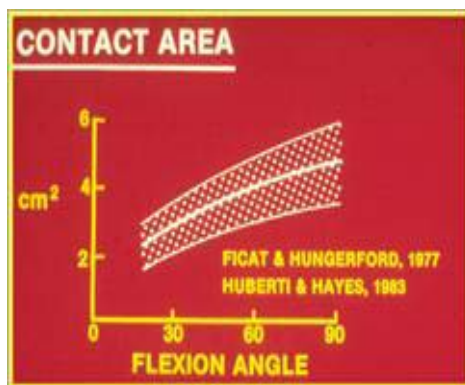


Figure 4: Contact pressure at knee –flexion as between 20 to 120 degree and demonstrated -that the maximum contact area occurs at 90 degrees of knee –flexion, which is about 6 cm² [5].

forces. As the patella contacts the anterior femoral condyle during end phase flexion and end phase extension of the knee, we infer that the impaction injury proposed by us occurs during the end phase flexion /hyperflexion and end phase extension/ hyperextension of the knee.

Patellar compression force is the resultant force vector between the quadriceps tendon and the patellar tendon. The resultant force vector (red arrow in Figure 3) increases as the knee flexes and causes a more –greater compressive force [5]. This is the likely mechanism that accounts for the varying grades/severity of the osteochondral lesions.

It is also important to understand the concept and the effect of the area of contact between the patella and the trochlea. It is obvious

that a small surface will concentrate the load over a smaller area [5]. When the knee is 30 degree flexed, the area of patellofemoral contact is about 2 cm². As the angle of flexion increases, the area of contact also increases. In 1984, Huberti and Hayes measured patellofemoral contact pressure at knee flexion as between 20 to 120 degree and demonstrated that the maximum contact area occurs at 90 degrees of knee flexion, which is about 6 cm² as shown in Figure 4 [5,6]. These mechanics explain the varying sizes of the osteochondral lesions in our study with an average size of 8.3 mm Figure 3&4.

Conclusion

Incidental finding of osteochondral lesions of the anterior femoral condyle had a prevalence of 13% in our study sample. All of these anterior femoral osteochondral lesions were located at or within 1 cm below the level of the inferior margin of the patella. Based on the location of these osteochondral lesions and the known mechanical forces of the knee (including the quadriceps tendon/patella and patellar tendon) that occur during flexion and extension of the knee joint, we propose a mechanism that results in these osteochondral lesions. The impaction of the inferior margin of patella against the anterior femoral condyle during hyperextension or hyper flexion of the knee likely causes the osteochondral injury. The occurrence of suprapatellar or infrapatellar fat pad edema, patellar and patellar tendon lateralization seems to favor such a mechanism. To extrapolate the results to a larger population, bigger studies with a larger number of cases need to be conducted. The clinical impact including pain and disability also needs to be explored and defined with the help of orthopedic surgeons.

References

1. Roth C, Jacobson J, Jamadar D, Caoili E, Morag Y, Housner J. Quadriceps fat pad signal intensity and enlargement on MRI: prevalence and associated findings. *American Journal of Roentgenology (AJR)*. 2004; 182: 1383-1387.
2. De Smet AA, Davis KW, Dahab KS, Blankenbaker DG, del Rio AM, Bernhardt DT. Is there an association between superolateral Hoffa fat pad edema on MRI and clinical evidence of fat pad impingement? *American Journal of Roentgenology (AJR)*. 2012; 199: 1099-1104.
3. Sanders TG, Paruchuri NB, Zlatkin MB. MRI of osteochondral defects of the lateral femoral condyle: incidence and pattern of injury after transient lateral dislocation of the patella. *American Journal of Roentgenology (AJR)*. 2006; 187: 1332-1337.
4. Lynch P. *Knee skeleton lateral anterior views*. Svg. 2006.
5. Rainold M. *Biomechanics of Patellofemoral Rehabilitation*. 2009.
6. Huberti HH, Hayes WC. Patellofemoral contact pressures: The influence of q-angle and tendofemoral contact. *J Bone Joint Surg Am*. 1984; 66: 715 -724.