

Research Article

The Impact of a Multidisciplinary Approach in the Treatment of Desmoplastic Small Round Cell Tumor (DSRCT)

Corrêa TS^{1*}, Castro Andrade AMGM¹, Toloi DA¹, Venchiarutti C¹, Camargo VP^{1,2}, Gonçalves MS^{1,2} and Hoff PM^{1,2}

¹Department of Medical Oncology, Universidade de São Paulo, Brazil

²Department of Medical Oncology, Hospital Sirio Libanês, Brazil

*Corresponding author: Corrêa TS, Department of Medical Oncology, Instituto do Câncer do Estado de São Paulo, (ICESP), Universidade de São Paulo, Av. Dr Arnaldo, 251 – 5th floor – São Paulo-SP, 01246-000, Brazil, Tel: +55 (11) 3893-2673; Fax: +55 (11) 3893-2000; Email: tatistrava@yahoo.com.br

Received: February 09, 2015; Accepted: July 10, 2015;

Published: July 25, 2015

Abstract

Introduction: DSRCT is a rare and aggressive cancer that affects children and young adults with a predominance of males. There is no standard treatment, and the prognosis is poor. In this retrospective study, we analyzed epidemiologic data, treatment and the overall survival of patients (pts.) treated at two Brazilian oncology centers: Instituto do Câncer do Estado de São Paulo and Hospital Sirio-Libanês.

Methods: Retrospective analysis of patients with DSRCT treated between January 2007 and November 2014.

Results: In this period, 12 patients were evaluated. The median age was 24 years, most patients were male (81%). Most patients received chemotherapy (92%) and seven were exposed to the regimen VAC (vincristine, doxorubicin and cyclophosphamide) in first line. The chemotherapy regimen used was not predictive of improved survival. The time free of progression for the first line was 21 weeks. Survival from diagnosis was 111 weeks, better for patients with good performance status (ECOG 0/1). Cytoreduction surgery was performed in six patients, with no statistical difference in survival (111 vs. 70 weeks; $p=0,292$).

Conclusion: This is the largest series of Brazilian DSRCT reported. Despite the lack of a standard treatment, our study suggests that surgical treatment and multiagent chemotherapy might yield better disease control, with a propensity to better survival.

Keywords: Desmoplastic small round cell tumor; Peritoneal neoplasia; Multimodal treatment; Cytoreduction surgery

Introduction

Desmoplastic small round cell tumor (DSRCT) is a rare and aggressive cancer that affects children and young adults with a male predominance [1]. The tumor typically arises in the peritoneal cavity and is genetically defined by the translocation $t(11;22)(p13;q12)$ EWSR1- WT-1 [2].

DSRCT typically presents as a large intra-abdominal mass with multifocal disease that spread along the peritoneal and mesothelial epithelium. There may also be ascites at the time of diagnosis. The lesions are usually very large with smaller lesions associated, impairing absorption of normal peritoneal fluid. The most common site of metastases is the liver [3].

Disease staging is usually made with radiologic evaluation by computed tomography and many staging systems have been proposed but none validated [1]. Recent studies with FDG PET/CT are promising [4], and a new staging system based on peritoneal cancer index and the presence of liver metastases and extra-abdominal metastases suggested by investigators at the MD Anderson Cancer Center seems to be clinically relevant [5].

There is no standard treatment available and the prognosis is very poor. Despite multiple strategies including chemotherapy regimens

active for sarcomas, aggressive debulking surgery, whole-abdominal radiation, high-dose chemotherapy with autologous stem cell transplant, durable remissions remain rare [6].

In this retrospective study, we analyzed the overall survival and epidemiologic data of patients treated at the Instituto do Câncer do Estado de São Paulo (ICESP) - Faculdade de Medicina da Universidade de São Paulo - and Hospital Sirio Libanês (HSL), both in São Paulo, Brazil.

Materials and Methods

Retrospective study of patients with DSRCT treated at ICESP and HSL in the period between January 2007 and November 2014. This study was approved by the both ethics committee of the Universidade de São Paulo and HSL.

Patients

The study population consisted of patients with histologically documented diagnosis of desmoplastic small round cell tumor with the EWSR1 - WT1 fusion transcripts detected by fluorescence in situ hybridization (FISH). The following data were abstracted from the electronic medical records: age at the time of the diagnosis, ECOG performance-status at initial treatment, disease presentation (primary site and staging with dissemination to peritoneum only, peritoneum

Table 1: Characteristics of the Patients.

| | |
|-----------------------------|-----------------|
| Age | 24 years |
| Sex | |
| Masculine | 10 (83%) |
| Feminine | 02 (16%) |
| ECOG 0/1 | 09 (75%) |
| ECOG 2 | 03 (25%) |
| Disease Presentation | |
| Peritoneum only | 02 (16%) |
| Peritoneum and liver | 02 (16%) |
| Other Distant metastases | 08 (66%) |
| Primary tumor | |
| Peritoneum | 10 (83%) |
| Uterus | 01 (8%) |
| Mediastinum | 01 (8%) |
| Ascites | 08 (66%) |

and hepatic metastases, and distant metastases), front line oncologic treatment (surgery and or chemotherapy – type and the median number of cycles) and the use of radiotherapy.

Statistical methods

Overall survival was estimated by the Kaplan-Meier method. The probability of a type I error was specified at 0.05 with use of a stratified log-rank test. Comparisons between variables were performed by Chi-square test. Clinical and epidemiological data are described.

Results

From January 2007 to November 2014, 12 patients with DSRCT were diagnosed and treated (Table 1). The median age at diagnosis was 24 (17 - 38) years old and most patients were male (83%). The ECOG at diagnosis were 0/1 in nine and 2 in three patients. The primary tumor was mostly in the peritoneum (83%), other sites were mediastinum (n = 1) and uterine cervix (n = 1). The initial disease was limited to the peritoneum in 16%, with hepatic metastases only in 16% and with distant metastases (beyond liver) in 66% of the patients. The more frequent sites were liver (n = 6), pleura (n = 5), lung (n = 3) and nodes (n=4). Eight patients had ascites during the course of the disease.

Most patients received chemotherapy during treatment (92%) and 58% (n = 7) were exposed to the regimen vincristine, doxorubicin and cyclophosphamide (VAC) as first line. Other reported chemotherapy regimens were platinum doublets and Ifosfamide plus Etoposide (IE). The chemotherapy regimen used was not predictive of improved survival. The time free of new treatment (TFNT) for the patients submitted to first line treatment (n=11) was 21 (1- 40.5) weeks. Patients had a median of three lines of treatment. Three patients were exposed to five lines of treatment. Two patients in first line and one in second lines were exposed to carboplatin and paclitaxel plus bevacizumab with radiologic partial response. The TFNT was 43 and 22 weeks for the first line patients and 19 weeks for the second line patient. Three patients received radiotherapy as part of palliative treatment.

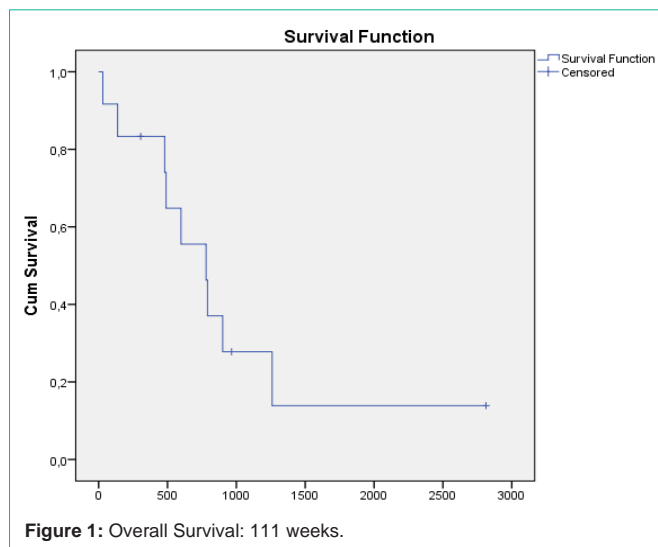


Figure 1: Overall Survival: 111 weeks.

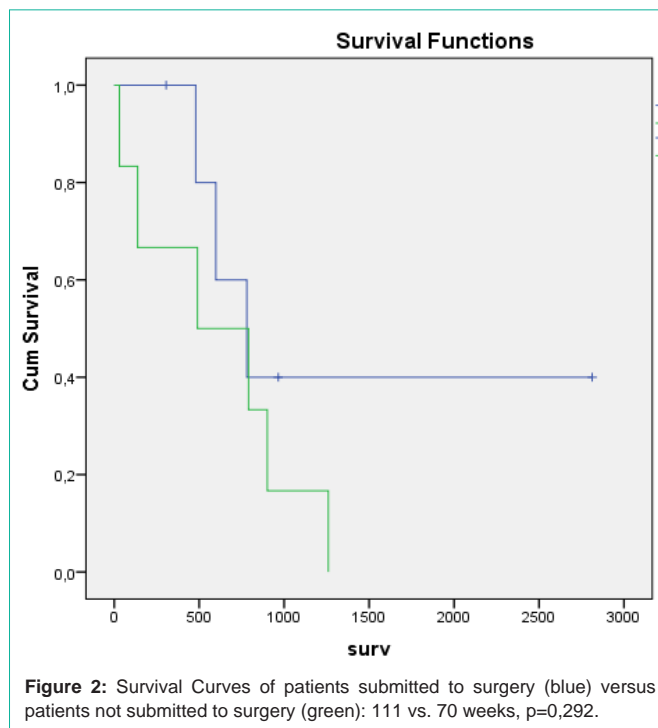


Figure 2: Survival Curves of patients submitted to surgery (blue) versus patients not submitted to surgery (green): 111 vs. 70 weeks, p=0,292.

Patient survival from diagnosis was 111 (4.2 – 402) weeks (Figure 1). The overall survival was better in patients with better performance status (ECOG 0/1 = 128 weeks; 2= 70 weeks), statistically significant (p=0,031).

Cytoreduction surgery was performed in six patients, with tendency for a better survival (111 vs. 70 weeks; p=0,292) not statistically significant (Figure 2). One patient diagnosed in 2007 with localized disease in peritoneum submitted only to cytoreduction surgery and is alive until the present date.

Discussion

In a seven-year retrospective analysis, we found 12 patients with DSRCT, most of them young men, with heterogeneous presentation of disease (82% with metastatic disease) and a median survival of 28

months. Almost all patients were exposed to chemotherapy, mostly VAC, IE and platin doublets. Cytoreduction surgery and good performance are factors that had a trend to increase survival, but also could be markers of a less aggressive biology.

The DSRCT usually presents as a multifocal, diffuse peritoneal disease. Because of the paucity of literature, there is no established standard treatment. Surgery seems to have an important role in the therapeutic of DSRCT, single aggressive surgical resection continues to be a major determinant in patient survival. As we have reported, the case of one patient submitted to cytoreduction surgery and is cured, with survival of more than 7 years.

A recent review of 41 cases from UK looking for prognostic factors for DSRCT concluded that surgical resection for localized disease and radiotherapy in the metastatic setting are associated with improved survival. Patient's age, gender and size of presenting tumor did not have prognostic significance in this analysis [7].

A retrospective cohort study was performed on 26 patients who underwent cytoreduction/ Hyperthermic Intraperitoneal Chemotherapy (HIPEC) using cisplatin for DSRCT at MD Anderson Cancer Center. Patients received neoadjuvant chemotherapy, adjuvant chemotherapy, and postoperative enteral nutrition. Most patients also received postoperative radiation therapy. Patients who had optimal resection and HIPEC had significantly longer median survival compared with patients who had HIPEC and none optimal (R2) cytoreduction (63.4 vs. 26.7 months). Patients with DSRCT and disease outside the abdomen at the time of surgery do not benefit from HIPEC [5].

With the aim of better control of this disease, multimodal treatment is an option, with the combination of aggressive surgery (R0/1), radiation therapy to the tumor bed and myeloablative multiagent chemotherapy [8]. In 2005, the Memorial Sloan-Kettering Cancer Center experience report showed that overall survival in 66 patients was 44% at three years and 15% at five years using the combination therapy. Gross tumor resection was highly significant in prolonging overall survival; 3-year survival was 58% ($P < 0.00001$) [6]. However, more than half of these patients had no distant metastasis.

There are few reports of metastatic DSRCT treatment. Kushner et al. [9], in 1996, described results in 12 DSRCT patients. The treatment used intensive alkylator-based therapy: cyclophosphamide, doxorubicin, vincristine alternating with ifosfamide and etoposide. The combination with other treatment modalities such as surgery, radiation, autologous stem cell rescue, was used. Seven patients achieved a complete remission and four patients who achieved a partial remission. The most common reported toxicity was myelosuppression and mucositis, with most of patients having hospitalization in the course of treatment. One patient died of infection.

It is interesting to note that the patients submitted to carboplatin and paclitaxel plus bevacizumab had a major TFNT in first line compared to other patients (43 and 22 weeks X 21 weeks). Of course, this an isolated case report and we need new studies with more patients to evaluate this chemotherapy schema.

Phase I and II trials have been performed with ganitumab, trabectedin and pazopanib. Ganitumab was well tolerated and

demonstrated antitumor activity in patients with advanced recurrent Ewing family tumors or DSRCT [10]. There were some case reports with temsirolimus, sunitinib, and sorafenib with progression free survival between 2 to 8 months [1].

Durable remissions are rare in patients with DSRCT. In the current literature, the overall survival is 15% at 5 years, which is consistent with findings in our case series: 20% and 10% in 3 and 5 years. Most patients have recurrent and resistant disease before the end of life.

Conclusion

This is the largest series of brazilian DSRCT reported in the literature, far as we know. DSRCT is a rare and highly aggressive neoplasm. Most of the patients experience a recurrence and are resistant to major treatment modalities currently available. Despite the lack of a standard treatment, our study suggests that surgical treatment and multiagent chemotherapy might yield some disease control, with a propensity to better survival. The study of genetic mutations involved in this disease, and resistance pathways will help in the development of target therapy with a perspective of improve results for this rare and bad prognosis disease.

Acknowledgement

We are grateful to the patients that allowed us to learn from their disease.

References

- Dufresne A, Cassier P, Couraud L, Marec-Bérard P, Meeus P, Alberti L, et al. Desmoplastic small round cell tumor: current management and recent findings. *Sarcoma*. 2012; 2012: 714986.
- Helman LJ, Meltzer P. Mechanisms of sarcoma development. *Nat Rev Cancer*. 2003; 3: 685-694.
- Jordan AH, Pappo A. Management of desmoplastic small round-cell tumors in children and young adults. *J Pediatr Hematol Oncol*. 2012; 34 Suppl 2: S73-75.
- Arora VC, Price AP, Fleming S, Sohn MJ, Magnan H, LaQuaglia MP, et al. Characteristic imaging features of desmoplastic small round cell tumour. *Pediatr Radiol*. 2013; 43: 93-102.
- Hayes-Jordan A, Green HL, Lin H, Owusu-Agyemang P, Fitzgerald N, Arunkumar R, et al. Complete cytoreduction and HIPEC improves survival in desmoplastic small round cell tumor. *Ann Surg Oncol*. 2014; 21: 220-224.
- Lal DR, Su WT, Wolden SL, Loh KC, Modak S, La Quaglia MP. Results of multimodal treatment for desmoplastic small round cell tumors. *J Pediatr Surg*. 2005; 40: 251-255.
- Wong HH, Hatcher HM, Benson C, Al-Muderis O, Horan G, Fisher C, et al. Desmoplastic small round cell tumour: characteristics and prognostic factors of 41 patients and review of the literature. *Clin Sarcoma Res*. 2013; 3: 14.
- Watanabe T, Miyamoto S, Kitagori K, Horimatsu T, Morita S, Mashimo Y, et al. A case of long-term survival of metastatic desmoplastic small round cell tumor treated with multimodal therapy. *Oncol Lett*. 2012; 3: 30-34.
- Kushner BH, LaQuaglia MP, Wollner N, Meyers PA, Lindsley KL, Ghavimi F, et al. Desmoplastic small round-cell tumor: prolonged progression-free survival with aggressive multimodality therapy. *J Clin Oncol*. 1996; 14: 1526-1531.
- Tap WD, Demetri G, Barnette P, Desai J, Kavan P, Tozer R, et al. Phase II study of ganitumab, a fully human anti-type-1 insulin-like growth factor receptor antibody, in patients with metastatic Ewing family tumors or desmoplastic small round cell tumors. *J Clin Oncol*. 2012; 30: 1849-1856.