

## Research Article

# Sinonasal Hemangiopericytomas are not Sinonasal Solitary Fibrous Tumors: a Study of STAT6 Immunohistochemistry and its Role in the Differential Diagnosis of These Two Entities

**Choi SM and Zhang PJ\***

Department of Pathology and Laboratory Medicine, Hospital of the University of Pennsylvania, USA

**\*Corresponding author:** Paul J Zhang, Department of Pathology and Laboratory Medicine, Hospital of the University of Pennsylvania, 3400 Spruce Street, 6 Founders, Philadelphia, PA 19104, USA**Received:** July 14, 2015; **Accepted:** October 02, 2015; **Published:** October 05, 2015**Abstract**

Most hemangiopericytomas in somatic soft tissue are now reclassified as solitary fibrous tumors (SFTs), except for Sinonasal hemangiopericytomas (SNHPCs). Morphologically typical SFTs do not infrequently occur in the head and neck region, including the sinonasal cavity, and usually can be diagnosed with certainty by typical morphology and CD34 immunoreactivity. SNHPCs are low grade spindle cell tumors occurring in the sinonasal cavity. They morphologically overlap with, but are not completely identical to, SFTs with variable CD34 reactivity and traditionally are regarded as an entity distinct from soft tissue hemangiopericytomas. Nuclear STAT6 expression due to a highly recurrent, tumor specific NAB2-STAT6 fusion has been recently used as a diagnostic marker specific for SFTs. However, only limited SNHPCs have been evaluated for STAT6 expression. We examined a cohort of sinonasal hemangiopericytomas with STAT6 immunohistochemistry using archived paraffin-embedded tissue and found that one quarter to one third of SNHPCs would be reclassified as sinonasal solitary fibrous tumors (SNSFTs) according to their STAT6 immunoreactivity. Many of these SNSFT cases were negative for CD34, demonstrating the limited utility of this marker in the diagnosis of SNSFTs. SMA staining showed an inverse correlation with STAT6 staining, highlighting most cases of SNHPCs. Thus, by using STAT6 as a diagnostic marker, the incidence of SNSFTs appears to be higher than previously thought. However, the majority of the SNHPCs still appear to STAT6 negative, supporting an entity distinct from SFTs. STAT6 immunohistochemistry is likely to resolve the vast majority of equivocal cases between SNHPC and SNSFT within the differential diagnosis.

**Keywords:** Sinonasal; Hemangiopericytomas; Solitary fibrous tumor; STAT6**Introduction**

Sinonasal hemangiopericytomas (SNHPCs), also known as glomangiopericytomas, are thought to be mesenchymal lesions of perivascular glomus-like myoid cell origin [1,2]. These lesions are relatively rare and commonly occur in the nasal cavity, and less often in the paranasal sinuses. While metastasis is extremely uncommon, they can be locally recurrent and are managed with surgical resection. SNHPCs commonly express smooth muscle actin and may show focal or patchy CD34 positivity.

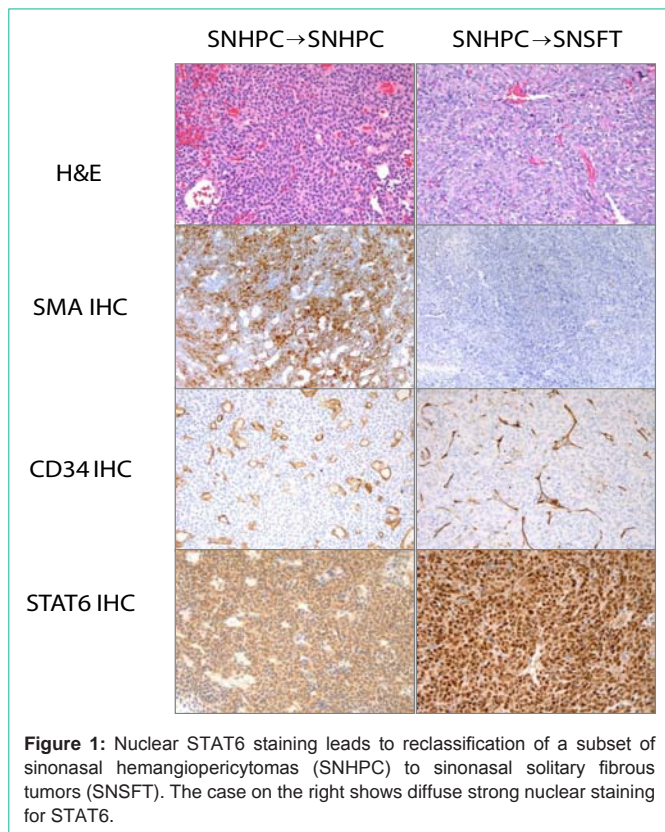
The term hemangiopericytoma was originally used to name a group of spindle cell tumors in the soft tissue, most of which are now known as solitary fibrous tumors. These two lesions were once regarded as distinct diagnoses, but are now understood to be a single entity of fibroblastic rather than pericytic origin, existing along a morphologic spectrum [2]. CD34 has been routinely used as a marker of SFTs for many years, however recent studies have identified a more sensitive and specific marker, STAT6, which demonstrates a nuclear staining pattern, reflective of a highly recurrent, characteristics

NAB2-STAT6 translocation in SFTs [3,4].

Soft tissue type SFTs can occur in the head and neck region and sinonasal cavity and show certain morphologic overlap with SNHPCs. However, unlike soft tissue hemangiopericytomas, sinonasal hemangiopericytomas (SNHPCs) and sinonasal solitary fibrous tumors (SNSFTs) are still regarded as different entities, with the former representing lesions that are less prone to malignant transformation and metastasis. One recent study used a small cohort of cases of SNHPCs and SNSFTs and demonstrated STAT6 nuclear staining and the presence of the NAB2-STAT6 translocation only in cases of SNSFTs and not SNHPCs, suggesting that unlike soft tissue lesions, these entities are not equivalent [5]. We set out to examine a larger retrospective cohort of cases to further investigate the distinctness of SNHPCs and role of STAT6 immunohistochemistry in establishing a diagnosis of SNHPCs vs. SNSFTs, with particular emphasis on equivocal cases.

**Materials and Methods**

Archived paraffin embedded tissue blocks of sinonasal HPCs



**Figure 1:** Nuclear STAT6 staining leads to reclassification of a subset of sinonasal hemangiopericytomas (SNHPC) to sinonasal solitary fibrous tumors (SNSFT). The case on the right shows diffuse strong nuclear staining for STAT6.

biopsied or excised at the Hospital of the University of Pennsylvania from 2008-2014 were identified (n=11). Four cases of sinonasal SFTs were also included for comparison. The original diagnoses were made on the basis of morphology and immunohistochemical staining results, in particular CD34 and SMA staining. STAT6 staining had

not been performed prior to this study. Hematoxylin and eosin slides were reviewed and a representative section of the lesion was selected for immunohistochemical staining. STAT6 nuclear expression was evaluated immunohistochemically on paraffin section on Leica Autostainer Bond III (STAT6 polyclonal antibody, Santa Cruz Biotechnologies, S-20 sc-621, 1:200 dilution). Prior reports and immunostains performed at the time of the diagnosis were also reviewed for expression of other immunohistochemical markers, in particular, CD34 and SMA. This study was approved by the institutional review board.

**Results and Discussion**

Of the 11 cases of sinonasal HPCs, 3 (27%) cases demonstrated diffuse STAT6 nuclear positivity (Figure 1; Table 1). All of these cases were also CD34 negative. Of the remaining eight cases of HPCs, three cases (38%) demonstrated focal to diffuse CD34 positivity. All four cases of sinonasal SFTs demonstrated diffuse STAT6 nuclear positivity, only two of which also were positive for CD34. After reclassification, only 2 of 7 (28%) SNSFTs were CD34 positive. In cases where SMA had been performed, SMA was negative or focal in cases of SNSFTs and was positive in cases of SNHPCs following reclassification. STAT6 cytoplasmic staining was noted in five of 7 cases of SNHPCs. Clinical follow-up of all patients, ranging from 6 months to 5 years, showed no evidence of recurrence either clinically or radiologically regardless of diagnosis.

In contrast to prior studies, our study shows STAT6 nuclear reactivity in 27% of previously diagnosed SNHPCs. As NAB2-STAT6 translocation is a highly recurrent and highly specific event in SFTs, STAT6 nuclear expression has been used as a new diagnostic standard for SFT regardless of CD34 reactivity. Therefore, it is logical to regard these three STAT6 positive, CD34 negative SNHPCs as SNSFTs instead of SNHPCs with STAT6 nuclear reactivity. This finding

**Table 1:** Classification of cases of sinonasal hemangiopericytomas (SNHPCs) and sinonasal solitary fibrous tumors (SNSFTs) and results of immunohistochemical studies. ND=Not Done.

Case No.	Age	Sex	Original Diagnosis	Final Diagnosis	Immunohistochemistry					
					STAT6	CD34	SMA	BCL2	CD99	S100
1	54	M	SNHPC	SNHPC	Negative	Negative	Positive	Focal	Focal	Focal
2	53	M	SNHPC	SNHPC	Negative	Focal	ND	ND	ND	ND
3	32	F	SNSFT	SNSFT	Positive	Negative	Negative	ND	ND	Negative
4	26	F	SNHPC	SNHPC	Cytoplasmic	Negative	ND	ND	ND	ND
5	75	M	SNSFT	SNSFT	Positive	Positive	ND	ND	ND	Negative
6	70	M	SNHPC	SNHPC	Cytoplasmic	Negative	Focal	Focal	Positive	Negative
7	67	M	SNSFT	SNSFT	Positive	Negative	ND	ND	ND	ND
8	43	M	SNHPC	SNHPC	Negative	Negative	Positive	Positive	ND	Negative
9	41	F	SNHPC	SNSFT	Positive	Negative	Negative	Positive	ND	Negative
10	62	F	SNHPC	SNSFT	Positive	Focal	Focal	Positive	ND	Negative
11	57	M	SNHPC	SNHPC	Cytoplasmic	Negative	Positive	ND	ND	ND
12	55	M	SNHPC	SNHPC	Cytoplasmic	Positive	ND	ND	ND	Negative
13	58	F	SNSFT	SNSFT	Positive	Positive	Negative	ND	ND	Negative
14	66	F	SNHPC	SNHPC	Cytoplasmic	Neg	Positive	ND	ND	Negative
15	66	F	SNHPC	SNHPC	Negative	Positive	ND	ND	ND	ND
16	75	M	SNHPC	SNSFT	Positive	Positive	Negative	Positive	Positive	Negative

implicates that CD34 reactivity is low (28%) in SNSFTs and could be up to 38% in SNHPCs. When CD34 is negative, SNSFTs have the potential for misclassification as SNHPCs. The diagnostic utility of CD34 staining is, therefore, limited in differentiating SNSFTs from SNHPCs. As STAT6 immunohistochemistry becomes available, the incidence of SNSFTs would be expected to increase as more SNSFTs could be correctly diagnosed by STAT6. Conversely, SMA staining, when performed, correlated well with SNHPCs (all cases showed some degree of positivity) and were either negative or only seen focally in SNSFTs. Recent studies of SNHPCs also suggest that beta-catenin is another new potential diagnostic marker for this entity [6,7], and though this stain was not performed in this retrospective analysis, we anticipate it would perform in a similar manner to SMA.

Interestingly, cytoplasmic staining for STAT6 was seen in a subset of cases of SNHPCs. This finding has been reported in a survey of mesenchymal lesions, and its significance is currently unknown [8]. It is important to note that only nuclear positivity is diagnostic of SFTs, and that cytoplasmic staining is an important pitfall in the interpretation of STAT6 immunohistochemistry.

After reclassification using STAT6 as diagnostic marker, 72% (8/11) of previously diagnosed SNHPCs were still negative for STAT6, which is significantly less frequent than that of soft tissue HPCs, indicating SNHPCs are not simply SFTs in the sinonasal tract, and supporting the notion that SNHPC, though its incidence is lower than what we expected after excluding CD34 negative SFT by STAT6, is a distinct entity from SNSFT. Along those lines, these findings may reflect the postulated different cells of origin of these two lesions, the perivascular myoid cell or pericyte (in the case of HPCs) and mesenchymal fibroblast cells (in the case of SFTs). To complicate matters further, it has been noted that different fusion variants of the NAB2-STAT6 translocation are associated with different morphologies as well as different clinical outcomes, at least with respect to pleuropulmonary SFTs and deep-seated tissue SFTs [9]. It would be interesting to see where SNSFTs fall in this spectrum.

## Conclusion

In conclusion, SNSFTs appear to have the same characteristic STAT6 nuclear reactivity as their soft tissue counterparts and a higher

incidence than previously thought, due to their higher incidence of CD34 negativity. Unlike in the soft tissue, SNHPCs appear to be distinct from SNSFTs. STAT6 stain is, therefore, essential to further differentiate SFTs from HPCs in the sinonasal tract. The clinical relevance of this distinction requires further study, as the case in our studies all showed no evidence of recurrence regardless of diagnosis.

## References

1. Fletcher CD. The evolving classification of soft tissue tumours: an update based on the new WHO classification. *Histopathology*. 2006; 48: 3-12.
2. Fletcher CD, Unni KK, Mertens F. World Health Organization Classification of Tumours. Pathology and Genetics of Tumours of Soft Tissue and Bone. Lyon: IARC Press. 2002.
3. Robinson DR, Wu YM, Kalyana-Sundaram S, Cao X, Lonigro RJ, Sung YS, et al. Identification of recurrent NAB2-STAT6 gene fusions in solitary fibrous tumor by integrative sequencing. *Nat Genet*. 2013; 45: 180-185.
4. Doyle LA, Vivero M, Fletcher CD, Mertens F, Hornick JL. Nuclear expression of STAT6 distinguishes solitary fibrous tumor from histologic mimics. *Mod Pathol*. 2014; 27: 390-395.
5. Agaimy A, Barthelmeß S, Geddert H, Boltze C, Moskalev EA, Koch M, et al. Phenotypical and molecular distinctness of sinonasal haemangiopericytoma compared to solitary fibrous tumour of the sinonasal tract. *Histopathology*. 2014; 65: 667-673.
6. Haller F, Bieg M, Moskalev EA, Barthelmeß S, Geddert H, Boltze C, et al. Recurrent mutations within the amino-terminal region of  $\beta$ -catenin are probable key molecular driver events in sinonasal hemangiopericytoma. *Am J Pathol*. 2015; 185: 563-571.
7. Lasota J, Felisiak-Golabek A, Aly FZ, Wang ZF, Thompson LD, Miettinen M. Nuclear expression and gain-of-function  $\beta$ -catenin mutation in glomangiopericytoma (sinonasal-type hemangiopericytoma): insight into pathogenesis and a diagnostic marker. *Mod Pathol*. 2014; 28: 715-720.
8. Barthelmeß S, Geddert H, Boltze C, Moskalev EA, Bieg M, Sirbu H, et al. Solitary fibrous tumors/hemangiopericytomas with different variants of the NAB2-STAT6 gene fusion are characterized by specific histomorphology and distinct clinicopathological features. *Am J Pathol*. 2014; 184: 1209-1218.
9. Demicco EG, Harms PW, Patel RM, Smith SC, Ingram D, Torres K, et al. Extensive survey of STAT6 expression in a large series of mesenchymal tumors. *Am J Clin Pathol*. 2015; 143: 672-682.