

Case Report

Extensive Osteosarcoma of Mandible: A Rare Case Report

Mishra SK¹, Singh RK^{1*}, Singh A², Raghwendra KH³ and Biswas NR⁴

¹Department of Otorhinolaryngology, Indira Gandhi Institute of Medical Sciences, Patna, India

²Department of Pathology, Indira Gandhi Institute of Medical Sciences, Patna, India

³Department of Anaesthesiology, Indira Gandhi Institute of Medical Sciences, Patna, India

⁴Department of Clinical Pharmacology, Indira Gandhi Institute of Medical Sciences, Patna, India

*Corresponding author: Singh RK, Department of Otorhinolaryngology, Indira Gandhi Institute of Medical Sciences, Sheikhpura, Patna, India

Received: April 24, 2016; Accepted: May 18, 2016;

Published: May 20, 2016

Introduction

Osteosarcomas are rare malignant tumours originating in bones, which commonly affect the long bones close to their metaphyseal ends. Their occurrence in craniofacial region is rare accounting for 4-6% of all sarcomas in this region [1,2]. It has been found that osteosarcomas of the jaws have distinct clinical and pathological differences from those appearing in the long bones. The tumours appearing in the maxilla are mostly seen to involve the posterior part of alveolar process and antrum. In the mandible, body is most commonly involved followed by angle, symphysis and rarely the ramus. These tumours have atypical clinical and radiological features and sometimes can have varied histological picture which makes the diagnosis difficult [2-4]. We are presenting a case of extensive mandibular osteosarcoma in a child with favourable outcome in adverse.

Case Report

A 10 year old boy presented to ENT outpatient department with complaints of large progressively enlarging mass involving the lower jaw, difficulty in taking solid food, inability to speak and occasional bleeding from the mass for 6 months. On examination, a huge proliferative mass of about 8 x 10 cm was seen involving the body of mandible on both sides and floor of the mouth, displacing tongue posteriorly and the overlying skin was stretched with increased vascular markings (Figure 1a,1b). On palpation, it was mixed in consistency. Other head, neck and systemic examinations were within normal limits. The haematological picture, biochemical reports, chest X-ray and ultrasonography of abdomen were normal. Neck nodes were clinically not palpable and the airway was patent. On the basis of these clinical findings, Computed Tomography (CT) was advised that revealed a heterogeneously enhancing mass involving the body of mandible with areas of bone destruction. The lesion was involving the entire width of lower alveolar process, while the ramus and condyle were normal. Multiple small sub-centimetric lymph nodes were seen at level one and two on right side (Figure 2a,2b,2c). Punch biopsy from the mass was taken and sent for histopathological examination which showed features of malignant mesenchymal tumour. The

Abstract

Osteosarcoma is a rare malignant tumour of long bones and its occurrence in head and neck region is even rare. Involvement of mandible by such tumours in children is exceptional. The early and prompt treatment with adequate follow up provides favourable result. Hereby, we are reporting a case of osteosarcoma in a child involving the lower jaw with the objective of discussing the difficulties faced in the diagnosis and management.

Keywords: Osteosarcoma; Mandible; Extensive; Recurrence

patient was prepared for surgery. Wide excision of the mass was done with anterior and lateral segmental mandibulectomy and bilateral supra-omohyoid neck dissection. Elective tracheostomy was also done and the patient was decannulated two weeks after surgery. The excised specimen was sent for histopathological examination, which showed high grade pleomorphic sarcoma involving mandible and soft tissue (Figure 3a,3b). Immunohistochemistry was done, which confirmed the diagnosis of osteosarcoma. Patient was then referred to the radio-oncology department for further management. However, he had escaped from chemotherapy and absconded from

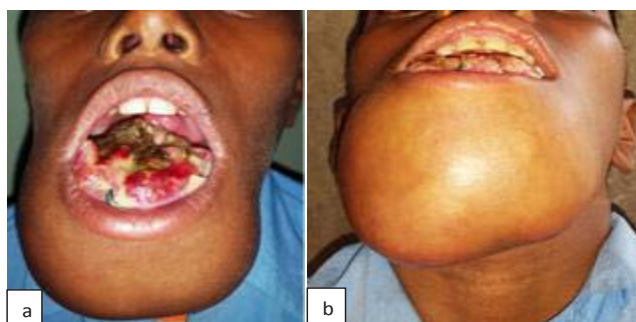


Figure 1: a,b) Clinical picture showing huge mass involving the mandible and floor of mouth.

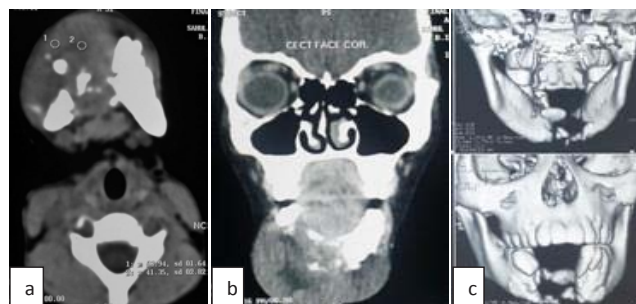


Figure 2: a,b,c) CT Scan axial and Coronal view with 3D reconstruction showing extent of the mass and erosion of central part of mandible.

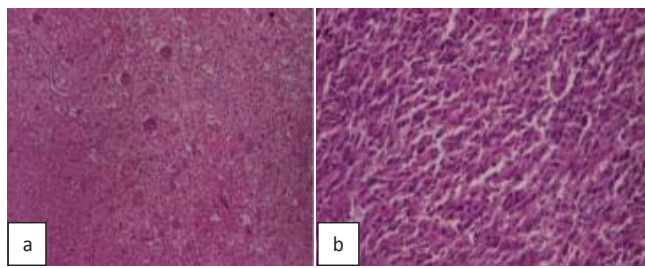


Figure 3: a,b) Histopathological examination under 40X magnification (a) and 100X magnification (b) showing spindle and polygonal cells with high mitotic features.

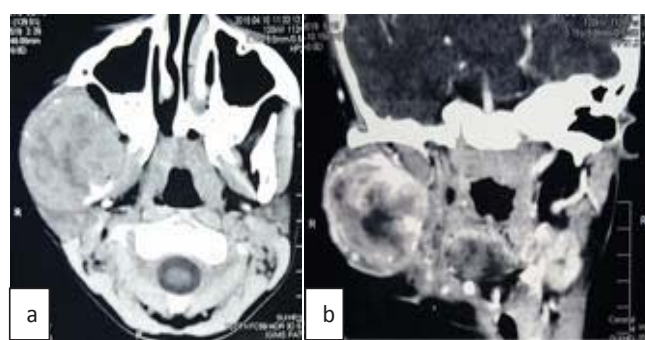


Figure 4: a,b) CT Scan Axial and coronal view showing recurrent lesion involving ramus and head of mandible and extension in TM joint and temporal fossa.

the treatment for 5 months during which he was taking indigenous treatment. After elapse of this vital period, he suddenly appeared in ENT outpatient department with a swelling in the right pre-auricular region of about 2 x 3 cm in size. FNAC was advised that showed the features of mesenchymal tumour. The chance of metastasis was ruled out by radiological examination. Furthermore, CT scan of head and neck region was advised to assess the local recurrence. The CT showed right sided heterogeneously enhancing mass of 6 x 4 cm involving the ramus and head of mandible that extended superiorly to involve the temporo mandibular joint (Figure 4a,4b). He was again taken up for surgery with wide local excision of the mass including removal of rest of the right side of mandible, ipsilateral total parotidectomy and temporal and infra-temporal fossa soft tissue clearance. Histopathology of the excised specimen showed features of osteosarcoma. During follow-up he was administered post-operative chemotherapy under strict vigilance. Post operative CT was done after one year of surgery that revealed no evidence of residual or recurrent lesion (Figure 5a,5b). The wound was well healed and no other lesion was evident. The mouth opening was adequate and drooling of saliva was not evident (Figure 6a,6b). He did not have swallowing and speech difficulties except right sided lower motor facial nerve palsy of grade three. For the past one and a half year, he has been leading a healthy and hearty life without any recurrence.

Discussion

Osteosarcomas are malignant bone tumours which commonly affect long bones; its occurrence in jaw is very rare. Osteosarcomas account for 20% of all the sarcomas with involvement of maxillofacial region seen in only 4-6% of cases [2]. The usual age of presentation of

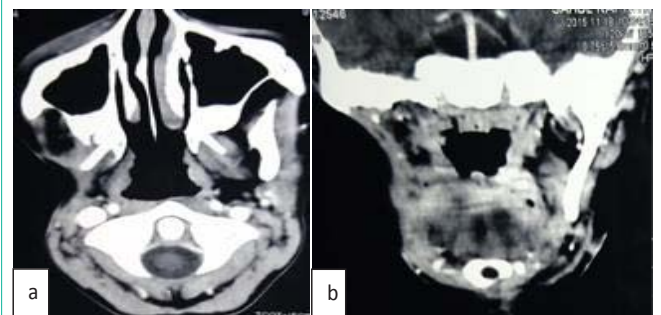


Figure 5: a,b) Coronal and Axial view of CT scan taken one year post operatively showing complete clearance of lesion with no evidence of recurrence.

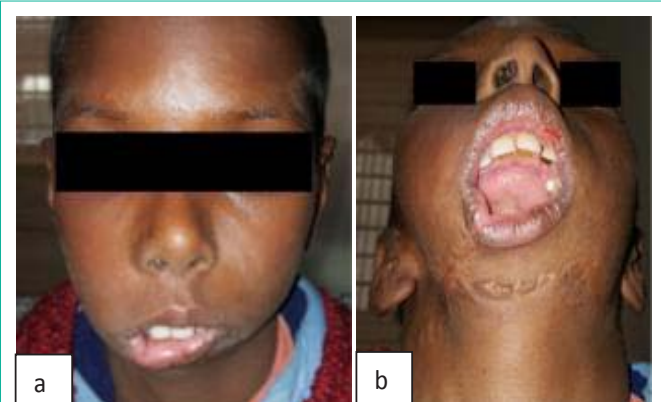

Figure 6: a,b) Post operative photograph of the patient showing well healed wound and adequate opening of mouth.

head and neck osteosarcoma is 3rd to 4th decade of life, a decade later than those usually occurring in the long bones [2,3]. In the paediatric age group osteosarcoma in maxillofacial region is extremely rare. Two types of osteosarcoma have been described, primary and secondary. Primary osteosarcoma is of unknown etiology that may be due to genetic mutation or other environmental factors; whereas secondary osteosarcoma is being seen in cases of previous craniofacial irradiation or in patients with Paget's disease or fibrous dysplasia. In paediatric age group mostly primary osteosarcomas are found.

Craniofacial osteosarcomas usually have nonspecific clinical and radiological features. These tumours commonly present with pain, swelling, paresthesias and ulcerations [4]. Radiologically also, they do not demonstrate the classical features of long bone osteosarcomas. Presence of a large soft tissue mass with extra-osseous osteoid calcifications favors the diagnosis of osteosarcoma [5]. The typical radiological appearance is of ossification pattern in soft tissue showing a "sunburst appearance" however this finding is neither sensitive nor specific for this tumour. CT scan and MRI are essential for determining tumour extent. MRI is superior to CT scan, but in our patient CT scan was done due to financial constrains. Clark et.al, had classified osteosarcoma of the jaw depending on their radiological pattern of lytic, sclerotic and mixed types. They did not find any correlation between the radiological pattern and histological type [6].

Histologically, diagnostic criteria for osteosarcoma are presence of new bone formation or atypical osteoid formation [7]. Our patient did not have these typical histological features, instead it showed

polygonal cells, spindle cells with necrosis and high mitotic figures. Hence, Immunohistochemistry was done to reach a confirmatory diagnosis.

According to Thiele et al the combined treatment with complete resection of the tumour and high dose chemotherapy according to standard protocol is the most effective treatment for craniofacial osteosarcomas [8]. Craniofacial osteosarcomas are considered to be less malignant and have better prognosis than their long bone counterparts.

The case discussed here belongs to low socioeconomic group and downtrodden family. Due to improper medical awareness, poor economic conditions and more faith on indigenous treatment, he presented to us in the advanced stage of disease. Moreover, the blind faith on illiterate local medical practitioners, the irresponsible advertisements published in print media and showed by electronic media for the sake of earning money, the myth about the spread of malignant cells in entire body by surgery and false belief of immediate death due to chemotherapy always come in the way of scientific curative management in the third world countries. The extremely poor and apathetic screening and awareness programmers at Government level always add fuel to the fire in prevention and early disease control.

Our patient presented in an apathetic advanced stage due to such untruthful reasons, hence he absconded from the chemotherapy initially due to the fear of death and became a victim of profit oriented inhuman medical practice which always advertises about a definite cure of cancer by indigenous treatment. The end result was the recurrence. When we adopted strict vigilance and vigorous counseling, we got favourable results.

Conclusion

It can be concluded that osteosarcoma of head and neck region may have atypical clinical, histological and radiological features. The accurate diagnosis is perhaps difficult; treatment might be unpredictable due to diversity in the biological behaviour of the tumour and individual variability. Moreover, the myth and miserable situation in society and poor government armament to control it must be evaluated on a war level. Hence, an understanding of the biological, social and health sector personnel behaviours is still a subject of extensive research in the spectrum of medical science.

References

1. Chaudhary M, Chaudhary SD. Osteosarcoma of jaws. *Oral Maxillofac Pathol.* 2012; 16: 233–238.
2. Kalburge JV, Sahuji SK, Kalburge V, Kini Y. Osteosarcoma of Mandible. *J Clin Diagn Res.* 2012; 6: 1597–1599.
3. Nissanka EH, Amaratunge E APD, Tilakaratne WM. Clinicopathologic analysis of osteosarcoma of the jaw bones. *Oral Diseases.* 2007; 13: 82–87.
4. Jasnau S, Meyer U, Potratz J, Jundt G, Kevric M, Joos UK, et al. Cooperative Osteosarcoma Study Group COSS: Craniofacial osteosarcoma. Experience of the cooperative German-Austrian-Swiss osteosarcoma study group. *Oral Oncol.* 2008; 44: 286-294.
5. Wang S, Shi H, Yu Q. Osteosarcoma of the jaws: demographic and CT imaging features, *Dentomaxillofac Radiol.* 2012; 41: 37–42.
6. Clark JL, Unni KK, Dahlin DC, Devine KD. Osteosarcoma of the jaw. *Cancer.* 1983; 51: 2311-2316.
7. Bertoni F, Dalleria P, Bacchini P, Marchetti C, Campobassi A. The Istituto Rizzoli-Beretta experience with osteosarcoma of the jaw. *Cancer.* 1991; 68: 1555–1563.
8. Thiele, Freier K, Bacon C, Egerer G, Hofele CM. Interdisciplinary combined treatment of craniofacial osteosarcoma with neoadjuvant and adjuvant chemotherapy and excision of the tumor: a retrospective study. *Br J Oral Maxillofac Surg.* 2008; 46: 533–546.