

## Case Report

# Distal Interphalangeal Joint (DIPJ) Soft Tissue Interpositional Arthroplasty

**Bettina Wai Yan Fung, Chris Yuk Kwan Tang\*, Boris Kwok Keung Fung, Margaret Fok**

Department of Orthopaedics and Traumatology, Queen Mary Hospital, Hong Kong

**\*Corresponding author:** Chris Yuk Kwan Tang, Department of Orthopaedics and Traumatology, Queen Mary Hospital, Hong Kong, Email: mathshouse@yahoo.com.hk

**Received:** May 24, 2014; **Accepted:** August 08, 2014; **Published:** August 13, 2014

## Abstract

Distal interphalangeal joint (DIPJ) arthritis can lead to pain, deformity, weakness or functional deficit. Traditionally, surgical management for DIPJ arthritis includes arthrodesis, silicone interpositional arthroplasty and rarely total joint replacement. We performed a new technique in a patient with DIPJ osteoarthritis secondary to psoriatic arthritis. Excisional arthroplasty followed by interpositional arthroplasty with extensor retinaculum from the left wrist was performed. Physical examination at one year post-operatively showed left thumb interphalangeal joint had flexion of 35 degrees with 5 degrees extension lag. He was pain-free over the operated joint. This new soft tissue interpositional arthroplasty can maintain mobility; relieve pain without foreign artificial materials. The authors therefore recommend it as an alternative to the existing options with comparable outcomes.

## Introduction

Arthritis affecting distal interphalangeal joints (DIPJ) can be due to inflammatory causes such as psoriatic arthritis or non-inflammatory causes such as osteoarthritis. It mainly leads to the problems of pain, deformity, weakness or functional deficit. Surgical treatment for the arthritis of the distal interphalangeal joint includes arthrodesis, silicone interpositional arthroplasty and rarely total joint replacement. Each method has its own limitations. We report a patient with soft tissue interpositional arthroplasty by using wrist extensor retinaculum over left thumb interphalangeal joint, which has not yet been described in literature. The result is comparable to the contemporary management options and can be considered as an alternative.

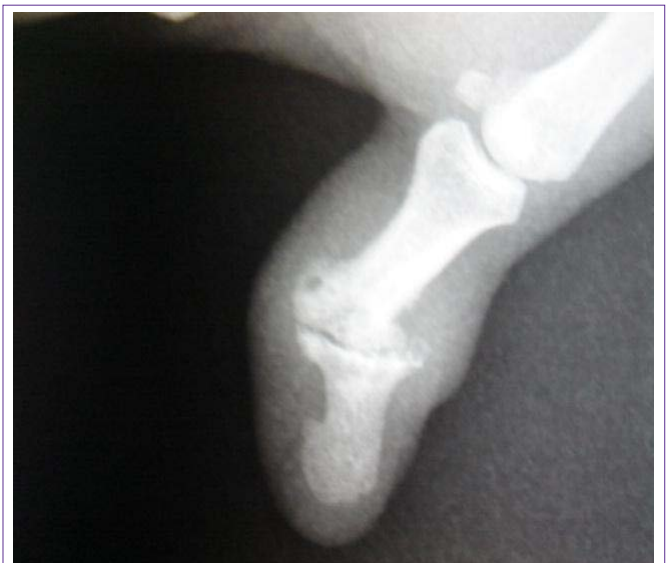## Case Presentation

A 59 year-old man with psoriatic arthropathy had secondary osteoarthritis over the left thumb interphalangeal joint and radial deviation of the joint. He also had pain and disability over the affected joint (Figure 1). Various options including joint fusion and arthroplasty were discussed and patient decided to go for interpositional arthroplasty because he wanted to preserve mobility of the interphalangeal joint. General anesthesia was used. A longitudinal incision was made over the left thumb dorsal interphalangeal joint (IPJ). Extensor pollicis longus was split longitudinally for exposure of IPJ. The joint with the unhealthy cartilage was debrided and leveled. A rectangular space was created symmetrically over the joint. Extensor retinaculum was then harvested from the left wrist and interposed into IPJ. Collateral ligament over radial sided IPJ were retightened and plicated to correct the laxity. Kirschner wire was inserted in a retrograde manner across the IPJ for stabilization. The K-wire was kept for 3 weeks (Figure 2). Concomitant synovectomy at the wrist was performed because he also had synovitis. Skin was closed. A mallet splint was given post-operatively for 3 weeks. Free active mobilization was allowed afterwards. Gradual strengthening was then started. Physical examination at one year post-operatively

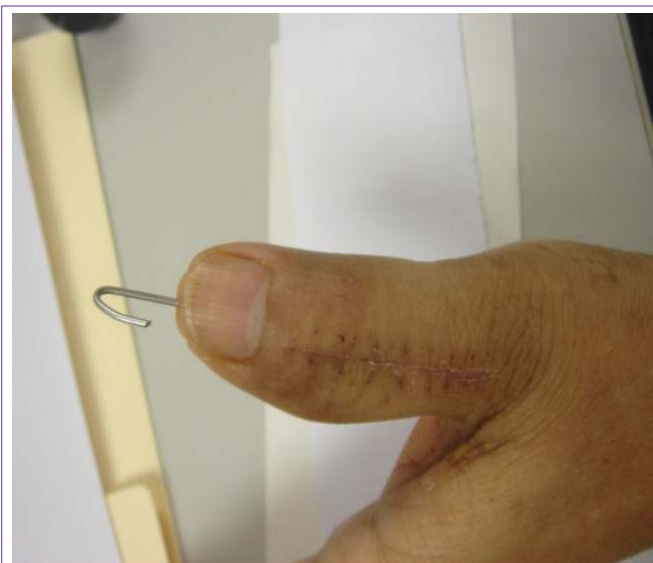
showed left thumb interphalangeal joint had flexion of 35 degrees with 5 degrees extension lag (Figure 3,4 & 5). He was pain-free over the operated joint.

## Discussion

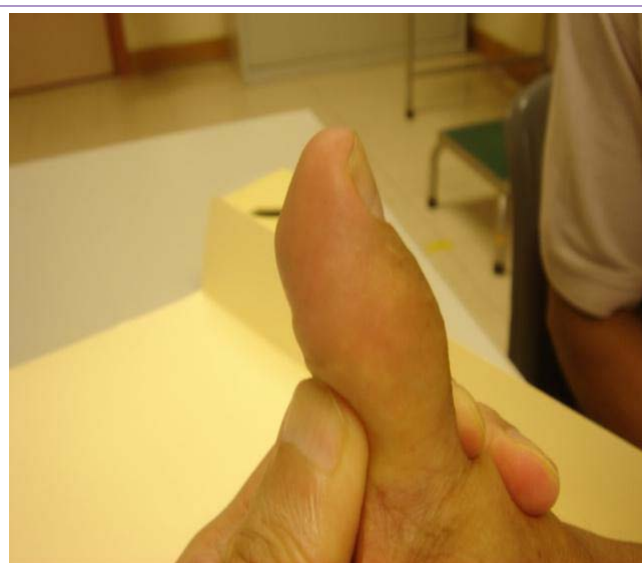Surgical treatment for the arthritis of the distal interphalangeal joint (DIPJ) includes arthrodesis and silicone interpositional arthroplasty. For DIPJ arthrodesis by Kirschner wire, cerclage wire or Herbert screw, major complications (non-union, malunion, infection) occurred in 20% of patients, while minor complications (skin necrosis, cold intolerance, proximal interphalangeal joint stiffness, superficial wound infection, or prominent implant) occurred in 16% of patients [1]. One study showed only 4% non-union rate with oblique placement of an AO lag screw [2]. Silicone has been the traditional material used in interpositional arthroplasty for years



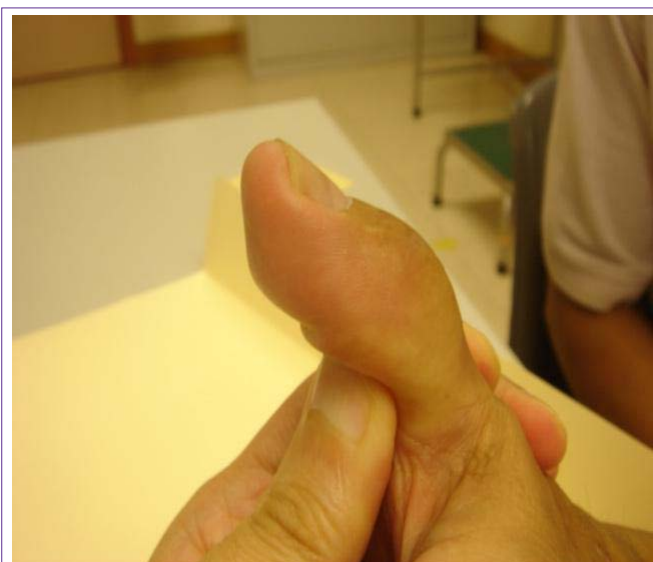
**Figure 1:** Pre-operative radiograph of left thumb interphalangeal joint showing the deformity.



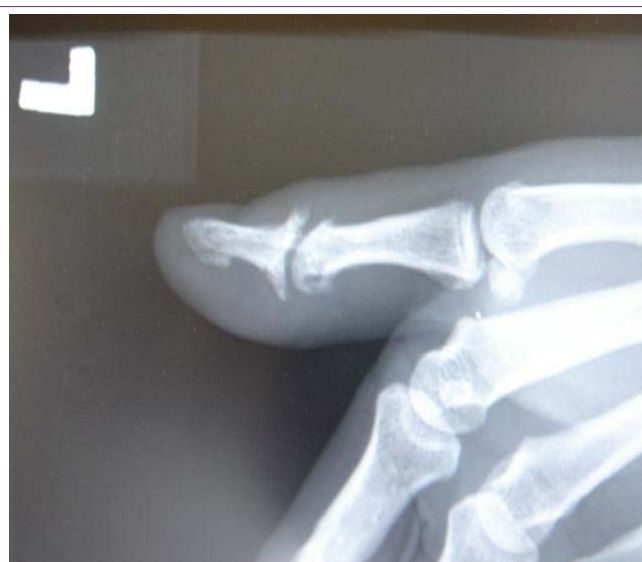**Figure 2:** Early post-operative period with Kirschner wire in-situ.



**Figure 4:** 5 degrees of extension lag at one year post-operatively.



**Figure 3:** Flexion of 35 degrees at one year post-operatively.



**Figure 5:** Post-operative radiograph of left thumb at 1 year post-operatively.

with satisfactory results. In a case series, the average retained range of motion was 33 degrees with satisfactory stability but 10 degrees extension lag [3]. Theoretically, silicone interpositional arthroplasty of DIPJ achieves less pinch power than arthrodesis, although further studies are needed to validate this. Total joint replacement for DIPJ arthritis, though not commonly performed, remains one of the options for treatment. Sierakowski reviewed 131 patients with distal interphalangeal joint arthritis treated by total joint replacement. The patients can achieve a greater range of 39 degrees with the same degree of extension lag. Complications rate was 5% in terms of cellulitis, osteomyelitis, instabilities and deformities [4].

Unlike in patients with primary osteoarthritis, there are a few considerations for the surgery regarding patients with psoriasis. Concentrations of bacteria are greater in psoriatic plaques, but the higher risk of infection is controversial. Lynfield [5] showed that standard perioperative disinfection over the plaques by iodine and alcohol successfully sterilized the plaques in all patients. Wound

healing may be complicated by Koebner phenomenon. However, study showed that psoriatic skin healed at the same rate as normal skin [5]. Studies regarding pre-operative medication management for psoriatic arthritis are lacking, but recommendations can be made based on the studies of rheumatoid arthritis patients. Biologics should be withheld before operation, exact timing depends the half-life of each drug. They can be resumed after stitch removal and when the wound is healing well without features of infection, usually at 2 weeks post-operatively. Methotrexate can be continued because there is a reduction in disease exacerbations without an increase in wound complications [6,7].

Advantage of this technique includes no risk of implant-related infection and foreign body reaction since the interpositional material is autologous, whereas the range of motion, stability, pain control and cosmetic appearance are comparable to total joint replacement. If only single digit is involved, the operation can be done under local anesthesia with digital block. If operation involves multiple digits, a

site where a bigger harvest such as fascia lata is needed under general anesthesia. General anesthesia had been used in this patient because concomitant synovectomy was performed. Disadvantages of this technique include the need of using unhealthy, attenuated soft tissue for balancing. There is a chance of future reversal of the deformity. Moreover, similar to other types of interpositional, it also has the potential drawback of less pinch power compared to arthrodesis.

In conclusion, interpositional arthroplasty with extensor retinaculum is a new possible alternative surgical option for interphalangeal joint arthritis, while further study involving a larger number of patients with long-term outcome is needed.

## References

1. Stern PJ, Fulton DB. Distal interphalangeal joint arthrodesis: an analysis of complications. *J Hand Surg Am.* 1992; 17: 1139-1145.
2. Teoh LC, Yeo SJ, Singh I. Interphalangeal joint arthrodesis with oblique placement of an AO lag screw. *J Hand Surg Br.* 1994; 19: 208-211.
3. Wilgis EF. Distal interphalangeal joint silicone interpositional arthroplasty of the hand. *Clin Orthop Relat Res.* 1997; 38-41.
4. Sierakowski A, Zweifel C, Sirotakova M, Sauerland S, Elliot D. Joint replacement in 131 painful osteoarthritic and post-traumatic distal interphalangeal joints. *J Hand Surg Eur Vol.* 2012; 37: 304-309.
5. Lynfield YL, Ostroff G, Abraham J. Bacteria, skin sterilization, and wound healing in psoriasis. *N Y State J Med.* 1972; 72: 1247-1250.
6. Scanzello CR, Figgie MP, Nestor BJ, Goodman SM. Perioperative management of medications used in the treatment of rheumatoid arthritis. *HSS J.* 2006; 2: 141-147.
7. Grennan DM, Gray J, Loudon J, Fear S. Methotrexate and early postoperative complications in patients with rheumatoid arthritis undergoing elective orthopaedic surgery. *Ann Rheum Dis.* 2001; 60: 214-217.