

Special Article - Surgical Case Reports

Endometriosis of the Appendix Masquerading as Appendicitis in a 34-Week Pregnant Woman: Case Report and Review of the Literature

Collom ML¹, Bajwa KS¹, Mehta SS¹, Walker PA¹ and Shah SK^{1,2*}

¹Department of Surgery, University of Texas Medical School at Houston, USA

²Michael E. DeBakey Institute for Comparative Cardiovascular Science and Biomedical Devices, Texas A&M University, USA

*Corresponding author: Shinil K Shah, Department of Surgery, University of Texas Medical School at Houston, USA, Tel: (281) 841-6034; Email: Shinil.K.Shah@uth.tmc.edu

Received: November 15, 2014; Accepted: November 24, 2014; Published: November 25, 2014

Abstract

Endometriosis is most commonly found in women of childbearing age with the most common sites of disease being the ovaries, uterine ligaments, recto and vesicovaginal areas, pelvic peritoneum, cervix, labia and vagina. Endometriosis of the appendix is an extremely rare finding. In this report we describe a patient in her 3rd trimester of pregnancy that presented with acute abdominal pain with clinical examination, laboratory investigation and imaging consistent with acute appendicitis. She underwent laparoscopic appendectomy without complication but with the surprising pathological diagnosis of endometriosis of the appendix. We discuss the management and relevant literature of the diagnosis of endometriosis of the appendix in pregnancy.

Keywords: Endometriosis; Appendix; Appendicitis; Pregnancy

Case Presentation

The patient presented is a 32-year-old woman who was 34 and 3/7th weeks pregnant. She presented to our facility with approximately 24 hours of right-sided abdominal pain associated with nausea and fevers. She did not report any similar previous episodes of pain. Her past medical and surgical history was unremarkable. She was febrile to 101F and her clinical examination demonstrated right sided abdominal tenderness with some localized guarding and rebound tenderness. Her laboratory studies were remarkable for a white blood cell count of 12.1 k/uL (reference range 4.5 – 11 k/uL) with left shift (86.1% neutrophils). The rest of her laboratory workup was essentially normal. An abdominal ultrasound demonstrated a dilated blind ending tubular structure in the right lower abdomen with tenderness noted over the structure consistent with a diagnosis of acute appendicitis (Figure 1).

Given suspicion for acute appendicitis, she was taken to the operating room for planned laparoscopic appendectomy. On examination, the appendix was noted to be inflamed with fibrinous exudates and no evidence of perforation, consistent with a clinical diagnosis of acute appendicitis. She was discharged on post-operative day 1 after an uneventful hospital stay.

Quite surprisingly, surgical pathology revealed no acute or chronic inflammation involving the appendiceal mucosa. Extensive decidual changes forming transmural nodules involving all layers of the appendiceal wall and periappendiceal soft tissues were noted with glandular structures noted in the area of decidual changes. Immunostaining for keratin (pancytokeratin), PAX8, vimentin, and calretinin on the epithelial structures surrounded by decidual tissue demonstrated PAX8 positivity for nuclei and keratin positivity for the cytoplasm. Stains for calretinin and vimentin were negative. Overall, the findings suggested transmural endometriosis of the appendix with extensive decidual changes.

At follow-up, the patient was doing well. She had no complications related to the pregnancy and delivered approximately 1 month after her operation.

Discussion

Endometriosis of the appendix was first described by von Rokitansky in 1860 [1]. Although it is associated with pelvic pain, its clinical presentation can be varied. The development of endometriosis is still not entirely understood. There are several different etiologies that have been hypothesized, but the most widely accepted mechanism is retrograde menstruation from the fallopian tube into the peritoneum [2]. The most common location of an endometrial implant is the female pelvis, but it can occasionally be found in the umbilicus, kidney, lung, skin and diaphragm [3]. The gastrointestinal tract is affected very rarely and the percentage varies according to location. The recto-sigmoid (72%) and recto-vaginal septum (13%) are most commonly affected followed by the small intestine (7%), cecum (3.6%) and rarely the appendix (3%) [4]. In the gastrointestinal tract, endometriosis deposits usually only involve the serosa and subserosa. It is rare for the deposit to involve the muscularis propria, but if it does it typically causes symptoms and fibrosis [5]. The only gold standard for the diagnosis of endometriosis of the appendix is laparoscopy or laparotomy.

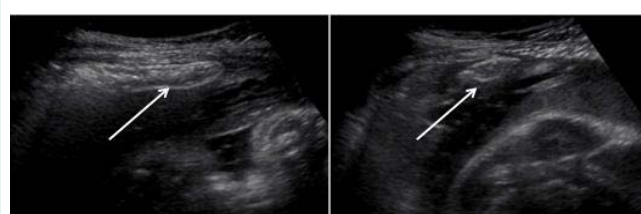


Figure 1: Abdominal ultrasound demonstrated a tubular structure (arrow) in the right lower quadrant. It measured 4.3 cm in length and 1.1 cm in diameter, consistent with a dilated appendix.

There are approximately twenty reported cases of endometriosis presenting as acute appendicitis during pregnancy [6-21]. The reported case is one of the more advanced gestational age presentations reported; there are three other cases in more advanced stages of pregnancy, (35 weeks gestation (2 cases), and at term (1 case) [14,15,20]. Additionally, most of the reported cases have occurred in women under the age of thirty, with two cases reported in individuals older than our reported patient (33 and 35 years old) [6,7].

Interestingly, in our patient, there was no pathologic evidence of acute appendicitis in the specimen. This is surprisingly a common finding. A large review of pathology specimens in patients treated for appendicitis demonstrated 14 cases of endometriosis in 4670 patients. In these specific cases, only 36% of specimens (5 cases) had evidence of acute inflammation in addition to findings of endometriosis [22].

It is interesting that our patient presented with signs and symptoms of acute appendicitis but without a pathological diagnosis of appendicitis. The presentation of patients with endometriosis of the appendix is varied. It is thought that bleeding and proliferation of ectopic endometrial tissue contributes to edema, inflammation, and luminal occlusion. Similar to endometriosis, cyclical pain may also be present [23]. The relatively high incidence of perforation noted during pregnancy is thought to be related to growth of endometrial tissue as a response to pregnancy related hormonal changes [21].

As with appendicitis in pregnancy, in the majority of the reported cases, open laparotomy either through a midline or transverse incision was required for treatment [6-20]. When the operative details were reported, there has been one reported case utilizing laparoscopy for the treatment of appendicitis secondary to endometriosis; in this case, an incidental carcinoid tumor was also discovered [11]. Pre term labor and delivery as well as fetal demise has been reported in certain cases, especially when perforation of the appendix is noted [7,19]. As with other cases of suspected appendicitis, timely intervention is key to preventing pregnancy related complications [24].

Conclusion

Endometriosis of the appendix presenting during pregnancy is an extremely rare presentation of appendicitis. It requires a high degree of suspicion amongst clinicians and most often, the diagnosis is made after definitive treatment. As with all cases of acute appendicitis in pregnancy, clinical suspicion should prompt quick intervention to prevent perforation and pregnancy related complications.

References

- Rokitansky C. Uber Uterusdrüsen-Neubildung in Uterus- und Ovarial-Sarcomen. *Z Ges Aerzte Wien*. 1860; 16: 577-581.
- Zondervan KT, Cardon LR, Kennedy SH. The gastrointestinal endometriosis. *Curr Opin Obstet Gynecol*. 2001; 13: 126-128.
- Olive DL, Schwartz LB. Endometriosis. *N Engl J Med*. 1993; 328: 1759-1769.
- Macafee CH, Greer HL. Intestinal endometriosis. A report of 29 cases and a survey of the literature. *J Obstet Gynaecol Br Emp*. 1960; 67: 539-555.
- Yantiss RK, Clement PB, Young RH. Neoplastic and pre-neoplastic changes in gastrointestinal endometriosis: a study of 17 cases. *Am J Surg Pathol*. 2000; 24: 513-524.
- Giorgakis E, Karydakis V, Farghaly A. Perforated endometrial appendicitis in pregnancy. *Hippokratia*. 2012; 16: 181-183.
- Lebastchi AH, Prieto PA, Chen C, Lui FY. Appendiceal endometriosis in a pregnant woman presenting with acute perforated appendicitis. *J Surg Case Rep*. 2013.
- Dogan E, Okyay E, Saatli B, Olgan S, Sarioglu S, Koyuncuoglu M. Tuba ovarian abscesses formation from decidualized ovarian endometrioma after appendiceal endometriosis presenting as acute appendicitis in pregnancy. *Iran J Reprod Med*. 2012; 10: 275-278.
- Perez CM, Minimo C, Margolin G, Orris J. Appendiceal endometriosis presenting as acute appendicitis during pregnancy. *Int J Gynaecol Obstet*. 2007; 98: 164-167.
- Faucheron JL, Pasquier D, Voirin D. Endometriosis of the vermiform appendix as an exceptional cause of acute perforated appendicitis during pregnancy. *Colorectal Dis*. 2008; 10: 518-519.
- Dimitriadis PA, Makar RR, Kingston G, Farouk R. Appendiceal endometriosis and carcinoid presented as acute appendicitis in pregnancy: a rare case report and review of the literature. *Case Rep Obstet Gynecol*. 2013; 2013: 360-459.
- Nakatani Y, Hara M, Misugi K, Korehisa H. Appendiceal endometriosis in pregnancy. Report of a case with perforation and review of the literature. *Acta Pathol Jpn*. 1987; 37: 1685-1690.
- Silvestrini IE, Marcial MA. Endometriosis of the appendix with decidual polyp formation: a rare cause of acute appendicitis during pregnancy. *P R Health Sci J*. 1995; 14: 223-225.
- Lofwander M, Haugen G, Hammarstrom C, Rokke O, Mathisen O. [A pregnant woman with abdominal pain and fever]. *Tidsskr Nor Laegeforen*. 2007; 127: 2528-2529.
- Gini PC, Chukudebelu WO, Onuigbo WI. Perforation of the appendix during pregnancy: a rare complication of endometriosis. Case report. *Br J Obstet Gynaecol*. 1981; 88: 456-458.
- Stefanidis K, Kontostolis S, Pappa L, Kontostolis E. Endometriosis of the appendix with symptoms of acute appendicitis in pregnancy. *Obstet Gynecol*. 1999; 93: 850.
- Pigne A, Faguer C, Giorgi H, Barrat J, Jouhet P, Treisser A. [Appendiceal endometriosis disclosed by pregnancy]. *Med Chir Dig*. 1980; 9: 721-722.
- Cutait R, Borges JL, Camara-Lopes LH, Ramos L, Calache JE, Lourenco JL, et al. [Endometriosis of the vermiform appendix inducing acute appendicitis in a pregnant woman]. *Rev Paul Med*. 1980; 96: 77-78.
- Finch DR, Lee E. Acute appendicitis complicating pregnancy in the Oxford region. *Br J Surg*. 1974; 61: 129-132.
- Tedeschi LG, Masand GP. Endometriosis of the intestines: a report of seven cases. *Dis Colon Rectum*. 1971; 14: 360-365.
- Yoon J, Lee YS, Chang HS, Park CS. Endometriosis of the appendix. *Ann Surg Treat Res*. 2014; 87: 144-147.
- Chandrasegaram MD, Rothwell LA, An EI, Miller RJ. Pathologies of the appendix: a 10-year review of 4670 appendectomy specimens. *ANZ J Surg*. 2012; 82: 844-847.
- Astroza G, Faundes V, Nanjari R, Fleiderman M, Rodriguez C. Appendiceal endometriosis differentially diagnosed from acute appendicitis. *Chin Med J (Engl)*. 2010; 123: 1610-1611.
- Al-Fozan H, Tulandi T. Safety and risks of laparoscopy in pregnancy. *Curr Opin Obstet Gynecol*. 2002; 14: 375-379.