

Case Series

Tension-Free Repair of Inguinal Hernia with “Undissociate Spermatic Cord”- Case Series

Zhao L^{1#}, Song X^{2#}, Li H¹, Yu H², Li Z¹, Li J¹ and Xu J^{1*}¹Department of Oncological and Laparoscopic Surgery, First Hospital of Harbin Medical University, China²Department of General Surgery, First Hospital of Harbin, China

#Equal Contribution.

***Corresponding author: Jun Xu**

Department of Oncological and Laparoscopic Surgery, First Hospital of Harbin Medical University, China

Received: February 13, 2023; **Accepted:** March 21, 2023; **Published:** March 28, 2023**Abstract**

Background: In recent years, with the deepening of the anatomical cognition of the inguinal region and the renewal of the hernia repair concept, inguinal hernia repair has become increasingly mature surgical approach. However, no matter how the hernia repair modes change, the treatment and repair of the hernia ring has always been the focus, so that the treatment of the hernia sac has been neglected.

Materials and Methods: From March 2014 to May 2019, there were 132 patients underwent inguinal hernia repair with “Undissociate Spermatic cord” theory (Undissected Spermatic cord and hernia sac, hernia ring and sac exclusion) in the First Affiliated Hospital of Harbin Medical University and the First Hospital of Harbin.

Results: All the operations were completed smoothly. The patients included 126 males and 6 females. There were 74 cases underwent open surgery and 58 cases underwent laparoscopic surgery (TAPP and TEP). In the open group, the mean operation time was 33.4min, and the mean blood loss was 7.1ml. The mean hospitalization time was 4.6d. In the laparoscopic group, the mean operation time was 74.4min, and the mean blood loss was 7.5ml. The mean hospitalization time was 4.7d. There were no complications occurred in our groups. All the patients were followed up for 18~63 months (mean of 41.5 months) without recurrence.

Conclusion: Following the “Undissociate Spermatic cord” theory, the inguinal hernia repair could be convenient operation, low complication rate and recurrence rate. The function of spermatic cord was also retained. “Undissociate Spermatic cord” theory is a safe and feasible novel idea for inguinal hernia repair.

Keyword: Undissociate spermatic cord; Inguinal hernia; Hernia exclusion; Hernial sac

Introduction

In recent years, with the deepening of the anatomical cognition of the inguinal region and the renewal of the hernia repair concept, inguinal hernia repair has become increasingly mature surgical approach [1,2]. However, no matter how the hernia repair modes change, the treatment and repair of the hernia ring has always been the focus, so that the treatment of the hernia sac has been neglected. However, during the process of dissociating the spermatic cord and separating the hernia sac, the

spermatic cord and its surrounding tissues are often damaged, resulting in unnecessary bleeding, seroma, testicular ischemia, pain and other complications [3]. Therefore, we put forward the concept of "undissected spermatic cord (US)" in tension-free repair of inguinal hernia. From March 2014 to October 2018, 132 patients of inguinal hernia successfully underwent tension-free repair with US. This study describes the application of US in tension-free repair of inguinal hernia.

Materials and Methods

Patient Selections and Post-Operation

In this study, 132 consecutive patients were enrolled. All patients were diagnosed based on clinical, laboratory and radiological findings. The inclusion criteria were age 18~65 years, indirect inguinal hernia, while the exclusion criteria were incarcerated hernia, strangulated hernia, direct hernia, femoral hernia, and recurrent hernia.

And the operation time, blood loss, complications, cancer stages et al. were collected by authors. All the patients were followed up 2 years, unless the patients were out of touch or deaden. Our study was approved by the Ethics Committee of First Hospital of Harbin Medical University and were conducted according to the principles outlined in the Declaration of Helsinki. Our experiment has been registered on the website of Clinical Trail (NCT05247983).

Surgical Methods

An oblique incision about 4cm length was made 2~3cm above the inguinal ligament. The aponeurosis of the external oblique was open to enter the inguinal ring. A longitudinal and small incision was made in the cremaster at the inguinal ring (for women, incision was made through the subcutaneous ring to the inner ring).

Expose the ventral peritoneum of the hernia ring and open the peritoneum. The peritoneum was division from the hernia ring and hernia sac was putting-aside (Figure 1A). The peritoneum was closed and 2 suture lines were kept (Figure 1B).

The preperitoneal space was dissociated: lower to the pectineal ligament, upper to the internal oblique, inside to the symphysis pubis, and outside to the iliopsoas. According to the diameter of the hernia ring, a mesh with a diameter of at least 10cm was inserted into the preperitoneal space, and the retained suture line was used to "fix" the mesh (Figure 1C). Then, close the aponeurosis of the external oblique and the incision. Transabdominal Preperitoneal(TAPP) and Total Extraperitoneal Repair(TEP) had followed the same procedure (Figure 1D).

The work has been reported in line with the PROCESS criteria [4].

Table 1: Patient Characteristics and Operative Data.

	Open (n=74)	Laparoscopic (TAPP+TEP, n=58)
Male	68	58
Female	6	0
BMI	24.5±3.0	23.5±1.7
Hernia Ring (cm)	1.4±0.6	2.1±0.6
Operation time (min)	33.4±7.5	74.4±14.0
Blood loss (ml)	7.1±5.6	7.5±4.6
Hospitalization time	4.6±1.8	4.7±1.2

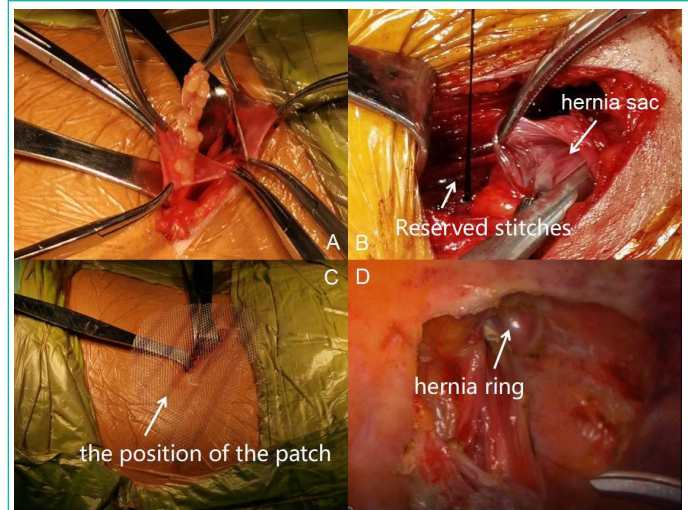


Figure 1: Operation procedure of inguinal hernia repair following the concept of "US". A. Transverse the peritoneum at the ventral side of the hernia ring, and pay attention to protecting and restoring the hernia contents; B. Peritoneal notch was sutured; C. "Fix" the center of the patch with stitching thread and lay the mesh flat in the preperitoneal space; D. Laparoscopic TAPP: look for the hernia ring at the inner ring opening and cut off the peritoneum annulus, opening the hernia structure.

Results

A total of 132 patients underwent Tension-free repair of inguinal hernia without dissected spermatic cord smoothly. There were 74 cases underwent open surgery and 58 cases underwent laparoscopic surgery (TAPP and TEP). In the open group, the average operation time was 33.4min (25~55), the average hernia ring was 1.4cm (0.5~2.9), and the mean blood loss was 7.1ml (0~30). The mean hospitalization time was 4.6d (2~9). In the laparoscopic group, the average operation time was 74.4min (35~90), the average hernia ring was 2.1cm (1.1~3), and the mean blood loss was 7.5ml (0~20). The mean hospitalization time was 4.7d (2~7). There were no complications occurred in our groups. The results were showed in (Table 1). All the patients were followed up for 18~63 months (mean of 41.5 months) without recurrence.

Discussion

The treatment strategy of inguinal hernia has been constantly updated and improved with the changes, innovations and development of its treatment strategy and surgical techniques. From Bassini to Lichtenstein tension-free hernia repair, as well as the proposal of the concept of pectineal foramen, each new concept has brought about revolutionary changes in the way of hernia repair.

However, over the past 100 years, these technological improvements, characterized by the change of the repair location, had not involved the treatment of the hernia sac, another important point in hernia repair. Therefore, there was a little attention to avoid the damage to the spermatic cord and surrounding tissues caused by the separation of the hernia ring and sac, as well as a series of complications. In that case, we proposed the theory of "undissected Spermatic cord (US)". That is, in adult inguinal hernia repair, only transected the hernia ring ends in the abdominal cavity, the hernia ring, hernia sac and spermatic cord will not be dissected. Its significance lies in that inguinal hernia repair can get rid of the "entanglement" of hernia sac and spermatic cord and fundamentally change the treatment mode of hernia ring and hernia sac. The hernia rings and hernia sacs,

which excluded used US, we call them "hernia composite structures". This kind of operation without dissociating the "hernia composite structures" was called "hernia composite structure exclusion". Up to now, "hernia structure composite exclusion" was the only operation method to realize the theory of "US", which can be regarded as another term of "US". And with US, there were no complications such as hydrocele of testes in our research.

Inguinal hernia repair under the guidance of "US" has the following advantages. Firstly, the cosmetic incision. Since it is more convenient to enter the preperitoneal space through the inner ring, about 4cm incision is generally enough. Secondly, avoid damage to spermatic cord and related structures. US had ensured the integrity of the testis muscle, avoid testicular atrophy, ischemic orchitis testis reflex weakened or disappeared, testicular distension and other complications caused by spermatic cord injury. Thirdly, without the procedure of separating spermatic cord and hernia sac, the operation time was shortened, especially for the patients with large hernia sac or the hernia sac adhesion with the spermatic cord strongly. Fourthly, the special patch fixation method can reduce the incidence of chronic pain after operation. Chronic pain refers to postoperative pain lasting for more than 3 months, mainly due to the intraoperative suture [5]. Researches showed that 10%~12% of inguinal hernia repair patients have chronic pain after surgery, and 2%~4% of patients need medical treatment [6]. In our study, without dissected the spermatic cord and stitched, the risk of collateral nerve damage in the inguinal region was also reduced. Fifthly, Health care costs are saved with US. Because the operation procedure is simplified, surgeons can serve more patients. And faster patient recovery also reduces hospital stay and patient costs. Lastly, in our long-term followed up, the recurrence rate was not increased.

In summary, "US" is a new concept of surgical hernia repair. Following the concept of "US" could retains the functions of the inguinal canal and spermatic cord to the greatest extent and reduces complications. Our study suggests that US is a safe and feasible new technique for hernia repair, but more cases are needed to verify this validity.

Conclusion

Following the "Undissociate Spermatic cord" theory, the inguinal hernia repair could be convenient operation, low complication rate and recurrence rate. The function of spermatic cord was also retained. "Undissociate Spermatic cord" theory is a safe and feasible novel idea for inguinal hernia repair.

Ethical Statement

Compliance with Ethical Standards: All processes involved in this study and all authors abide by the code of Ethical Standards

Funding

This study was funded by the Natural Science Foundation of China (grant no. 81902421), the China Postdoctoral Science Foundation (grant no. 2018M641863) and a grant from the First Hospital of HMU (grant no. 2019B22).

Conflict of Interest

Lei Zhao, Xue Song, Huiying Li, Hong Yu, Zhengtian Li, Jun LiandJun Xudeclare that they have no conflict of interest.

References

1. Chen D C, Poulouse B K. Clinical Guidelines Synopsis of Groin Hernia Management. *JAMA Surgery*. 2020; 155: 980-981.
2. Hewitt D B, Chojnacki K. Laparoscopic Groin Hernia Repair. *Jama*. 2017; 318: 1294.
3. Fortelny RH, Petter Puchner AH. A method for the reduction of chronic pain after tension-free repair of inguinal hernia: iliohypogastric neurectomy and subcutaneous transposition of the spermatic cord. *Hernia: the journal of hernias and abdominal wall surgery*. 2010; 14: 229-230.
4. Agha RA, Sohrahi C, Mathew G, Franchi T, Kerwan A, et al. The PROCESS 2020 Guideline: Updating Consensus Preferred Reporting Of Case Series in Surgery (PROCESS) Guidelines, *International Journal of Surgery*. 2020; 84: 231-235.
5. Alfieri S, Amid PK, Campanelli G, Izard G, Kehlet H, et al. International guidelines for prevention and management of postoperative chronic pain following inguinal hernia surgery. *Hernia: the journal of hernias and abdominal wall surgery*. 2011; 15: 239-249.
6. Niebuhr H, Wegner F, Hukauf M, Lechner M, Fortelny R, et al. What are the influencing factors for chronic pain following TAPP inguinal hernia repair: an analysis of 20,004 patients from the Herniated Registry. *Surgical endoscopy*. 2018; 32: 1971-1983.