

## Case Report

# Surgical Management of a Strangulated Amyand's Hernia in an Emergency Situation: A Practical Approach

Ouhammou Yousra<sup>1\*</sup>; Dady Mohammed<sup>1</sup>; Laamri Imad<sup>1</sup>; Maouni Ilyass<sup>1</sup>; Abou Elalaa Khalil<sup>2</sup>; El Alami Fahd Hassan<sup>1</sup>

<sup>1</sup>Department of the Emergency Surgery (UCV) - Ibn Sina University Hospital, Rabat, Faculty of Medicine and Pharmacy of Rabat, Mohammed V University in Rabat, Morocco

<sup>2</sup>Department of Anesthesiology and Intensive Care, Head of the Operating Room Theatre Military Hospital Mohammed V, Faculty of Medicine and Pharmacy of Rabat, Mohammed V University in Rabat, Morocco

**\*Corresponding author: Ouhammou Y**

Department of the Emergency Surgery (UCV) - Ibn Sina University Hospital, Rabat, Faculty of Medicine and Pharmacy of Rabat, Mohammed V University in Rabat, Morocco.

Email: ouhammouyousra2017@gmail.com

**Received:** August 02, 2023

**Accepted:** September 15, 2023

**Published:** September 22, 2023

## Introduction

A strangulated Amyand's hernia presents a unique and rare surgical emergency. The presence of the appendix within an inguinal hernia is estimated to occur in approximately 1% of cases, with inflammation found in only 0.1% [4]. The clinical presentation of a strangulated Amyand's hernia often manifests with acute symptoms, necessitating immediate intervention. While imaging techniques such as CT scan and ultrasound are valuable diagnostic tools, in certain emergency situations, prompt access to these imaging modalities may not be feasible. Consequently, an immediate surgical exploration becomes essential for timely decision-making and management [5].

The rarity and distinctive clinical presentation of a strangulated Amyand's hernia make it of significant scientific interest. Published cases contribute to expanding our understanding of this condition, particularly in circumstances where immediate imaging studies are not readily available. By presenting an illustrative observation of a strangulated Amyand's hernia managed through urgent surgical exploration, this article aims to high-

## Abstract

Amyand's hernia is a rare condition characterized by the presence of the appendix within an inguinal hernia. Although rarely seen, strangulated Amyand's hernia is a surgical emergency requiring immediate management to avoid potentially serious complications.

This condition, named after the French surgeon Claudius Amyand [1], is estimated to affect around 1% of inguinal hernia cases, with a prevalence of appendicular inflammation of only 0.1% [2]. It is more common in children, due to the permeability of the vaginal process [3].

In such situations, a practical approach involving immediate surgical exploration is warranted. Prompt treatment is essential to avoid serious complications, such as appendicular perforation or peritonitis. Surgical expertise, careful clinical assessment and patient-centered decision-making are essential for the successful management of these emergency cases.

In conclusion, strangulated Amyand's hernia is a rare condition that requires prompt surgical management. In emergency situations, early surgical exploration is recommended to avoid potential complications. This clinical observation illustrates the importance of practical decision-making in the management of such emergency cases, and highlights the need for a multidisciplinary approach involving surgical expertise and thorough clinical evaluation.

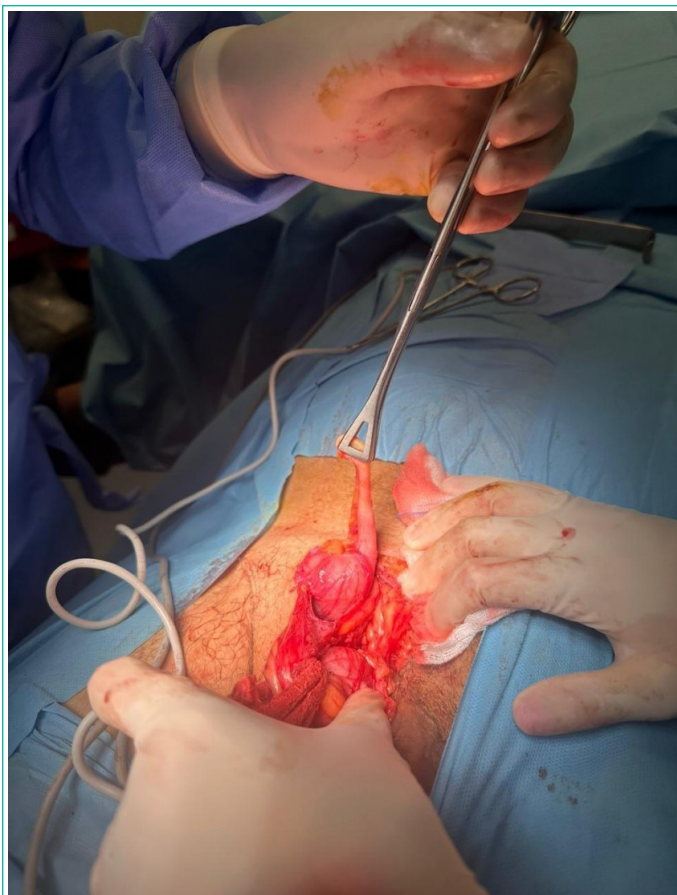
**Keywords:** Amyand's hernia; Strangulation; Surgical emergency; Surgical exploration; Practical decision-making

light the challenges encountered in emergency settings and emphasize the critical role of surgical expertise in making prompt decisions.

This article explores the scientific significance of managing a strangulated Amyand's hernia, emphasizing the practical challenges faced when immediate imaging is not accessible according to emergency protocols. Through the discussion of this unique observation, the study contributes to the existing scientific literature, providing valuable insights into the management of surgical emergencies. The presented case underscores the importance of a multidisciplinary approach, involving clinical acumen and surgical expertise, in addressing the complexities associated with a strangulated Amyand's hernia.

## Clinical Observation

We report the case of a 72-year-old man with a history of well-controlled hypertension on calcium channel blockers. The patient was admitted to the surgical emergency department

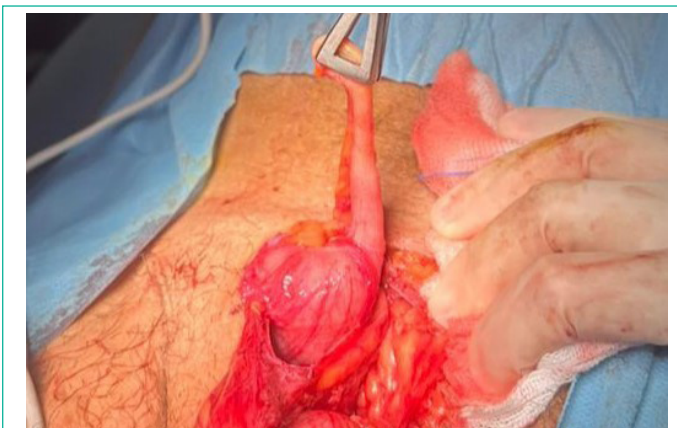

**Figure 1:** The picture during the surgery that shows repairing the Amyand's hernia.

of our hospital with suspected strangulated hernia. Given the presence of characteristic clinical symptoms such as acute groin pain for 3 days and a hernial protrusion already diagnosed as an inguinal hernia, urgent surgery was indicated as soon as anesthesia conditions allowed. The pre-operative check-up did not reveal any biological abnormalities, such as a blood ionogram, renal function, blood glucose, and an electrocardiographic trace.

In accordance with the department's protocols, no prior imaging was carried out in this case of hernia emergency. The intense pain and irreducible hernia were sufficiently suggestive clinical signs to justify immediate surgical exploration.

At the time of surgery, an Amyand's hernia was discovered, accompanied by inflamed appendicitis (Figures 1,2). No other abdominal abnormalities were identified during the preoperative work-up. Appendectomy was performed successfully, and the patient recovered without postoperative complications.



**Figure 2:** Preoperative picture showing acute inflammation of the appendix incarcerated in a right inguinal hernial sac (Amyand's hernia).

This case highlights the rarity of Amyand's hernia in an elderly patient, and the importance of prompt surgical management in hernial emergencies with obvious clinical symptoms.

### Discussion

Strangulated Amyand's hernia is a rare condition characterized by the incarceration and ischemia of the appendix within an inguinal hernia. The management and diagnosis of this condition are not well-established due to its rarity, and the literature primarily consists of case reports and small case series documenting individual experiences and approaches to treatment [6].

In emergency situations where immediate imaging modalities such as CT scans or ultrasound are unavailable or impractical, the management approach should rely on clinical assessment and surgical intervention. A thorough history and physical examination play a crucial role in evaluating the patient's symptoms and signs of inflammation, along with findings such as a tender and irreducible groin mass [7].

When imaging is not feasible, urgent surgical consultation should be sought, and the patient should be prepared for emergency surgery to relieve the incarceration and restore blood supply to the appendix. The decision to proceed with surgical exploration becomes paramount to diagnose and treat the underlying condition. During surgery, the surgeon can directly visualize the hernia sac, assess the viability of the appendix, and perform necessary interventions, such as reduction of the appendix and appendectomy if indicated [8].

The rarity of strangulated Amyand's hernia and the limited literature available emphasize the importance of the surgeon's experience and expertise. In the absence of preoperative imaging, the surgeon's clinical judgment plays a crucial role in guiding the surgical approach and decision-making process. The ability to recognize the characteristic findings and adapt the surgical technique accordingly is essential for successful management [5]. It is important to note that while imaging studies such as CT scans and ultrasound can provide valuable information in diagnosing and characterizing Amyand's hernia [9], their unavailability or impracticality in an emergency context should not delay surgical intervention when there is a high index of suspicion. The priority is to relieve the strangulation and address the ischemia to prevent further complications and improve outcomes.

### Conclusion

Strangulated Amyand's hernia represents a rare condition that necessitates prompt surgical management. In emergency situations, early surgical exploration is recommended to mitigate potential complications. This case observation serves as a reminder of the importance of practical decision-making in the management of these emergent cases and highlights the need for a multidisciplinary approach involving surgical expertise and thorough clinical evaluation."

### Author Statements

#### Ethical Approval

This case reports didn't require review by Ethics committee Ibn Sina University Hospital, Rabat, Morocco.

#### Sources of Funding

This research did not receive any specific grant from funding

agencies in the public, commercial, or not-for-profit sectors.

### Consent

Written informed consent was obtained from the patient for publication of this case report and accompanying images.

### Author Contribution

Yousra Ouhammou: contributed in study concept and design, data collection and writing paper. Khalil Abouelalaa: contributed in writing the paper.

### References

1. Doğan F, Tutak FN. Illustrations of hernia surgery in the early period of the Ottoman Empire by Şerefeddin Sabuncuoğlu. *World J Surg.* 2021; 45: 2116-20.
2. Kakodkar P, Neo WX, Khan MHT, Baig MN, Khan T. An incidental discovery of Amyand's hernia: A case study and literature review on its intraoperative management. *Cureus.* 2020; 12: e11858.
3. Ivanschuk G, Cesmebasi A, Sorenson EP, Blaak C, Loukas M, Tubbs SR. Amyand's hernia: a review. *Med Sci Monit.* 2014; 20: 140-6.
4. Psarras K, Lalountas M, Baltatzis M, Pavlidis E, Tsitlakidis A, Symeonidis N, et al. Amyand's hernia-a vermiform appendix presenting in an inguinal hernia: a case series. *J Med Case Rep.* 2011; 5: 463.
5. García-Cano E, Martínez-Gasperin J, Rosales-Pelaez C, Hernández-Zamora V, Montiel-Jarquín JÁ, Franco-Cravioto F. Hernia de Amyand y apendicitis complicada; presentación de un caso y elección de tratamiento quirúrgico Amyand's hernia and complicated appendicitis; case presentation and surgical treatment choice. *Cir Cir.* 2016; 84: 54-7.
6. Gao Y, Zhang T, Zhang M, Hu Z, Li Q, Zhang X. Amyand's hernia: a 10-year experience with 6 cases. *BMC Surg.* 2021; 21: 315.
7. Sutaria RB. Inguinal hernia. In: Kahn S, Xu R, editors. *Musculoskeletal sports and spine disorders.* Cham: Springer. 2017.
8. Birindelli A, Sartelli M, Di Saverio S, Coccolini F, Ansaloni L, van Ramshorst GH, et al. 2017 update of the WSES guidelines for emergency repair of complicated abdominal wall hernias. *World J Emerg Surg.* 2017; 12: 37.
9. Mebis W, Hoste P, Jager T. Amyand's hernia. *J Belg Soc Radiol.* 2018; 102: 8.