

Special Article – Thoracic Surgery

Aberrant Brachiocephalic Artery in Thoracic Surgery

Amore D^{1*}, Casazza D¹, Caterino U², Imitazione P² and Curcio C¹

¹Department of Thoracic Surgery, Monaldi Hospital, Italy

²Department of Respiratory Diseases, Monaldi Hospital, Italy

*Corresponding author: Dario Amore, Department of Thoracic Surgery, Monaldi Hospital, Leonardo Bianchi Street 1, 80131 Naples, Italy

Received: September 25, 2019; Accepted: October 01, 2019; Published: October 08, 2019

Clinical Image

A 70-year-old man was admitted to our operative unit for treatment of non-small cell lung cancer located in the right upper lobe. Pre-operative chest computed tomography scan showed a tortuosity of the brachiocephalic artery that crossed horizontally the right anterolateral surface of the trachea before ascending (Figure 1). The vascular anomaly was then identified intraoperatively during the lymph node dissection in the Baretty's space (Figure 2). Thoracic surgeons must be aware that an unrecognized anomalous origin of the brachiocephalic artery can lead to haemorrhagic complications during mediastinal lymph node dissection due to vascular injury.

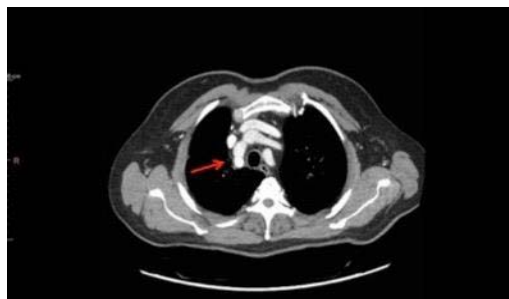

Figure 1: Chest CT showing an aberrant brachiocephalic artery (red arrow).

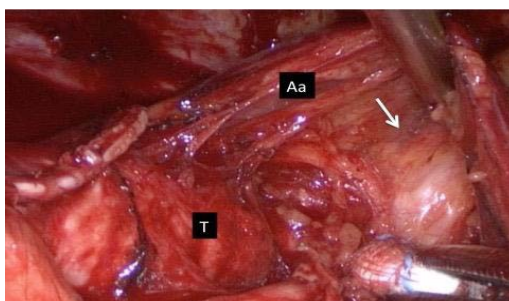


Figure 2: Intraoperative view of brachiocephalic artery (white arrow). T, trachea; Aa, arch of the azygos vein.