

Clinical Image

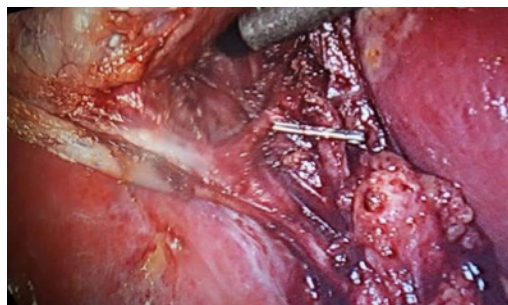
Right Posterior Hepatic Drain Drain into the Cystic Duct

Elsaady A*

Department of General Surgery, Kafr Elshikh General Hospital, Egypt

***Corresponding author:** Ahmed Elsaady, Department of General Surgery, Kafr Elshikh General Hospital, Egypt**Received:** November 28, 2019; **Accepted:** December 06, 2019; **Published:** December 13, 2019**Clinical Image**

A rare congenital anatomical variety of the biliary tree, presented in 2%. It carries the risk of its clipping during laparoscopic cholecystectomy, unless it is identified before clipping. Here the posterior hepatic duct opened into the cystic duct.

**Figure:**