Austin Journal of Surgery

Open Access

Austin Publishing Group

Special Article: Hysterectomy

Special Focus on Subtotal Laparoscopic Hysterectomy

Liselotte Mettler*; Alkatout Ibrahim
Department of Obstetrics and Gynecology, University Hospitals Schleswig-Holstein, Germany

***Corresponding author:** **Liselotte Mettler**
Department of Obstetrics and Gynecology, University Hospitals Schleswig-Holstein, Campus Kiel, Arnold-Heller-Str. 3/24, 24105 Kiel/ Germany.
Email: profmettler@gmx.de

Received: March 30, 2023
Accepted: April 18, 2023
Published: April 25, 2023

Abstract

Today 80 percent of hysterectomies in patients with benigne and malignant disease are done by endoscopic procedures. Clear indications for Laparoscopic Subtotal Hysterectomy include a cervix free of any disturbances, a multifibroid uterus and the wish of the patient to reserve the normal function of her pelvic organs. Laparoscopically this procedure can be easily performed without any side effects. Recently in China Li, Zi-Jun et al. [25] 2020 described a new technique called Anterograde Vaginal Subtotal Hysterectomy (AVSH) which appears to be much more complicated than our Kiel based LSH initiated by Kurt Semm in 1991 [13]. It is the aim of this chapter to line out the easiness and beauty of Laparoscopic Subtotal Hysterectomy (LSH). This is not intended to be a research paper but a historical development presentation for LSH.

Keywords: Laparoscopic Subtotal Hysterectomy (LSH) or Laparoscopic supracervical hysterectomy; Anterograde Vaginal Subtotal Hysterectomy (AVSH)

Introduction

Subtotal hysterectomy, first performed by Freund [1] was the leading technique of hysterectomy for over 80 years until Tervilä [2] described the danger of cervical cancer as 0.3 to 1.9% following supracervical hysterectomy. From 1950 onward, hysterectomy was performed almost exclusively as total hysterectomy until Semm [3] revived interest in supracervical hysterectomy in the 1990s by introducing the Classic Intrafascial Supracervical Hysterectomy (CISH technique) to be performed by laparoscopy and laparotomy [3-10] with coring of the inner cervix. Other major contributions to this technique soon followed [11,12].

Materials and Methods

Classic Intrafascial Supracervical Hysterectomy (CISH)

The CISH technique, as one method of supracervical or subtotal hysterectomy, was performed in Kiel from 1989 until 2005 and was then replaced by the Laparoscopic Subtotal Hysterectomy (LSH) technique.

In the years 1988 -1989, when there was still a lot of opposition from traditional gynecological surgeons against the Minimal Invasive Surgery (MIS). For Hysterectom CISH was developed to exclude the possible development of a cervical stump malignancy in the cervical functional tissue. The transformation zone was resected by transvaginal cylindrical coring of the cervical tissue using a 15, 20, or 24mm Calibrated Uterine Resection Tool (CURT). This coring involved transvaginal excision of the functional cervical tissue from the muscular and connective tissue components of the uterine cervix. To ensure the safety of this excision without endangering ureters or the uterine artery, it was necessary to manipulate the uterus which normally lies in ante- or retroflected position into a straight position. This was done by introducing a 5 mm perforation rod into the external cervical os and pushing it through the internal os into the cavity and finally perforating the uterus in the middle of the fundus. Even in cases of large uterine fibroids, it was possible to find the uterine cavity. The device for coring out of a tissue cylinder is demonstrated in Figure 1. Once a straight line has been established between the cervical canal and the uterine fundus, a preselected CURT was applied over the perforation rod to cut out the appropriate cylinder leaving the cervical outer shell intact. Four steps characterize the technique, two from the vaginal side and two transabdominally. We describe these steps as a historical development only but proceed with the LASH technique which is internationally called LSH (laparoscopic subtotal hysterectomy) today.

Mettler Liselotte © All rights reserved

Citation: Liselotte M, Ibrahim A, Mettler L. Special Focus on Subtotal Laparoscopic Hysterectomy. Austin J Surg. 2023; 10(1): 1298.

Figure 1: The CURT along the previously placed axial guide as first and second vaginal steps of CISH.

For both technologies of subtotal hysterectomy by laparoscopy a careful, preoperative exclusion assessment of cervical pathology like endometriosis or malignancies of the uterine cervix and corpus are necessary. This preoperative evaluation includes:

1. Endometrial evaluation by bleeding pattern, imaging and may be dilation and curettage.

2. Pap smear may be colposcopy or dilation and curettage. If there has been any previous cervical pathology or conization etc a LSH is not indicated.

3. In any case of endometriosis with vaginal, cervical or rectocervical nodules the cervix should not be retained in hysterectomy indications.

First Vaginal Step

Preoperatively, the vagina is disinfected; the cervix is grasped at 3 and 9 o'clock by two tenacula. Following this, the uterus length is measured, the cervical canal is dilated up to Hegar 5, and the 50cm long perforation rod is introduced into the uterus according to the uterine length. The perforation rod is part of the CURT set and is fixed vaginally together with two tenacula using a specifically designed clamp and screw. With large uterine fibroids, this can be difficult and is sometimes more easily performed following transaction of the supracervical uterus. The correct diameter of the CURT is selected based on the ultrasound measurement of the cervix and upon inspection. The proper selection of CURT is important because if the cylinder is too wide, it would cut outside the cervical fascia. A cylinder that is too narrow would not remove all of the functional cervical tissue. The center of fixation of the uterus allows for a three-dimensional maximal mobilization of the uterus transvaginally. During this procedure the uterus is continually observed on the video screen

First Laparoscopic Step

After having established a clear endoscopic view into the pelvis with no bowels adherent to the structures of the uterus, the perforation of the uterine fundus is performed under vision. The uterus can now be anteverted, retroverted, and lateralized.

The adnexa are separated from the pelvic side wall using ligatures, sutures, staplers, ligasure, ultrasound, or whatever hemostatic technique is available. Separation of the adnexa usually causes a minimal blood loss. The round ligament is also coagulated and divided. This dissection of the adnexa and round ligament leads to an opening of the vesicovaginal fold and to an opening of the posterior leaf of the broad ligament.

The first laparoscopic part of CISH consists of the following steps:

- Separation of adnexa and round ligament from pelvic side wall or uterus
- Dissection of the vesicouterine peritoneum, opening of the paravesical space
- Placement of one cervical loop

After having exposed the cervix, a Roeder polydioxa- none (PDS) loop is loosely placed around the cervix ready to be locked after the CURT cylinder is resected to prevent gas leakage.

Second Vaginal Step

The fixing screw holding the axial guide rod of the CURT is removed. The cutting tube around the central cylinder is placed as a unit over the axial guide rod and the chosen cylinder is cored out electrically under endoscopic vision. The tenacula placed at 3 and 9 o'clock are gently pulled and the motor drive is slowly advanced. An equal pressure is applied to the cutting tube as it is rotated and advanced from the cervix through the endometrium to the fundus. As the cutting tube advances, the calibrated scale along the central cylinder slowly reveals the depth of tissue already cut (Figure 2).

The cutting tube is rotated and slowly cores out a cylinder through the fundal serosa. It is important to ensure that each last thread of tissue has been cut; otherwise, the tissue cylinder cannot be removed transvaginally.

After the tissue cylinder has been completely cored out, it is carefully withdrawn and extracted through the vagina under transabdominal laparoscopic control. The endocervical wound is coagulated up to a maximum of 2.5cm into the resection canal. After the CURT cylinder has been resected, there is very little bleeding; however, as a prophylaxis against later bleeding the inner part of the remaining cervical cylinder has to be coagulated, preferably with an endocoagulator at 120°C or with bipolar coagulation forceps. Figures 3 and 4 demonstrate the preparatory and two transvaginal surgical steps.

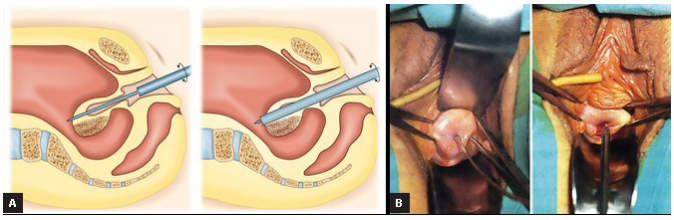

Figures 2A and B: First vaginal step of CISH. **(A)** Positioning of CURT. **(B)** Anatomical situation with grasping the cervix at 3 and 9 o'clock and measuring the length of the cervix, introduction of the axial guide of CURT.

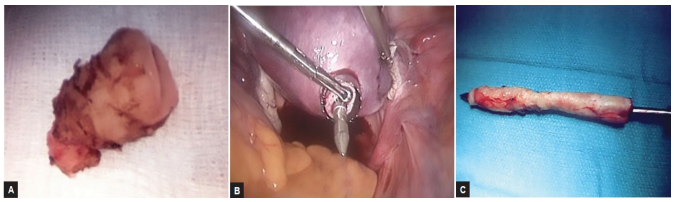

Figures 3A to C: (A) Resected specimen at additional conization (which was rarely indicated). **(B)** Anatomical situation of coring of the inner cervix. **(C)** Cored-out specimen for pathohistological examination

Second Laparoscopic Step

With a 10mm claw forceps, the uterus is grasped and pulled in the direction of the umbilicus. The prepositioned Roeder loop is placed as deep as possible and closed similar to a tourniquet around the cervix (Figures 5 and 6).

This technique was already recommended by Rubin in 1951 as a temporary ligature around the ascending branches of the uterine artery for myoma enucleations.

The double cervical ligature: A subsequent ligature is placed over the cervix to closely tie the ascending branches of the uterine artery and its collaterals. If the ligature is not set tightly enough, it is possible that after resecting the uterus, the fascial tissue could invaginate and loosen the ligatures securing the uterine arteries.

Resecting the uterus: When the pericervical fascial tissue has been ligated using the double-loop ligation technique, the uterus is re-grasped with the forceps and pulled in the direction of the umbilicus. It may then be resected with a monopolar loop above the ligatures, with hook scissors, a laser, or a monopolar current hook. The remaining stump should be at least 2 to 3cm.

Sterilization of the intraabdominal cervical stump: Disinfection is performed with iodine and the bipolar forceps are applied to coagulate the surface of the stump.

Peritonealization: When the cervical stump clearly shows the ascending branches of the uterine artery, these may be coagulated and the tourniquet released. The two remaining PDS threads are not a hindrance. The stump may be covered by placing the vesicouterine peritoneum over the tissue pedicles (Figure 7).

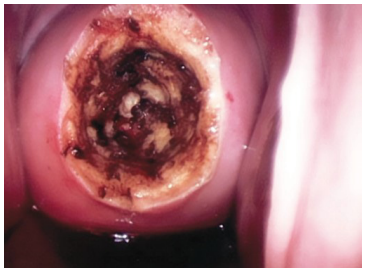

Figure 4: Coagulation of cored-out cervix.

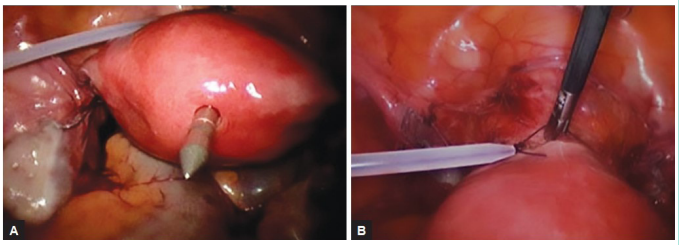

Figures 5A and B: Ligation of uterine cervix with two PDS Roeder loops.

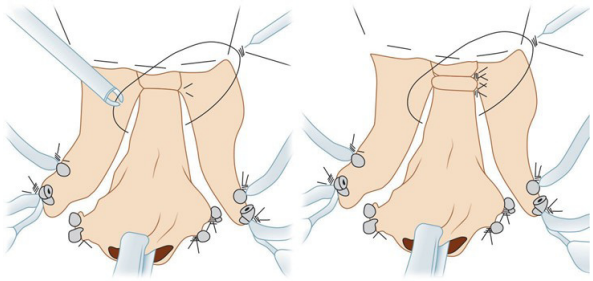

Figure 6: Schematic illustration of loop placement at CISH.

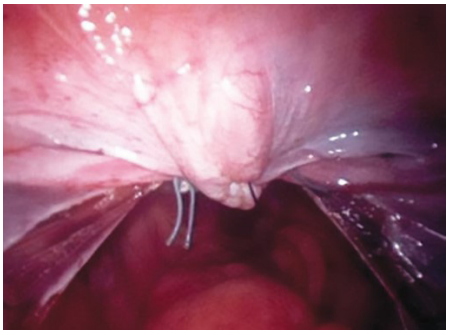

Figure 7: Peritonealization after CISH.

The pelvis is then irrigated with 1 to 2L of Ringer's lactate and a careful supervision of the whole abdomen is carried out.

Morcellation of the uterus: The large claw forceps grasps the uterus which is then morcellated from the left lateral incision point through the morcellator. We usually dilate up to the required morcellator size. The Storz Rotocut is ideal for this purpose. For further hemostasis and adhesion prevention, the remaining cervical stump is coagulated with the bipolar forceps.

The second laparoscopic part of CISH consists of the following steps:

- Closing of two ligatures around the cervix
- Separation of cervix from uterus
- Coagulation of cervical stump
- Morcellation
- Peritonealization of stump

Histopathology of CISH specimens: A normal non- elongated cervix measures 2.5 to 3cm in length. It is separated into an ectocervix and an endocervix. The ectocervix is covered with stratified squamous epithe lium. The epithelium changes from ecto to endocervix, from a squamous epithelium to columnar epithelium. The epithelium is quite granular and in the area of the endo-cervix the so-called endocervical glands may be found.

The cervical sections are analyzed as to whether a hyperplastic cervical mucosa is present and for remaining glandular components. The distal cervical segment, as it progresses to the isthmus, is analyzed in cross sections. This is performed to demonstrate the outer circumference of the cervix and to allow the pathologist to check for possible mesonephric duct remnants. The uterine cavity segment is also sectioned in a longitudinal manner. The procedure allows for an absolutely correct and accurate histopathological assessment of all the uterine tissue.

The individual steps of the laparoscopic CISH technique are summarized in Figures 3 to 6.

Laparoscopic Supracervical Hysterectomy

Since 1995 at the Department of Obstetrics and Gynaecology in Kiel we only use the laparoscopic supracervical or subtotal hysterectomy as described in the following paragraph. We had found out that the meticulous bipolar coagulation of the inner cervical stump results in the same success than the entire coring suggested with the CISH procedure. It took a long time to convince Kurt Semm, but he certainly had his reasons, as our Medical Surgical profession in 1990-1995 often attacked him of not respecting medical principals.

Prerequisites for LSH are the absence of premalignant and malignant alterations within the cervix and the uterine body and indications are bleeding abnormalities, pain, uterine fibroids, and adenomyosis. The LSH operation is technically simple, carries less risks than vaginal or abdominal hysterectomy, and the essential pelvic floor support connective tissue structures remain unchanged. The retention of sexual feeling and less risk of later descensus of pelvic floor and genital organs or urinary incontinence, compared with total hysterectomy, are important factors in patients' decision for this procedure.

Only a few reusable instruments are used for the LSH procedure. In addition to the optic trocar and two to three 5mm trocars. Standard instruments include the bipolar coagulation clamp, scissors, grasping forceps, a needle holder, a unipolar hook, and a suction irrigation system or other devices for hemostasis (Figure 8).

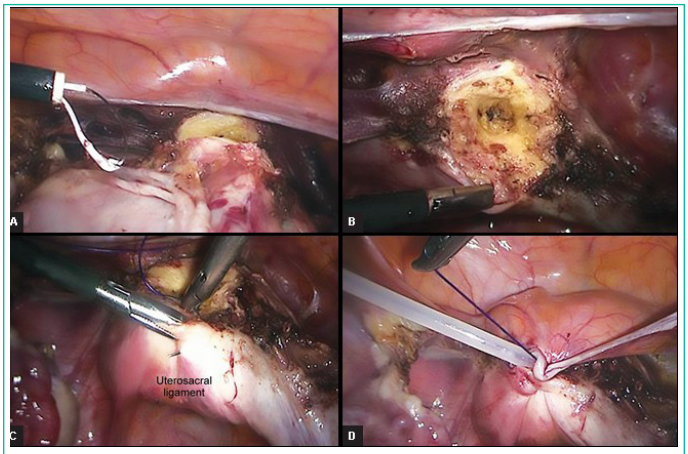

Figures 8A to D: **(A)** LSH procedure with dissection of uterine body from vagina using the STORZ loop (endoscopic monopolar loop for sectioning of uterus) ligation technique in three steps. **(B)** Loop placed around the cervix. **(C)** Cervical stump after separation from the uterine body followed by intracervical bipolar coagulation and **(D)** Peritonealization.

To mobilize the uterus, the round ligaments, the fallopian tubes, and the ovarian ligaments are coagulated with bipolar forceps and subsequently dissected with endoscopic scissors. At each procedure the uterus is pulled to the contralateral side, and the ovaries and fallopian tubes are separated from the pelvic side wall or the uterus. The bladder peritoneum is delineated and the bladder pushed downward. Once the uterine vessels have been identified, they are coagulated with bipolar forceps and dissected. Hemostasis can be performed with plasma fusion, ligasure, or ultracision. The bladder peritoneum is again mobilized and pushed down cranially to where the sacrouterine ligaments leave the cervix. For the resection of the uterine body from the cervix, a monopolar hook is used. Starting from the left, the uterus is held against the anterior abdominal wall with grasping forceps and pulled toward the postcranial side. From the right, the dissection is carried out step-by-step with the unipolar hook. After appropriate hemostasis in the area of the cervical stump, bipolar coagulation of the cervical canal is performed. The uterus itself is morcellated. The peritoneum can be left open; however, it can also be closed over the cervical stump. Since the introduction of the cutting loops by Karl Storz, LINA, and other companies, the cervix is easily separated from the uterine body by these monopolar loops.

To be able to remove the uterus, we first widen the incision and bring in one of the conventional morcellators (STORZ® or others). At the end of the operation, lavage is performed and the cervical stump is checked. Within the last 10 years more than 1000 LSH procedures have been performed at the Kiel University Department of Obstetrics and Gynecology without any complications. Cervical endometriosis and rectovaginal endometriosis do not represent indications for LSH (14-24).

Uterine Morcellation

We are well aware of all the issues concerning uterine morcellation for tissue extraction and understand the present ban on morcellation within the USA.

According to our own evaluation estimating the frequency of unsuspected uterine sarcoma identified postoperatively in women undergoing surgery for presumed benign uterine fibroids by myoma enucleation or LSH, at the single –center university hospital in Kiel. we retrospectively examined the records of all 2,275 patients with uterine fibroids and uterine sarcomas from 2003 to 2015 [13].

Descriptive statistics were used to analyze demographic and clinical characteristics. To calculate Confidence Intervals (CIs), the exact Clopper-Pearson method was applied. Preoperatively, 2,269 patients had presumed benign uterine fibroids, and six patients had suspected uterine sarcoma. Among the 2,269 patients who underwent surgery with morcellation for presumed uterine fibroids, only one patient (0.044%, 95% CI: 0.001%-0. 25%) histopathologically revealed Endometrial Stromal Sarcoma (ESS) detected in the pathohistogical examination after Laparoscopic Subtotal Hysterectomy (LSH) with morcellation**,** she was 49 years old all six preoperatively diagnosed patients with uterine sarcoma underwent a direct conventional cancer treatment. Histopathological analyses confirmed four cases of Uterine Leiomyosarcoma (ULMS), one High-Grade Undifferentiated uterine Sarcoma (HGUS), and one Embryonal Rhabdomyosarcoma (ERMS). Altogether, seven women were diagnosed with uterine sarcomas over this twelve-year period we concluded that he frequency of unsuspected uterine sarcomas was 1/2,269 (0.044%) among women who underwent myomectomies and hysterectomies to treat presumed benign uterine fibroids in our institution and continue to do in bag morcellation for all our patients with LSH, carefully trying to exclude in morcellation in the following situations:

1. Fast growing uterine mass within the last months.

2. Unclear capsule and structure in 2- and 3- dimensional ultrasound and MRI. There should be clear myoma margins and homogeneous tissue

3. Increased serum LDH levels above 140- 280 IU/L.

4. Age over 45 years, as the incidence of sarcomas increase with age.

5. If consent, for the small remaining risk of sarcoma, is not given for morcellation

Taking these landmarks allowing in bag morcellation, into consideration, few cases with the primary decision for LSH remain to have tissue extraction done in the bag after widening the left lower abdominal trocar incision for an extraction without morcellation or extracorporal morcellation.

In our estimation a possible malignancy spread in myomectomies and subtotal hysterectomies may already occur at myoma enucleation or resection of the uterine body from the cervix and not only at morcellation.

Results and Discussion

Experience with LSH now dates back to 1990. LSH was first performed by CISH and after 1995 by LSH as it is today. It is easy to perform, can be carried out on smaller and larger uteri, and leaves the pelvic floor intact. It has a short rehabilitation time and high patient acceptance. It is very cost-effective and has a low complication rate [14-18]. The CISH technique historically was the first subotal laparoscopic hysterectomy procedure that was initially technically challenging but had a quick learning curve. It can be easily performed by two surgeons with three hands for the surgery and one hand to hold the camera. Every evaluation postulates that patients undergoing laparoscopic supracervical hysterectomy compared with total hysterectomy have shorter operation times, shorter hospital stays, and less morbidity than those who underwent laparoscopic-assisted vaginal hysterectomy or total laparoscopic hysterectomy [18]. The practice of routine cervixectomy at laparoscopic hysterectomy may be reconsidered. Okara et al [17] published data related to the cervical stump requiring further surgery following a laparoscopic supracervical hysterectomy. These data, however, could not be verified in our own retrospective evaluation [14,19] nor in data published by colleagues using the LSH technique [20,21]. The LSH technique is an easier surgical method than CISH and fulfils the same purpose. Thus, CISH can be considered a simple subtotal hysterectomy and now is only historically relevant. It has all the advantages of a subtotal hysterectomy and additionally includes the coring of the inner cervix [17,18]. This prevents the occurrence of cervical stump cancer which after CISH only appears in 1 of 5 million cases. The same rare incidence was found recently in LSH [27].

Surgical complications and clinical outcome proved to be acceptable even in large uteri [23,24]. In cases of large uteri, the procedure is possible via laparoscopy. Uterus and fibroids are dissected and morcellated in situ.

In a random evaluation of 253 nonselective cases, the entire excoriated tissue cylinder specimens obtained at hysterectomy in our department were histologically reexamined. In all cases, the transitional zone from the ectocervix to the endocervix (from squamous to columnar epithelium) was completely removed. In only six cases could endocervical glands be found at the cutting margins (2.3% = 0.02% coincidence). If cervical carcinoma were to develop in all of these cases, the incidence rate of cervical carcinoma post CISH would be 0.02 cases per 100,000, which is a frequency of 1:5,000,000.

A laparoscopic CISH or at present LSH procedure is possible even in cases of uterine fibroids, larger than the 24th gestational week in size.

Taking into account the remaining cervical concept, a laparotomic subtotal hysterectomy is an alternative procedure for larger fibroids. At LSH in comparison to CISH the coring of the inner cervix is replaced by bipolar coagulation of the cervical canal via laparoscopy. Laparoscopic subtotal hysterectomy is an ongoing technique in patients that can be checked regularly by their gynecologist. We do not advise it for patients who do not come back for annual gynecological controls.

The surgical benefits are:

- Secure transvaginal coring out of the cervical mucosa including the glandular component or coagulation
- Preservation of the cardinal ligament
- Preservation of the pericervical network of nerves
- Protection of the ureters, uterine artery, bladder and rectum, etc.
- No colpotomy
- The vagina is not shortened
- No danger of abdominal infection through contamination from vaginal bacteria
- Elimination of the method associated secondary healing of the vaginal cuff
- Minimal traumatization and little blood loss

Elective suspension of the ligaments on the cervical fascial stump as opposed to the vaginal cuff The medical benefits are:

- Prophylaxis against cervical stump carcinoma
- Complete preservation of the pelvic floor anatomy through preservation of the support function of the cardinal ligament
- Reduced physical stress for the patient
- Reduction in the time for reconvalescence
- Complete preservation of sexual function with regard to subjective vaginal and cervical components
- Complete preservation of the functionability of the vagina as regards partner contact
- Earlier return to sexual activity
- No change in the perception of sexual contact by the partner
- Better quality of life through LSH despite hysterectomy

The standardized LSH minimally invasive surgical technique is simple to learn and can be performed with a few simple endoscopic surgical instruments. The special significance of the LSH procedure is that it can be performed on nulliparous patients, patients who have not previously had a vaginal delivery, and patients who have had previous surgery. The LSH provides a minimally invasive alternative to all other methods of total hysterectomy in benign conditions and has a low perioperative morbidity rate.

The LSH remains to be an effective alternative to laparoscopic total hysterectomy with the necessity of regular gynecological checks of our patients.

Compared to the AVSH technique [26] which is part of the originally Viennese vaginal hysterectomy technique, LSH has multiple advantages out of which the clear open laparoscopic vision at the dissection speaks for itself [25-29].

References

1. Freund WA. Bemerkungen zu meiner Methode der Utuerusextirpation. Zbl Gynäkol. 1878; 2: 497-500.
2. Tervilä I. Carcinoma of the cervical stump. Acta Obstet Gynecol Scand. 1963; 42: 200-10.
3. Semm K. Hysterektomie per laparotomiam oder per pelviscopiam. Geburtsh Frauenheilk. 1991; 51: 996-1003.
4. Semm K. Morzellieren und Nähen per pelviskopiam—kein prob-

lem mehr. Geburtsh Frauenheilk. 1991; 51: 843-846.

5. Mettler L, Semm K, Shah A, Shah P. Intrafascial supracervical hysterectomy without colpotomy and transuterine mucosal resection by pelviscopy and laparotomy—our first 200 cases. Curr Invest Gynecol Obstet. 1993; 9: 359-362.

6. Mettler L, Semm K, Lüttges J, Panadicar D. Pelviskopische intrafasciale Hysterectomie ohne Kolpotomie (CISH). Gynäkol Prax. 1993; 17: 509-526.

7. Semm K. Prophylaxe der Sterilität durch minimal invasive Chirurgie. Der Frauenarzt. 1994; 35: 944-954.

8. Mettler L, Alvarez-Rodas E, Lehmann-Willenbrock E, Lüttges J, Semm K. Intrafascial supracervical hysterectomy without colpotomy and transuterine mucosal resection by pelviscopy and laparotomy. Diagn Therap Endosco. 1995; 1: 201-207.

9. Mettler L, Semm K, Lehmann Willenbrock E, Shah A, Shah P, et al. Comparative evaluation of classical intrafascial supracervical hysterectomy (CISH) with transuterine mucosal resection as performed by pelviscopy and laparotomy—our first 200 cases. Surg Endosc. 1995; 9: 418-423.

10. Alkatout I, Mettler L, editors. Hysterecotomy: a comprehen- sive surgical approach. 1st ed. Switzerland: Springer International Publishing. 2018; 33: 1639.

11. Donnez J, Nisolle M. Laparoscopic supracervical (subtotal) hysterectomy (LSH). J Gynecol Surg. 1993; 9: 91-94.

12. Lyons TL. Laparoscopic supracervical hysterectomy. A comparison of morbidity and mortality results with laparo- scopically assisted vaginal hysterectomy. J Reprod Med. 1993; 38: 763-767

13. Liselotte Mettler, Nicolai Maass, Khulkar Abdusattarova, Astrid Dempfle, Ibrahim Alkatout. Frequency of uterine sarcomas in patients admitted for uterine fibroid surgery. J Turk Ger Gynecol Assoc. 2017; 18: 62-66.

14. Mettler L, Semm K. Subtotal versus total laparoscopic hysterectomy. Acta Obstet Gynecol Scand Suppl. 1997;164: 88-93

15. Kim DH, Bae DH, Hur M, Kim SH. Comparison of classic intrafascial supracervical hysterectomy with total laparoscopic and laparoscopic-assisted vaginal hysterectomy. J Am Assoc Gynecol Laparosc. 1998; 5: 253-260.

16. Lyons TL. Laparoscopic supracervical hysterectomy. Obstet Gynecol Clin North Am. 2000; 27: 441-450.

17. Okaro EO, Jones KD, Sutton C. Long term outcome follow- ing laparoscopic supracervical hysterectomy. BJOG. 2001; 108: 1017-1020.

18. Morrison JE Jr, Jacobs VR. 437 classic intrafascial supracervical hysterectomies in 8 years. J Am Assoc Gynecol Laparosc. 2001; 8: 558-567.

19. Milad MP, Morrison K, Sokol A, Miller D, Kirkpatrick L. A comparison of laparoscopic supracervical hysterectomy vs laparoscopically assisted vaginal hysterectomy. Surg Endosc. 2001; 15: 286-288.

20. Alkatout I, L Mettler. practical Manual for Laparoscopic and Hysteroscopic Gynecological Surgery, Third edition, New Delhi: Jaypee Brothers Medical Publishers (P) Ltd; 2020.

21. Salfelder A, Lueken RP, Bormann C, Gallinat A, Moeller CP, et al. Die suprazervikale Hysterektomie in neuem Licht. Wiederentdeckung als minimalinvasive Methode. Frauenarzt. 2003; 44: 1071-1075.

22. Bojahr B, Raatz D, Schonleber G, Abri C, Ohlinger R. Perioperative complication rate in 1706 patients after a standardized laparoscopic supracervical hysterectomy technique. J Minim Invasive Gynecol. 2006; 13: 183-189.

23. Lyons TL, Adolph AJ, Winer WK. Laparoscopic supracervical hysterectomy for the large uterus. J Am Assoc Gynecol Laparosc. 2004; 11: 170-174.

24. Learman LA, Summitt RL Jr, Varner RE, McNeeley SG, Goodman-Gruen D, et al. A randomized comparison of total or supracervical hysterectomy: surgical complications and clini- cal outcome. Obstet Gynecol. 2003; 102: 453-462.

25. Mettler L, Alkatout I, Keckstein J, Meinhold-Heerlein I, editors. Endometriosis: a concise practical guide to current diagnosis and treatment. 1st ed. Tuttlingen: Endo Press GmbH; 2017.

26. Li ZJ, Jia ZX, Zheng YQ. A New technique for supracervical hysterectomy: anterograde vaginal subtotal hysterectomy. Medicine. 2020; 99: e20006.

27. Bojahr, Bernd Tchartchian, Garri. Laparoscopic Subtotal Hysterectomy (LSH). Hysterectomy: A Comprehensive Surgical Approach. 2018; 467-480.

28. Alkatout I, Mettler L. Hysterectomy – A comprehensive Surgical Approach. Springer International Publishing Switzerland. 2018; 1: 1-103.

29. Alkatout I, Mettler L. Hysterectomy – A comprehensive Surgical Approach. Springer International Publishing Switzerland. 2018; 2: 1034-1639.