

Case Report

Steatocystoma Multiplex of Scrotum

Kumar R, Krishnamoorthy S* and Rajamanickam MG

Department of Urology and Renal Transplantation, University of Sri Ramachandra Medical Centre, Chennai, India

*Corresponding author: Sriram Krishnamoorthy, Department of Urology and Renal Transplantation, University of Sri Ramachandra Medical Center, Chennai, India

Received: July 28, 2015; Accepted: November 12, 2015; Published: November 27, 2015

Abstract

Steatocystoma Multiplex (SM) is a hamartomatous malformation of the pilosebaceous duct. It is a rare disorder of the pilosebaceous unit, characterized by the development of numerous sebum-containing dermal cysts [1]. Here, we report a 22-year-old male presented with multiple asymptomatic, yellow to skin-colored firm cystic swellings over the scrotum; the lesion had been present for about 3 years. Histological findings are consistent with the diagnosis of steatocystoma multiplex. This case represents an unusual clinical manifestation of steatocystoma multiplex in scrotum and is presented for its rarity.

Keywords: Steatocystoma multiplex; Scrotum; Sebaceous cyst

Introduction

First described by Jamieson in 1873, and coined by Pringle in 1899, Steatocystoma Multiplex (SM) is an uncommon disorder of the pilosebaceous unit characterized by the development of numerous sebum-containing dermal cysts [1]. Historically, this condition may be hereditary (as an autosomal dominant trait) or more commonly sporadic. It usually begins in adolescence or during early adult life [1,2]. Clinically, it is characterized by multiple, small, soft, movable, yellowish-to-skin-colored dermal cystic papules and nodule and the overlying epidermis is usually normal with no central punctum.

In typical cases of SM, cysts are distributed in areas where high numbers of sebaceous glands are found, most commonly the chest, arms, axillae and neck. Several reports of localized SM limited to the scalp, face, retro-auricular region, groin and nasal region have been reported [1-3]. Herein, we report a case of SM localized to the scrotum. The appearance of multiple cystic lesions involving the scrotum, especially in unmarried men, is highly embarrassing.

Case Report

A 22-year old unmarried male presented with multiple cystic firm lesions over scrotum. These lesions had gradually grown larger and increased in number over a period of three years. On physical

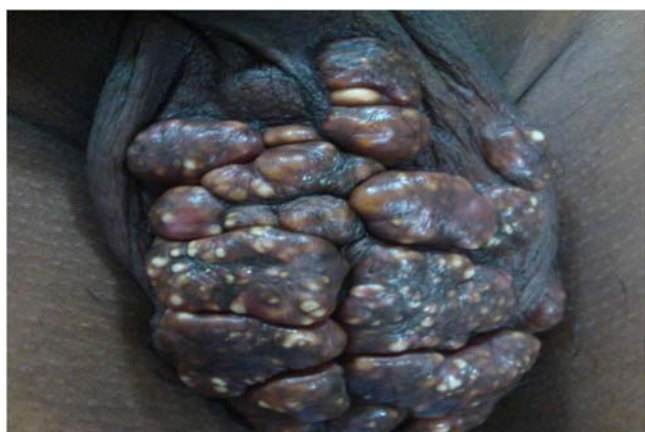

Figure 1: Multiple yellow to skin colored cystic lesions over the scrotum.

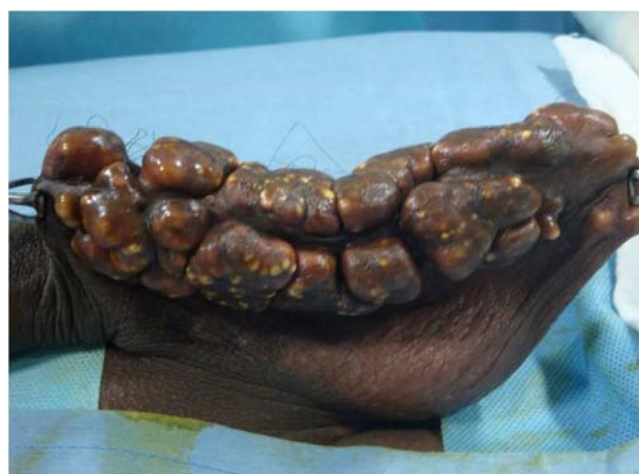

Figure 2: Cystic lesions over the Scrotum.

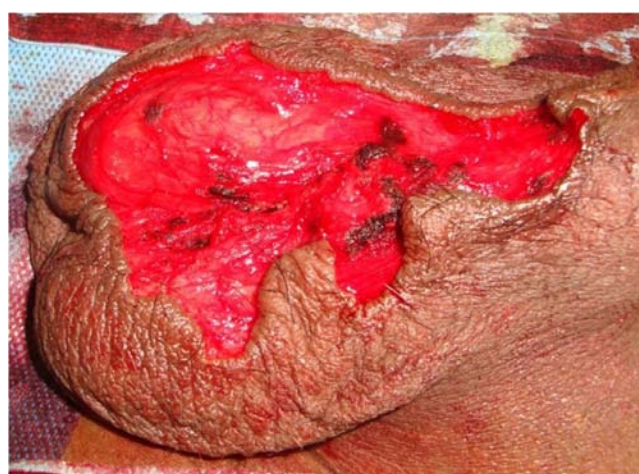

Figure 3: Excision of the scrotal lesion done.

examination, asymptomatic multiple smooth yellow and skin-colored cystic nodules were palpable on the whole scrotum, there were no central punctum; however, no lesions were detected in other locations, including the trunk, extremities, and face. The diameters

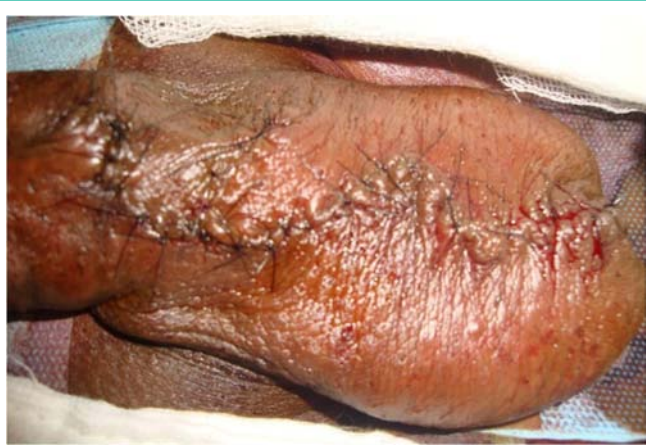

Figure 4: Primary closure after excision of lesion.

of the lesions ranged from 1cm to 3 cms (Figure 1,2). There were no signs of inflammation in any of the lesions. The patient's past and family histories were non-contributory. The results of laboratory blood tests did not show any evidence of infection or inflammation. Patient underwent excision of lesions en-mass (Figure 3) under spinal anaesthesia and primary closure was done (Figure 4) and specimen sent for histopathology. Subsequent histopathological examination revealed cysts within the lower dermis and subcutaneous fat. The folded cystic wall was lined with stratified squamous epithelium and contained flattened sebaceous gland cells (Figure 5).

Discussion

Steatocystoma multiplex is an uncommon disorder that is characterized by multiple small, cystic nodules. The overlying epidermis is usually normal with no central punctum present. The lesions are typically located on the upper trunk, neck, axillae, scrotum, and proximal extremities [2-4]. Although there are reports of involvement of various sites, such as scalp, forehead, chest, trunk, groin, axilla, scrotum, and so forth, an increase in size and number with extensive calcification and adhesion tightly to the scrotum for many years are unlikely and an asymptomatic presentation.

The colour of the lesions varies from yellowish to skin colour and this variation has been attributed to the depth of the lesions- the superficial lesions being yellowish and the deeper lesions skin coloured [3]. In our case, the lesions exhibited both the colors.

The causative factors of steatocystoma multiplex still remain unclear. The pathogenesis of these lesions has been extensively studied. Steatocystomas were initially thought to be sebaceous or retention cysts [3,4]. As far as the pathogenesis of this condition is concerned, it was postulated that pluripotential ectodermal cells retain the embryonic capacity to form appendages or nevus rather than retention or inclusion cyst [5,6]. Steatocystomas are now recognized

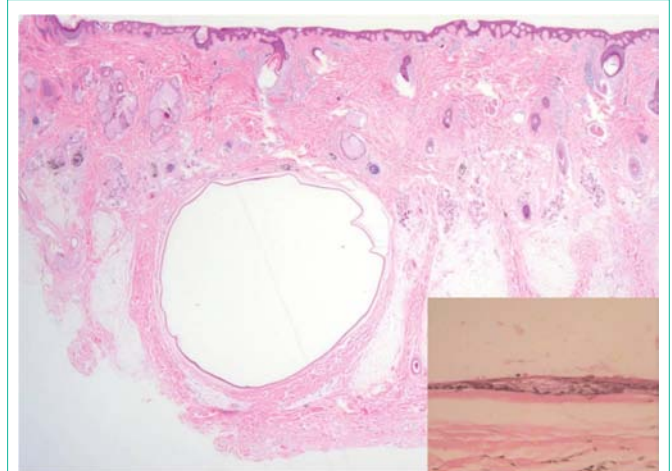


Figure 5: Cysts within the lower dermis and subcutaneous fat. Inset- folded cystic wall was lined with stratified squamous epithelium and contained flattened sebaceous gland cells.

as a nevoid or hamartomatous malformation of the pilosebaceous junction [3]. Steatocystoma described a similar case, where the SM had large granular lining cells had immunohistochemical characteristics of the macrophage/monocyte lineage [7].

The definite treatment of individual lesions is excision. However, the sheer number of cysts and calcification usually precludes this type of treatment. In such instances, incision and complete expression of cysts contents or aspiration may be effective temporally in reducing the lesion [2]. Laser incision of the cyst may also be effective. Intra-lesional steroid, cryotherapy, and oral retinoids can be beneficial in early lesions [3].

References

1. Lee D, Chun JS, Hong SK, Seo JK, Choi JH, Koh JK, et al. Steatocystoma multiplex confined to the scalp with concurrent alopecia. *Ann Dermatol.* 2011; 23: 258-260.
2. Choudhary S, Koley S, Salodkar A. A modified surgical technique for steatocystoma multiplex. *J Cutanaesthet Surg.* 2010; 3: 25-28.
3. Laquer VT, Wu JJ, Tournas JA, Murase JE, Dyson SW. Pruritic bluish-black subcutaneous papules on the chest. *Dermatology Online Journal.* 2008; 14: 14-17.
4. Chu DH. Steatocystoma multiplex. *Dermatology Online Journal.* 2003; 9: 18.
5. Mortazavi H, Taheri A, Mansoori P, Kani ZA. Localized forms of steatocystoma multiplex: Case report and review of the literature. *Dermatology Online Journal.* 2005; 11: 22.
6. OhSW, KimMY, LeeJS, KimSC. Keratin 17 mutation in pachyonychia congenita type 2 patient with early onset steatocystoma multiplex and Hutchinson-like tooth deformity. *J Dermatol.* 2006; 33: 161-164.
7. Setoyama M, Mizoguchi S, Usuki K, Kanzaki T. "Steatocystomamultiplex: a case with unusual clinical and histological manifestation". *American Journal of Dermatopathology.* 1997; 19: 89-92.