

Short Communication

Warming Acupuncture Therapy for Idiopathic Facial Paralysis in a Dog

Xin-Huai SHI, Feng-Jun LIU*, Qiu Y, Zhao H, Yi-Heng LI and Yu-Ling Zjang

College of Animal Science and Technology, Henan University of Science and Technology, Luoyang, China

*Corresponding author: Feng-Jun LIU, College of Animal Science and Technology, Henan University of Science and Technology, Luoyang, China

Received: April 04, 2018; Accepted: April 23, 2018;

Published: April 30, 2018

Abstract

The combination of acupuncture and moxibustion was used for treating canine idiopathic facial palsy (IFP) to explore the therapeutic method of this disease. Local acupuncture points (ST4, ST5, ST7, GB3 and TH17) in the affected side were treated by needle warming through moxibustion, were retained needle for 30 minutes. The dog was treated 15 times of acupuncture and moxibustion in total. IFP was cured during 20 days. This result indicated that this method is effective for the treatment of IFP in this dog. Although this method has been used to cure the dog, the reliability of this method needs to be verified in more cases.

Keywords: Canine; Idiopathic facial palsy; Acupuncture; Moxibustion; Treatment

Short Communication

Idiopathic facial paralysis (IFP) is an acute disorder of the facial nerve that begins with symptoms of full or partial paralysis on one side of the face [1], and might persist for months or years. This disease has been reported in several domestic species and man [2-6]. Up to data, its cause is not very clearly known and prognosis is difficult. Some study has reported it may be related to latent herpes simplex virus type I, infection, trauma, neoplasia, otitis media, otitis interna, hypothyroidism, diabetes mellitus [7-10]. Traditional Chinese Medicine (TCM), names IFP as 'deviated mouth', attributes it to 'wind' by past dynasties. Deficiency of 'qi' allows the invasion of exogenous pathogenic wind. Qi refers to the vital substances comprising the body and the physiological functions of viscera and bowels, channels and collaterals. 'Qi' maintains life activities and reflects the resistance of the body.

Acupuncture is part of TCM and dates back thousands of years. Acupuncture treatment is thought to regulate channels and collaterals, harmonize 'qi' and blood, strengthen the body's resistance to pathogenic factors, increase the excitability of the nerve, promote regeneration of the nerve fibers and formation of its collateral branches, enhance muscle contraction and blood circulation, and accelerate metabolism and recovery of body functions [11,12]. Warming acupuncture is a method of combining acupuncture with moxibustion [6], the effect is better than simple acupuncture, which has the function of warming the meridian and activating blood circulation. It is applicable to the syndrome of cold and dampness and stagnation of meridian and collaterals. Though a number of studies have indicated that the therapeutic effect of acupuncture on IFP is good in human [12], there is limited report on the treatment of idiopathic facial paralysis in dog [3]. This short communication describes the combination of acupuncture and moxibustion to treat IFP in a dog.

A seven-and-a-half-year-old female gold retriever dog, named DUDU, was referred to Luoyang Dog Doctor Pet Hospital. We accorded to the examination method reported by Jeong SM [3] to

diagnose the disease. The acute clinical signs showed that its right lip was weak, drooping, drooling, salivating, and retention of food in the mouth. The right upper eyelid was unable to close and the right ear had no skin sensation and was almost unable to move. The right eye had no the palpebral reflex, corneal ulceration, opacity, strabismus and nystagmus. Other aspects of right eye were normal such as the corneal and pupillary light reflexes, the visual following movements, obstacle testing, and visual placing response, the retraction of the eyeball etc. All functions of the left eye were normal. In addition to, its cranial nerve functions, postural reactions, segmental spinal reflexes and locomotion were normal. Examination of Biochemistry measurement, complete blood count, and electrolytes were also normal. No radiographic abnormality was observed in the skull. Synthesizing above examination result, idiopathic facial nerve paralysis were diagnosed.

The acupuncture and moxibustion was performed at the 5th day after the onset of these symptoms [6]. Firstly take a needle more than 1.5 inches in length, prick into the acupoint to get qi, retain the needle, then take a moxibustion stick about 2cm long, ignite its one end, move it around the needle handle, make the heat transmit into body through the needle. Local acupuncture points (ST4, ST5, ST7, GB3 and TH17) in the affected side were treated by needle warming through moxibustion (Figure 1). All points were retained needle for 30 minutes. The dog was treated 15 times of acupuncture and moxibustion in total, one day of rest per 3 days.

ST4 1 cm dorsocaudal to the angulioris, on the outer edge of musculus orbicularis; ST5 At the rostral border of masseter muscle between the upper and lower dentes molars; ST7 In the depression ventral to the zygomatic arch and rostral to the condyloid process of the mandible; GB3 In the depression caudal to the masseter muscle and dorsal to the zygomatic arch. The depression is more prominent when the mouth is open; TH17 In the depression caudal to the mandibular joint and ventral to the ear base.

In the early stages of treatment, the dog was very honest and did not dodge. After 4 times of acupuncture, it began to dodge, the

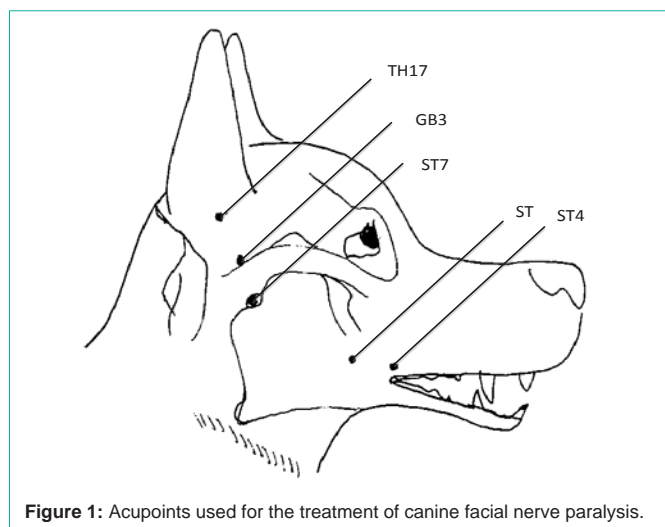


Figure 1: Acupoints used for the treatment of canine facial nerve paralysis.

drooping and drooling of the right lip were eliminated. Palpebral reflex, skin sensation and movement of the right ear were slightly improved after the 4th treatment. The face symmetry was regained at the 8th treatment. The symmetry of the ear and lip were completely recovered following the 12th treatment. After the last treatment, complete symmetry of the face was achieved. Ear movement and sensation was normal and the eyelids could be closed voluntarily.

The present study combined the acupuncture and moxibustion to cure IFP with fewer acupoints and shorter treating period in a dog. Only five local acupuncture points (ST4, ST5, ST7, GB3 and TE17) were used to achieve good curative effect in 20 days. In the previous reports, more acupoints were used in the IFP treatment; for example, eight acupoints (L120, ST2, ST7, SI18, TH17, GB3, GB34 and LI4) were used for four weeks in dog [3], twelve acupoints (ST4, SI18, ST2, ST3, ST6, ST7, L120, GV26, GB20, L14, ST36 and ST44) in horse [4]. The reason of fewer acupoints and shorter treating period might due to the addition of moxibustion on the basis of simple acupuncture in present study. Controlling inflammation and promoting the recovery of nerve function is the main purpose of treatment of idiopathic facial palsy. According to TCM, acupuncture can improve local blood circulation, the deficiency of qi and blood, the disharmony between

yin and yang, and the stagnancy of qi and blood. The moxibustion can stimulate the facial nerve's extra cranial distribution in a wide and sufficient quantity, further, relieve the spasm of smooth muscle, improve neurotropy, accelerate the circulation and supply of local blood, promote the metabolism of inflammatory facial nerve cells and surrounding tissues, absorb inflammatory substances, and restore the function of the facial nerve.

Though the therapeutic method of the combination of common acupuncture and moxibustion was proved is effective for the treatment of IFP in this dog, the comparative study on the high quality of acupuncture and moxibustion in dog is scarce and the related mechanism still needs to be further explored.

References

1. Adour KK. Current concepts in neurology: diagnosis and management of facial paralysis. *N Engl J Med*. 1982; 307: 348-351.
2. Braund KG, Lutgen PJ, Sorjonen DC, et al. Idiopathic facial paralysis in the dog. *Vet Rec*. 1979; 105: 297-299.
3. Jeong SM, Kim HY, Lee CH, et al. Use of acupuncture for the treatment of idiopathic facial nerve paralysis in a dog. *Vet Rec*. 2001; 148: 632-633.
4. Fleming P. Acupuncture for musculoskeletal and neurologic conditions in the horse. In *Veterinary Acupuncture: Ancient Art to Modern Medicine*. Ed A. M. Schoen. St Louis, Mosby. 1994: 511-512.
5. Kern TJ, Erb HN. Facial neuropathy in dogs and cats: 95 cases (1975-1985). *J Am Vet Med Assoc*. 1987; 191:1604-1609.
6. Roynard P, Frank L, Xie H, et al. Acupuncture for Small Animal Neurologic Disorders. *Vet Clin North Am Small Anim Pract*. 2018; 48: 201-219.
7. Earll JM, Kolb FO. Facial paralysis occurring with hypothyroidism. *Calif Med*. 1967; 106: 56-63.
8. Rendano V, De Lahunta A, King JM. Extra cranial neoplasia with facial nerve paralysis in two cats. *J Am Vet Med Assoc*. 1980; 16: 921-925.
9. Noya M, Pardo J. Diagnosis and treatment of facial palsy. *Neurologia*. 1997; 12: 23-30.
10. De Diego JI, Prim MP, Madero R, et al. Seasonal patterns of idiopathic facial paralysis: a 16-year study. *Otolaryngol Head Neck Surg*. 1999; 120: 269-271.
11. Ren XQ. A survey of acupuncture treatment for peripheral facial paralysis. *J Tradit Chin Med*. 1994; 14: 139-146.
12. He SH, Zhang HL, Liu R. Review on acupuncture treatment of peripheral facial paralysis during the past decade. *J Tradit Chin Med*. 1995; 15: 63-67.